



Techniques and Graft Materials used in Maxillary Sinus Lift Procedure for Dental Implant Placement – A Review

Suhas Manoharan¹, Revathi Duraisamy¹, Sindhuja Devi S², Santhosh Kumar M P^{*3}

¹Department of Prosthodontics, Saveetha Dental College and Hospital, Chennai- 600077, Tamil Nadu, India

²Department of Oral and Maxillofacial Surgery, Sree Mookambika Institute of Dental Sciences, kulasekharam-629161, Tamil Nadu, India

³Department of Oral and Maxillofacial Surgery, Saveetha Dental College and Hospital, Chennai-600077, Tamil Nadu, India

Article History:

Received on: 07.09.2019

Revised on: 15.12.2019

Accepted on: 22.12.2019

Keywords:

Sinus lift,
maxillary sinus,
pneumatization,
grafts

ABSTRACT

Maxillary sinus is one of the first Para-nasal sinuses that develop around the age of twenty (20) with the eruption of the maxillary third molars. It is pyramidal in shape. Pneumatization of the maxillary sinus occurs with time. Tooth loss may lead to loss of bone density, atrophy of bone and further pneumatization of the maxillary sinus leading to insufficient quality and quantity of bone for placing implants. Despite lots of literature and research being done, there is no clarity in obtaining consensus regarding the techniques and materials used in maxillary sinus lift procedures. This article reviews the various techniques and bone graft materials used in maxillary sinus lift procedures. The techniques include lateral window approach, hydraulic sinus lift technique, Piezoelectric Surgery technique, Transcrestal Approach, Osteotome Technique, and Balloon elevation technique. It can be concluded that the balloon antral elevation and Hydraulic Sinus Lift techniques are more efficient techniques for maxillary sinus lift procedures. These techniques are known to result in less perforations, less chair-side time, comparatively easier, and the need for elaborate instrumentation is minimized. It can also markedly increase the success rates of implants in contrast to the conventional techniques which pose greater risks to the patient, more soft tissue trauma, more chair-side time and can expose patients to infections.



*Corresponding Author

Name: Santhosh Kumar M P

Phone: +91-9994892022

Email: santhoshsurgeon@gmail.com

ISSN: 0975-7538

DOI: <https://doi.org/10.26452/ijrps.v11i2.2081>

Production and Hosted by

IJRPS | www.ijrps.com

© 2020 | All rights reserved.

INTRODUCTION

Maxillary sinus is the first paranasal sinuses to develop, which is pyramidal in shape and it completes developing around 20 years of age with the eruption of the maxillary third molars (Mcgowan *et al.*, 1993). Maxillary sinus has an average volume of 15cc and protrusion of the maxillary posterior root tips maybe seen in some cases which can lead to various complications during oral surgical and orthodontic procedures. Hence it is essential for clinicians to be aware of the apical position of the teeth in relation to the maxillary sinus (Wehrbein and Diedrich, 1992). The inner layer of the maxillary sinus is coated by pseudo stratified ciliated

epithelium known as Schneiderian membrane with a normal thickness of 0.8mm and is consistent with nasal epithelium through the ostium in medial meatus (Didilescu *et al.*, 2012). The superior wall is formed by the floor of the orbit, anteriorly by facial segment of maxillary bone, posterolateral wall is formed by zygomatic bone and greater wing of sphenoid bone and floor is established by the alveolar process and the palatal process of maxilla.

Pneumatisation is a physiologic process that occurs in all paranasal sinuses leading to increase in volume of the sinus. With age, pneumatisation of the maxillary sinus occurs. Following extraction of maxillary posterior teeth, marked reduction in bone density is seen followed by disuse atrophy of the bone accelerating the pneumatisation of the maxillary sinus (Wehrbein and Diedrich, 1992). Pre surgical analysis of the maxillary posterior region and position of the maxillary sinus is necessary to prevent oro-antral communication or damage to the maxillary sinus.

Accelerated by ridge resorption, bone loss and age, the sinus floor dips down in the maxillary posterior region and in certain cases perforation of the sinus floor by maxillary posterior root tips is also seen. Hence, for the placement of implants in such cases, sinus lift procedure is done. Maxillary sinus lift procedure is one the most frequently done pre-prosthetic procedures in dental practices around the world. Various articles have been published regarding the techniques and materials used in maxillary sinus lift procedure. In this article, the various techniques and graft materials available for sinus floor elevation are reviewed and summarized.

Techniques

Lateral window approach

In this technique a full mucoperiosteal flap is raised from the alveolar bone using vertical incisions. High speed surgical drills are used to create an access on the lateral sinus wall (Figure 1). Dissection of the Schneiderian membrane is done after access preparation using curettes and the surrounding bone is carefully lifted creating a space below the membrane in which bone grafts are placed. The flap should be made in such a way that proper blood supply is given from the base and the releasing incision should flare at the anterior or posterior edge. In such cases, where the sinus wall is close to the alveolar crestal bone or if it is thin, then a fully thick mucoperiosteal flap is recommended. In certain cases releasing incisions may have to be made at a distance from the window site. Single anterior incision may also provide sufficient access in some cases. Rotary or piezo-electric technique can be

used to provide adequate access into cortical bone and reveal the sinus membrane to create space for graft placement. For primary stabilization, implants can be placed with minimum bone height of about 4-5 mm and the raised flap is sutured to prevent exposure of the implants or grafts. This technique provides an average implant success rate of 91% (Waite, 1971; Andreasi *et al.*, 2013). Complications include excess bleeding, infection, swelling and discomfort.

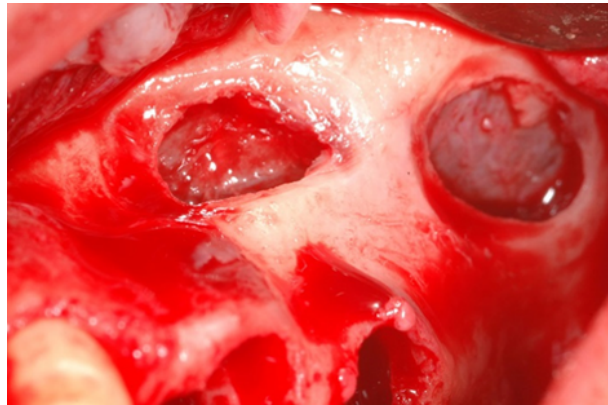


Figure 1: Lateral window approach

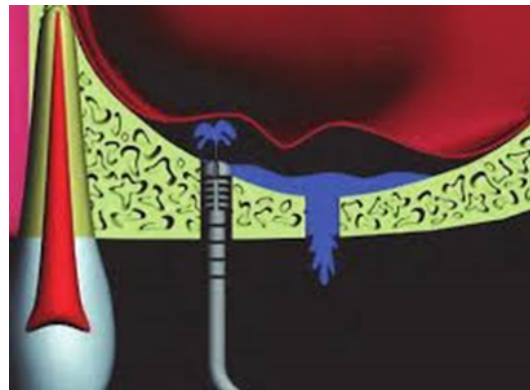


Figure 2: Hydraulic Sinus Lift Technique (HySiLift)

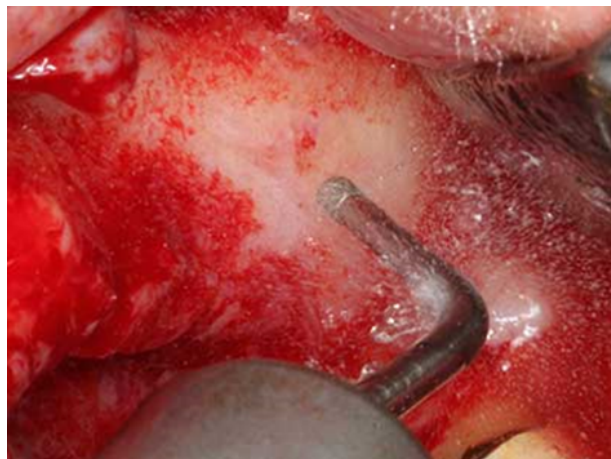


Figure 3: Piezoelectric Surgery (PS) technique

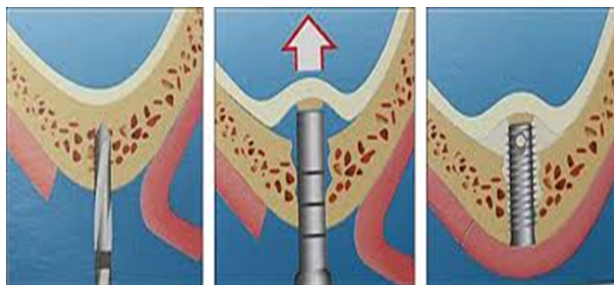


Figure 4: Transcrestal approach

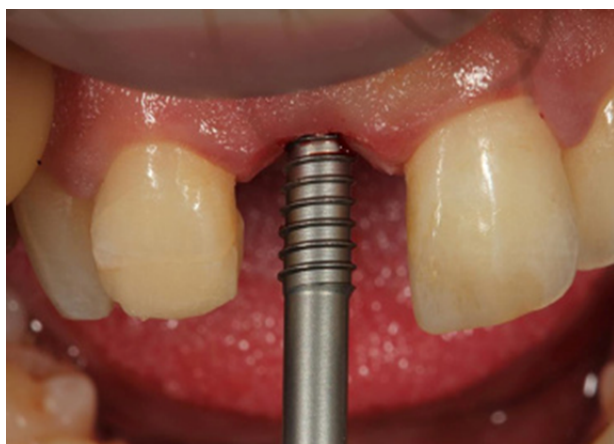

Figure 5: Threaded osteotome technique

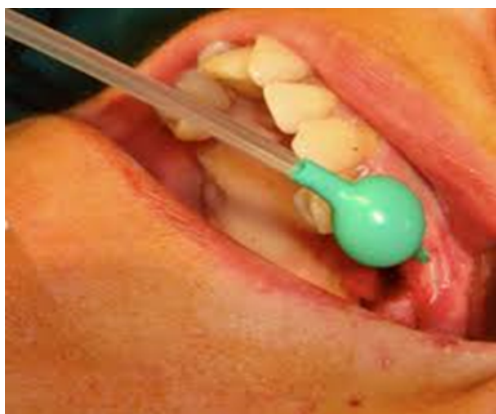

Figure 6: Balloon elevation technique

Hydraulic Sinus Lift Technique (HySiLift)

This technique involves injection of a liquid to detach the Schneiderian membrane followed by spontaneous aspiration thereby creating a sub Schneiderian space into which the graft is placed (Figure 2). Being a crestal approach, it is being widely used. The instruments used for this purpose consist of three components: a titanium syringe with a micrometric piston, a dispenser and measurements, and a needle in surgical steel. The single-use syringes are loaded with the required quantity of graft material (Busenlechner *et al.*, 2009; Carmagnola *et al.*, 2008). This technique allows the hydraulic detachment of the maxillary sinus

mucosa with subsequent filling of the sub Schneiderian space with the graft material and the failure rate of implants is 4% (Smeets *et al.*, 2008; Sohn *et al.*, 2008). This technique is quite advantageous as it is minimally invasive and provides superior results.

Piezoelectric Surgery (PS) technique

Piezoelectric bone surgery was developed by Tomaso Vercellotti to bypass difficulties in traditional surgery. The osteotomy instruments in this technique consists of an insert; three essential points to be considered during this procedure are precise, clean cutting, selective bone-cutting and relatively blood free surgical field (Vercellotti, 2004). Piezoelectric osteotomies (Figure 3) are done in a frequency range of 25- 30 kHz which provide an accurate cut in the bone without affecting the integrity of the surrounding soft tissues (González-García *et al.*, 2008). Frequencies above 50 kHz may result in soft tissue damage. This surgery is based on piezoelectric effect which postulates that certain ceramics and crystals deform when an electric current pass through them, and results in oscillations of ultrasonic frequency (Leclercq *et al.*, 2008). The vibrations obtained are amplified and transferred to a vibrating tip, which when applied with gentle pressure on bone tissue results in a cavitation phenomenon, an effect of mechanical cutting which occurs only in mineralised tissues (Crosetti *et al.*, 2009). The cavitation effect causes a hydro pneumatic pressure with saline irrigant, that helps to the lift the sinus membrane without trauma (Vercellotti, 2004). Success rate of 95% is seen in this technique. Perforations in the maxillary sinus membrane were observed in only 5% of patients (Misch, 1997).

Active tip of the piezosurgical device is small, thus increases the cutting efficiency and decreases the patient discomfort (Schlee *et al.*, 2006). Because, PS uses ultrasonic vibrations; it produces less vibration and noise than conventional surgery thereby minimizing patients stress and fear levels. There is also minimized risk of thermal necrosis. However other studies have shown risk of post-operative complications due to the presence of space left after the PS thereby, reducing the overall success rate (González-García *et al.*, 2008).

Transcrestal Approach (tSFE)

This technique is a surgical procedure used to increase the vertical height of the bone in the maxillary posterior region (Figure 4). Osteotomes are used in these procedures (González-García *et al.*, 2008; Leclercq *et al.*, 2008). Use of burs has also been advocated. In this technique, after the Schneiderian membrane is lifted, a graft material is condensed to maintain the position of the lifted mem-

brane. A modification of this technique was proposed by Fugazzotto which involves usage of specialized drills and osteotomes. All instruments used in this technique had stops, thus restricting the working action on the bone. The postoperative infection ranges up to 2.5% in this technique (Pjetursson *et al.*, 2008).

Osteotome Technique (OstSFE)

OstSFE technique uses an osteotome and mallet. Using the surgical mallet, the sinus floor is broken and bone graft is placed into the sinus. A pilot drill of 2-3 mm. short of the sinus floor is done to place the osteotome. Osteotomes are increased in width gradually to create adequate space for implants (Figure 5). According to a study (Berengo *et al.*, 2004), osteotomes can be used without bone grafts if the residual bone height is 5.4mm.

The usage of osteotomes can condense bone laterally and create a denser interface for implants (Nkenke *et al.*, 2002) and improve the quality of the initial bone-to-implant contact (Giro-lamo *et al.*, 2005). Possible complications such as perforation of sinus membrane are noticed in this technique. Also, benign positional paroxysmal vertigo (BPPV) may be caused due to the damage to the internal ear by the striking osteotome and mallet when the sinus floor is broken (Girolamo *et al.*, 2005; Rosen *et al.*, 1999). The OstSFE technique has low success rates when residual bone height is less than 4mm (Summers, 1994).

Balloon elevation technique

This technique is a modification of the bone-added osteotome sinus floor elevation (BAOSFE) method. Antral membrane elevation is done through the osteotomy site (3.5 mm) using a specially designed balloon (Figure 6). It consists of a stainless steel tube that connects the proximal end to an inflation syringe, and the distal end which has an embedded single use silicone balloon (Kfir *et al.*, 2006). The balloon is inflated with a diluted contrast fluid that lifts up the Schneiderian membrane, thereby creating sufficient height for implant placement (Kfir *et al.*, 2014; Mazor *et al.*, 2011). Under local anaesthesia, a punch is made, through which the epithelium is exposed. An ultrasonic piezoelectric drill is used to drill the alveolar crest and expose the sinus floor. Bone graft is then inserted; the membrane integrity was checked by the Valsalva manoeuvre. The balloon was inflated up to 2atm to augment the sinus. Once the desired elevation of 11mm is obtained the balloon is kept inflated in sinus for up to 5 mins to prevent any elastic forces of the sinus membrane. Subsequently the balloon is then deflated and removed.

Graft Materials

Autogenous bone

Autogenous bone was the first graft materials to be used widely as a sinus grafting material. Many studies involved harvesting grafts from the crest and stabilizing the grafts with implants. Most common sites for grafts include hip, knee and various intraoral sites. Harvesting of such grafts usually involves hospitalization thereby increasing the length and morbidity of the surgery. Studies have also reported resorption of grafts when using iliac bone. A Computed Tomography scan study showed that 5.47 cc of graft material would be required to graft a sinus for the placement of multiple 15 mm implants (Uchida *et al.*, 1998).

Demineralized freeze-dried bone (DFDBA)

It has also been widely utilized as a sinus graft material. While used successfully by some clinicians, the results published following the Academy of Osseo integration Sinus Consensus Conference showed both poor bone quality and a poor implant survival rate (85%). Moreover, this demineralized graft is susceptible to "slumping", or settling, with a concomitant loss of graft height. It has a volumetric resorption rate second only to that of autogenous bone (Jensen *et al.*, 1998).

Xenografts

Xenografts have been very well documented as a sinus grafting material. They have been used alone or as part of a composite graft combined with autogenous bone, venous blood or platelet-rich plasma. Efficacy of xenografts is due to a combination of factors such as osteo conductivity, slow resorbability, and the residual graft material which does not interfere with osteo integration. The most important factor that can be attributed to xenografts is their osteo conductivity; which may be defined as the direct apposition of vital bone on the xenograft surface.

CONCLUSIONS

It can be concluded that the balloon antral elevation technique and Hydraulic Sinus Lift technique are more efficient techniques for maxillary sinus lift procedures. These techniques are known to result in less perforations, less chair-side time, comparatively easier, and the need for elaborate instrumentation is minimized. It can also markedly increase the success rates of implants in contrast to the conventional techniques which pose greater risks to the patient, more soft tissue trauma, more chair-side time and can expose patients to infections. By using these recent advanced techniques, sinus lifting can be done with more confidence and higher rates of

success for implant placement with minimal patient discomfort. Further research with controlled clinical trials is necessary regarding the graft materials and techniques to ensure unparalleled efficiency in the field of implantology.

REFERENCES

- Andreasi, B., Lopez, M., Confalone, L., Fanali, S., Carinci, F. 2013. Hydraulic sinus lift technique: Description of a clinical case. *Annals of Oral and Maxillofacial Surgery*, 1(2):18–21.
- Berengo, M., Sivolella, S., Majzoub, Z., Cordioli, G. 2004. Endoscopic evaluation of the bone-added osteotome sinus floor elevation procedure. *International Journal of Oral and Maxillofacial Surgery*, 33(2):189–194.
- Busenlechner, D., Huber, C. D., Vasak, C., Dobsak, A., Gruber, R., Watzek, G. 2009. Sinus augmentation analysis revised: the gradient of graft consolidation. *Clinical Oral Implants Research*, 20(10):1078–1083.
- Carmagnola, D., Abati, S., Celestino, S., Chiapasco, M., Bosshardt, D., Lang, N. P. 2008. Oral implants placed in bone defects treated with Bio-Oss[®], Ostim[®]-Paste or PerioGlas: an experimental study in the rabbit tibiae. *Clinical Oral Implants Research*, 19(12):1246–1253.
- Crosetti, E., Battiston, B., Succo, G. 2009. Piezosurgery in head and neck oncological and reconstructive surgery: personal experience on 127 cases. *Acta Otorhinolaryngol Ital*, 29(1):1–9.
- Didilescu, A., Rusu, M., Săndulescu, M., Georgescu, C., Ciuluviică, R. 2012. Morphometric analysis of the relationships between the maxillary first molar and maxillary sinus floor. *Open Journal of Stomatology*, (04):352–357.
- Girolamo, M., Napolitano, B., Arullani, C. A., Bruno, E., Girolamo, S. 2005. Paroxysmal positional vertigo as a complication of osteotome sinus floor elevation. *European Archives of Oto-Rhino-Laryngology*, 262(8):631–633.
- González-García, A., Diniz-Freitas, M., Somoza-Martín, M., García-García, A. 2008. Piezoelectric and Conventional Osteotomy in Alveolar Distraction Osteogenesis in a Series of 17 Patients. *The International Journal of Oral & Maxillofacial Implants*, 23(5):891–896.
- Jensen, O. T., Shulman, L. B., Block, M. S., Iacono, V. J. 1998. Report of the Sinus Consensus Conference of 1996. *Int J Oral Maxillofac Implants*, 13:11–45.
- Kfir, E., Goldstein, M., Abramovitz, I., Kfir, V., Mazor, Z., Kaluski, E. 2014. The Effects of Sinus Membrane Pathology on Bone Augmentation and Procedural Outcome Using Minimal Invasive Antral Membrane Balloon Elevation. *Journal of Oral Implantology*, 40(3):285–293.
- Kfir, E., Kfir, V., Mijiritsky, E., Rafaeloff, R., Kaluski, E. 2006. Minimally Invasive Antral Membrane Balloon Elevation Followed by Maxillary Bone Augmentation and Implant Fixation. *Journal of Oral Implantology*, 32(1):26–33.
- Leclercq, P., Zenati, C., Amr, S., Dohan, D. M. 2008. Ultrasonic Bone Cut Part 1: State-of-the-Art Technologies and Common Applications. *Journal of Oral and Maxillofacial Surgery*, 66(1):177–182.
- Mazor, Z., Kfir, E., Lorean, A., Mijiritsky, E., Horowitz, R. A. 2011. Flapless Approach to Maxillary Sinus Augmentation Using Minimally Invasive Antral Membrane Balloon Elevation. *Implant Dentistry*, 20(6):434–438.
- Mcgowan, D. A., Baxter, P. W., James, J. 1993. The maxillary sinus and its dental implications. *John Wright*.
- Misch, C. M. 1997. Comparison of intraoral donor sites for onlay grafting prior to implant placement. *Int J Oral Maxillofac Implants*, 12(6):767–776.
- Nkenke, E., Radespiel-Troger, M., Wiltfang, J., Schultze-Mosgau, S., Winkler, G., Neukam, F. W. 2002. Morbidity of harvesting of retromolar bone grafts: a prospective study. *Clinical Oral Implants Research*, 13(5):514–521.
- Pjetursson, B. E., Tan, W. C., Zwahlen, M., Lang, N. P. 2008. A systematic review of the success of sinus floor elevation and survival of implants inserted in combination with sinus floor elevation. *Journal of Clinical Periodontology*, 35:216–240.
- Rosen, P., Summers, R., Mellado, J. R., Salkin, L. M., Shanaman, R. H., Marks, M. H., Fugazzotto, P. A. 1999. The bone-added osteotome sinus floor elevation technique: Multicenter retrospective report of consecutively treated patients. *The International Journal of Oral & Maxillofacial Implants*, 14:853–858.
- Schlee, M., Steigmann, M., Bratu, E., Garg, A. K. 2006. Piezosurgery: basics and possibilities. *Implant Dent*, 15(4):334–340.
- Smeets, R., Grosjean, M. B., Jelitte, G., Heiland, M., Kasaj, A., Riediger, D., Yildirim, M., Spiekermann, H., Maciejewski, O. 2008. Hydroxyapatite bone substitute (Ostim) in sinus floor elevation. Maxillary sinus floor augmentation: bone regeneration by means of a nanocrystalline in-phase hydroxyapatite (Ostim). *Schweiz Monatsschr Zahnmed*, 118(3):203–212.
- Sohn, D., Lee, J., Ahn, M., Shin, H. I. 2008. New Bone

- Formation in the Maxillary Sinus Without Bone Grafts. *Implant Dentistry*, 17(3):321-331.
- Summers, R. B. 1994. A new concept in maxillary implant surgery: the osteotome technique. *Compendium. 158 Passim; Quiz*, 162(2):154-156.
- Uchida, Y., Goto, M., Katsuki, T., Soejima, Y. 1998. Measurement of maxillary sinus volume using computerized tomographic images. *Int J Oral Maxillofac Implants*, 13(6):811-818.
- Vercellotti, T. 2004. Technological characteristics and clinical indications of piezoelectric bone surgery. *Minerva Stomatologica*, 53(5):207-214.
- Waite, D. 1971. Maxillary sinus. *Dental Clinics of North America*, 15(2):349-368.
- Wehrbein, H., Diedrich, P. 1992. The initial morphological state in the basally pneumatized maxillary sinus—a radiological-histological study in man. *Fortschr Kieferorthop*, 53(5):254-262.