



Evaluation of functional outcome of treatment for distal femur fractures

Vilas S. Mane*

Department of Orthopaedics, Krishna Institute of Medical Sciences, Karad, Maharashtra, India



Article History:

Received on: 19 Mar 2020
 Revised on: 14 Apr 2020
 Accepted on: 05 May 2020

Keywords:

Distal femur fractures,
 AO classification,
 metaphyseal junction,
 Locking compression
 plates

ABSTRACT

In the past few decades man has taken traveling to high speeds with flexed knee joint with much of impacts taken first by patella then femoral condyles and tibial condyles in different positions and proportions and with vast increment in technology, travel modalities and industrialization there have been advantages and disadvantages too like easier and faster traveling but road traffic accidents too. Such accidents and falls resulting in loss of lives and disabilities. In recent years with the advancement of technology and facilities, wide use and trend of open reduction & internal fixation has been apparent. This study evaluated the functional outcome of treatment for distal femur fractures. Patients were operated from 5 days to 35 days. Mean injury to surgery duration was 13.24 days patients were operated between 80 min to 160 min with mean time for operative procedure was 112.4 minutes, Open fractures were seen in 14(56%) closed fractures were seen in 11(44%). There were 14(56%) intra articular fractures and 11(44%) extra articular fractures. Comminution was present in 16(64%) fracture patterns in our study. All patients were operated with distal femur condylar locking compression plate. AO type C 3 fractures 7(28%) were most common type of fractures. Knee mobilization was started as early as within 2 weeks. Average time was 7.68 weeks. Functional outcome was analyzed according to the NEERS knee scoring system, 10(40%) observed excellent result, 5(20%) observed good results, 7(28%) observed fair result and 3(12%) observed poor results.

*Corresponding Author

Name: Vilas S. Mane

Phone:

Email: kimskarad66@gmail.com

ISSN: 0975-7538

DOI: <https://doi.org/10.26452/ijrps.v11i3.2597>

Production and Hosted by

IJRPS | www.ijrps.com

© 2020 | All rights reserved.

INTRODUCTION

The area between the condyles of femur and the metaphyseal – diaphyseal junction approximating 15 cms of the distal end of femur measuring from the surface of articulation is termed as the distal end of femur (Menon and Subramanian, 2014; Bezwada

et al., 2004). Fractures at lower end of femur are more often the complex fractures as they involve comminution and soft tissue injury. Distal femur region has wide medullary canal, thin cortices, compromised bone stalk, associated ligament injuries intraarticular involvement, and difficult in achieving anatomical alignment, fractures at lower end of femur are difficult to treat (Zlowodzki *et al.*, 1989).

Better implants have provided the results which are satisfactorily obtained with the use of intramedullary supracondylar nail, locking dynamic compression plates, buttress plate, cannulated cancellous screws & Herbert screws (Markmiller *et al.*, 2004). Patients of elderly age presenting with the common complaints of osteoporosis with fractures around knee are difficult to manage as it requires restoration of geometrical relationship of articular surfaces and its rotational axis, for free movement in joint without persistent pain. Locking

Compression Plates in such cases are of great use. Locking compression plates are of much advantage as they combine both locked plating techniques & conformist compression plating enhancing the plate osteo-synthesis. Such a built results in marked reduction in soft tissue issues (Zlowodzki *et al.*, 1989; Markmiller *et al.*, 2004; Higgins *et al.*, 2007).

Mechanism of Injury

Main mechanism being axial injury in cases of distal end of femur with rotational forces as varus or valgus.

Fracture Lower End of Femur

Figure 1 Comminution, open wound & displaced fractures are mostly common in high velocity trauma. In elderly patients with osteoporosis, this type of fracture can be caused due to flexed knee or trauma. Deformity is caused due to either

1. Muscle force and imbalance
2. Trauma caused initially.

Till the consolidation of fracture, muscle forces continue to act during the primary impact during initial trauma.

Research Objectives

Purpose of this study is evaluation and determination of results of distal end femur fracture treated by distal femur locking compression plate in AO type A and AO type C fractures. Other objectives include

Evaluation of time required for union of fracture clinically and radiologically. Evaluation with respect to joint movement, work capacity and walking. Study of associated complications like infection, knee stiffness, post traumatic arthritis, delayed union, malunion, deformity, implant failure, limb shortening.

Types of Injuries

Most common injuries being compression or nerve damage due to the sharp fragment margins of the distal end. Rare incidences of neurological involvement and common peroneal nerve involvement. Further complicated mechanism of quadriceps and concomitant ligament injuries of knee resulting in instability of knee joint, stiffness of knee and adhesions at extra articular regions (Vishwanath *et al.*, 2016).

- Femoral shortening,
- Distal fragment angulation posteriorly,
- Displacement of fragment.

Classification: AO Type 33

(Distal Femur-Figure 2)

TYPE-33 A: Fractures are extra-articular

- A1: Simple fractures
- A2: Metaphyseal wedge fracture
- A3: Complex metaphyseal fracture

TYPE-33 B: Fractures are partially articular

- B1: Lateral condylar fractures in the sagittal plane
- B2: Medial condylar fracture in sagittal plane
- B3: Coronal/frontal fracture of femoral condyles

TYPE-33 C: Fractures which are intra-articular

- C1: Simple fractures of both articular surface and metaphysis
- C2: Simple fractures of articular surface and comminution of metaphysis.
- C3: Comminuted fracture of articular surface.

In this study distal femur condylar locking compression plate is used in all cases.

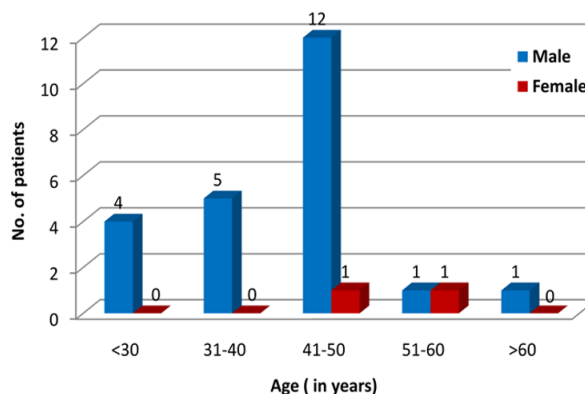


Figure 5: Age and Gender wise distribution of patients

Gender wise distribution of patients

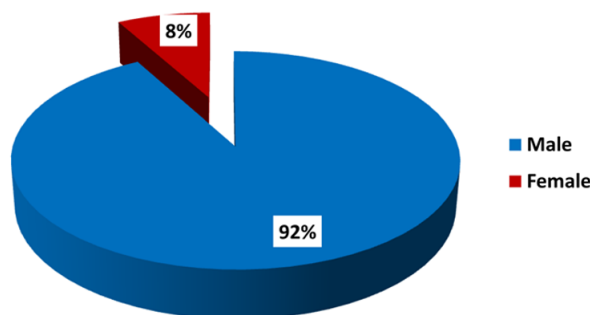


Figure 6: Gender wise distribution of patients

LITERATURE REVIEW

Different types of treatments modalities have been tried for the distal femur fractures including manipulation, casts, slabs, cast bracings & skeletal traction

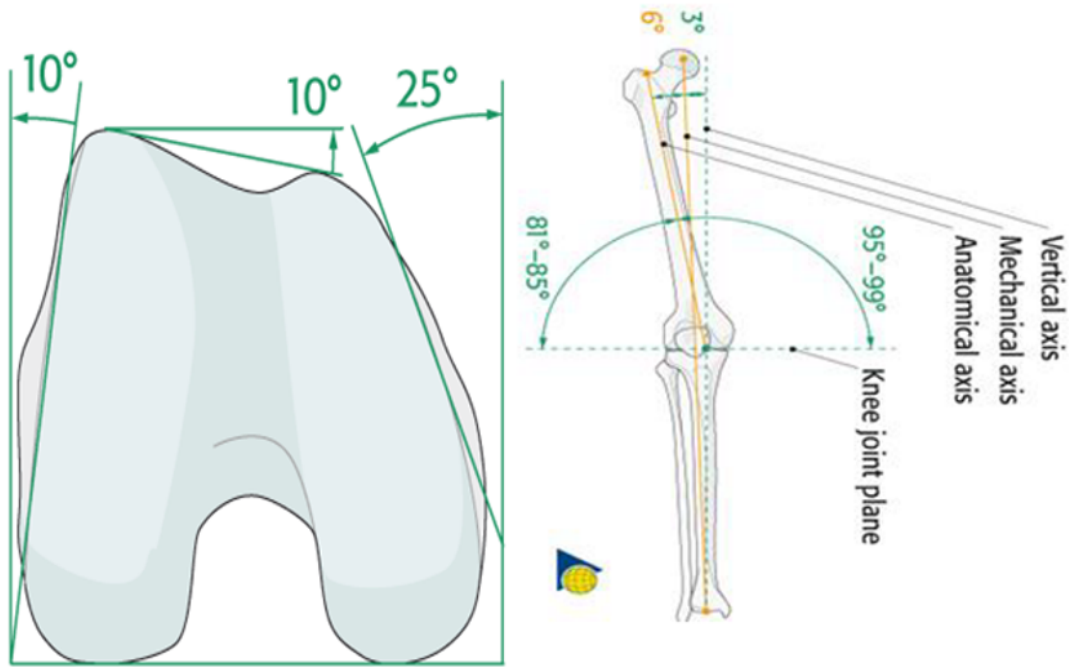


Figure 1: Femoral Condyles and various axis of femur

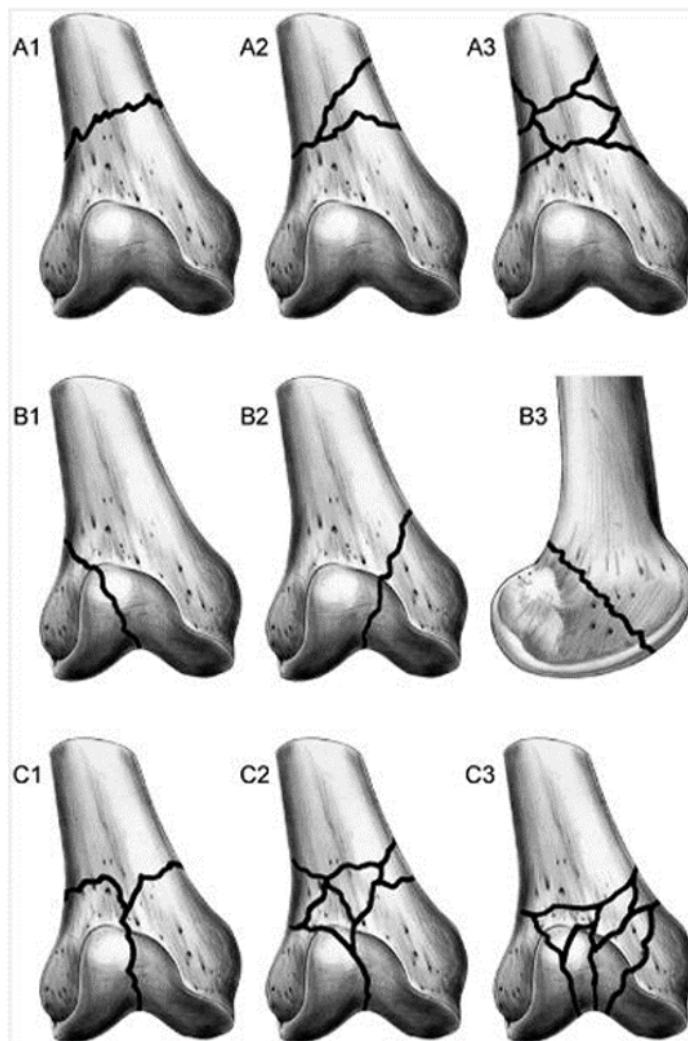


Figure 2: AO Classification

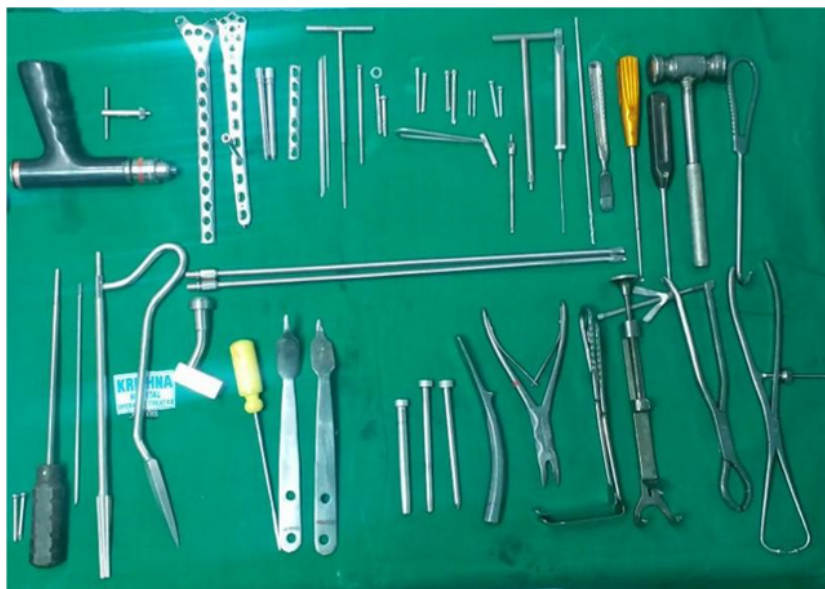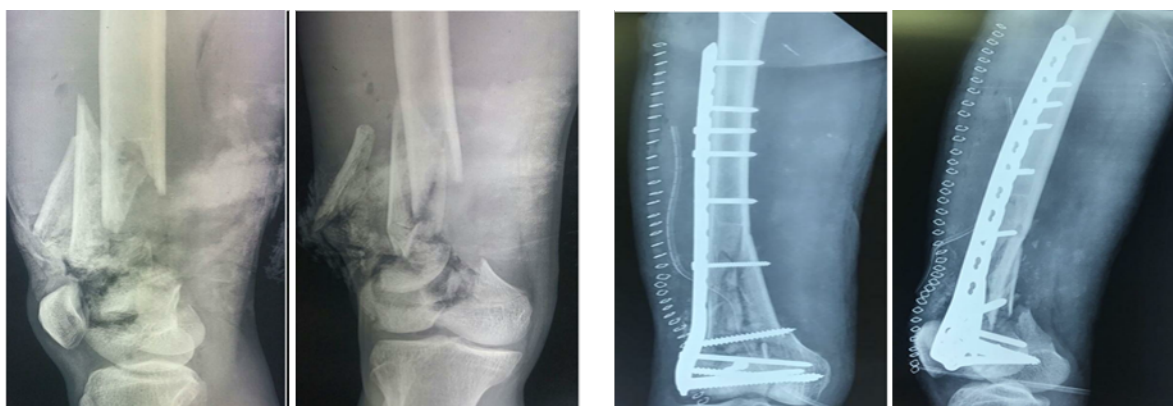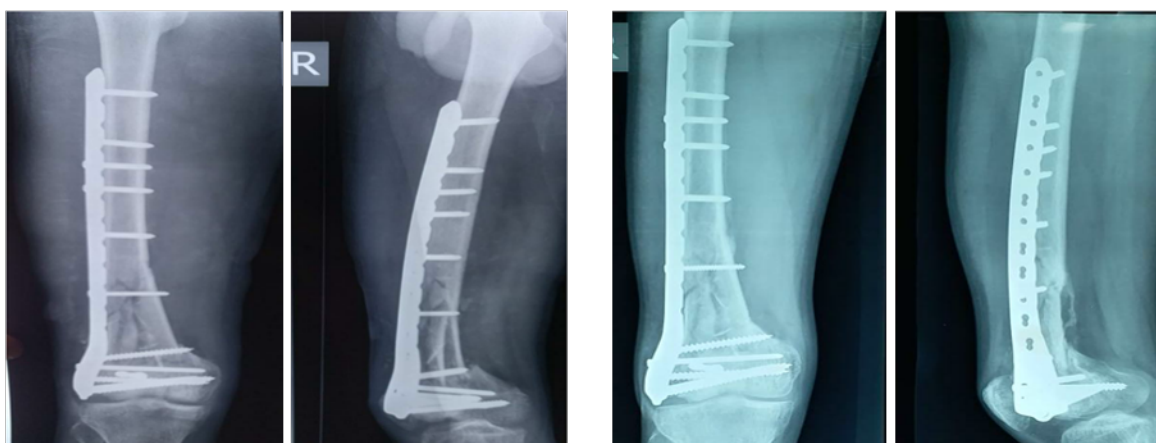


Figure 3: Instruments and Implants used



(a) Pre-operative X-ray

(b) Post-operative X-ray



(a) Post-Operative 6 Weeks

(b) Post-Operative 24 Weeks

Figure 4: Pre and Post-operative X-rays of fracture treatments

Table 1: AO Classification for distalfemur fractures

AO Fracture	Type	No. of Patients
Type A	33 A1	2
	33 A2	5
	33 A3	4
Type C	33 C1	2
	33 C2	5
	33 C3	7
	Total	25

Table 2: Age and Gender wise distribution of patients

Age in years	Male	Female	Total	Chi-Square Statistic
<30	4	0	4	0.0002
31-40	5	0	5	
41-50	12	1	13	
51-60	1	1	2	
>60	1	0	1	
Total	23	2	25	
Mean \pm SD	40.65 \pm 11.29	49.00 \pm 5.65	41.32 \pm 11.12	

Table 3: Gender wise distribution of patients

Gender	No of patients	Percentage
Male	23	92
Female	2	8
Total	25	100

Table 4: Mechanism of Injury

Mechanism of Injury	No. of Patients	Percentage
Road Traffic Accident	24	96
Domestic-Fall from Height	1	4
Total	25	100

Table 5: Nature of Injury-Closed/Open

Nature of Injury	No. of Patients	Percentage
Closed	11	44
Open Gustilo and Anderson Type 1	1	4
Open Gustilo and Anderson Type 2	7	28
Open Gustilo and Anderson Type 3A	5	20
Open Gustilo and Anderson Type 3B	1	4
Total	25	100

Table 6: Injury - Surgery Interval

Surgery-Injury Interval (In Days)	No. of patients	Percentage
<10	9	36
10-20	12	48
20-30	3	12
>30	1	4
Total	25	100

Table 7: AO Classification

AO Fracture Type		No. of Patients	Percentage
Type A	33A1	2	8
	33A2	5	20
	33A3	4	16
Type C	33 C1	2	8
	33C2	5	20
	33C3	7	28
Total		25	100

Table 8: Knee Mobilization Starting Period

Knee Mobilization Starting Period (In Weeks)	No. of Patients	Percentage
0-4	10	40
5-8	3	12
9-12	9	36
13-16	3	12
TOTAL	25	100

Table 9: Malalignment

Malalignment	No of Patients	Percentage
Nil	18	72
Varus	5	20
Valgus	2	8
Total	25	100

Table 10: AO classification and functional outcome

AO type	Excellent and good result	Fair and poor result	Chi square
A	9	2	0.0483
C	6	8	

for external immobilization of fractures. Another modality was invented in 1870 by Hugh Owen Thomas ([Markmiller et al., 2004](#)) named as Thomas splint which helped in the immobilization and manipulation of fracture.

First internal fixation technique was derived and done in 1894 by Sir Arbuthnot Lane using screw and plate. Skeletal traction was another important method replacing the skin traction. Skeletal trac-

tion used 'Steinman Pin' introduced by Fritz Steinman ([Vishwanath et al., 2016](#)) in 1909. Next in 1930's inert alloys like molybdenum chromium and nickel vitellium were described.

([R.V. and M, 2015](#)) guided the treatment of fractures around knee by describing the anatomy of lower end of femur. It's very important to understand the biomechanics of fracture to even assign treatment modality which is why anatomy of the fracture site

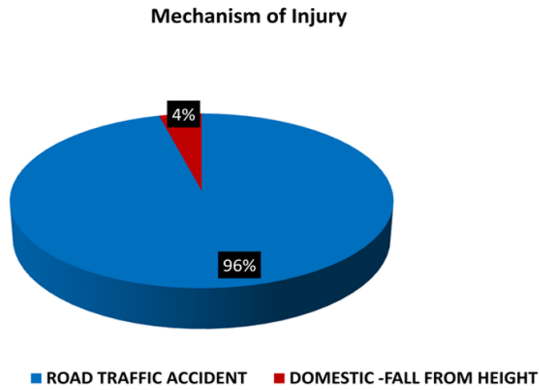


Figure 7: Mechanism of Injury

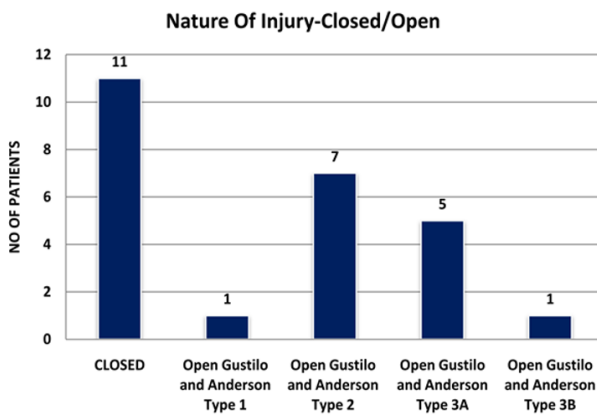


Figure 8: Nature of Injury-Closed/Open

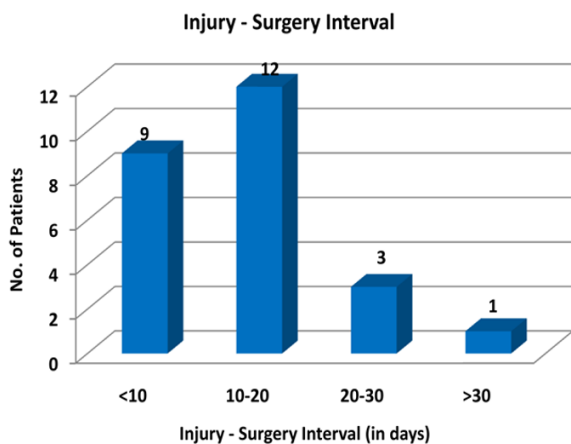


Figure 9: Injury - Surgery Interval

and fracture classification as classified by Muller is important.

(Kumar *et al.*, 2017) also reported using suspended traction system mode of Thomas splint with Pearson attachment permits good results. He focused on the importance of proper care in recumbent period consisting of high protein diet, early active exercises and timely Roentgenographic examination.

(Saini *et al.*, 2018) shows in osteoporotic bone the LISS fixator provides better fixation as compared

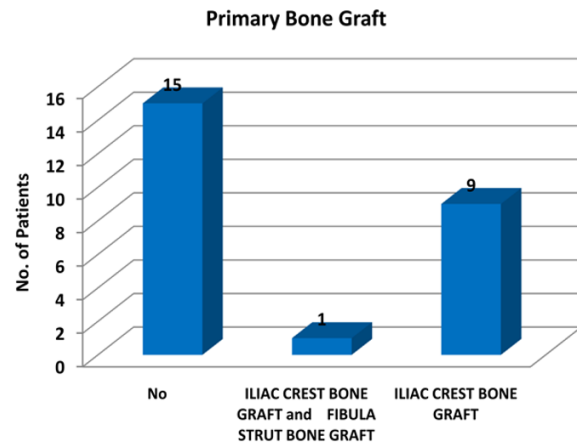


Figure 10: Primary Bone Graft

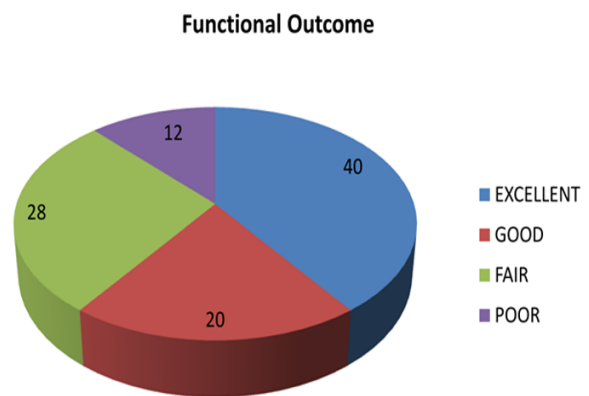


Figure 11: Functional Outcomes

to the intramedullary nail and angled blade plate, hence used for distal femur fracture management. The LISS fixator uses same material and is designed with characteristics like the tibial LISS fixator. Using LISS fixator nullifies the occurrence of varus collapse in fractures like bicondylar tibial plateau fracture as demonstrated by the series of study.

According to (Vallier *et al.*, 2006), implementing the technique of biological fixation with minimal invasion to soft tissues helps in bringing down the complication rates. The retrograde nailing is a similar method of biological fixation. Locking plate has also gained popularity in present times due to its success rate in injuries with minimal invasion of soft tissues. Infact locking plate constructs are stiffer than others and may reduce the amount of callous produced and thereby affect the fracture union. There have been some reports which state that the intramedullary nails are less stiff than the locking plates (Krishna and Shankar, 2016).

MATERIALS AND METHODS

This is a study conducted in Department of Orthopedics at Krishna Institute of Medical Sciences Deemed to be University, Karad. This study is about the Evaluation of Functional Outcome of treatment for distal femur fractures. In this study 25 patients with distal femur were included who presented to KIMS casualty who fulfilled the criteria. The patients were classified according to AO Classification for distal femur fractures. All the 25 patients were classified according to AO classification in Table 1. Of these 11 were Type 33A and 14 were Type 33C.

The method used for fracture fixation was open reduction and internal fixation with distal femur condylar locking compression plate.

Implant Used

Distal femur Condylar locking compression plate with locking cancellous and cortical screw.

Procedure

Preparation- The supine position with the knee flexed 30° provides good support for the knee and relaxes the tendency of the gastrocnemius muscle to pull the condyles into hyperextension.

Correction of Hyperextension

Correction of Hyperextension deformity must be corrected before fracture fixation. Aids to correct this hyperextension deformity include,

Muscle relaxation of the patient A bolster in the supracondylar region

Intra operative radiological assessment was done in terms of length and rotation (position of lesser trochanter of contralateral side).

Wound closure

Close any joint capsule arthrotomy with absorbable sutures. Proximally, close the fascia of the vastus lateralis with a running absorbable suture or interrupted sutures. Close the iliotibial band with absorbable sutures. Close the skin and subcutaneous tissues in a routine manner. The use of suction drains was considered in some cases.

Postoperative evaluation

Patients were immobilized according to fracture fixation stability and comminution. Drain was removed within 48 hours post operatively. Physiotherapy was started from postoperative day 1 as quadriceps and hamstring strengthening exercises. Knee mobilization was started depending upon the fracture pattern and modality of fixation. Non weight bearing was started and gradually increasing to partial and full weight bearing depending upon

the modality of fixation (Choudhary *et al.*, 2019; Ramu *et al.*, 2018).

All patients were evaluated postoperatively at regular follow up of 6 weeks, 3 months, 4.5 months, 6 months. Serial x-rays and functional assessment were carried out at each visit in outpatient clinic itself using the Neer's Knee Score. All the patients were assessed using a standard Proforma in Figures 3 and 4.

OBSERVATION AND RESULTS

A prospective study was conducted with 25 patients to compare and evaluate the functional outcomes of distal femur fractures. Patients were classified according to AO classification. We compared the distribution of patients in different variables like age group, sex, etc. and their association using Chi-square test or Fisher exact test. The scores within single group at different time interval was compared using Paired t- test, and comparison of scores between two groups was done using unpaired t- test.

Age and Gender Distribution

Age group ranged from 20 years to 70 years. Majority of the patients were from the age group 41-50 years 12(48%) patients, followed by less than 31-40 5(20%) patients, less than 30 years 4(16%) patients, 51-60 years 1(4 %) and more than 60years (4 %). Average age of patients was 41.32 years with a standard deviation of 11.12 years in Table 2 and Figure 5.

By comparing CHI square statistics of age and gender male dominance was seen in a particular age group.

Out of total patients' majority of the patients were male 23 (92 %), and 2 female (8%) in Table 3 and Figure 6.

Mechanism of Injury

Out of 25 patients in our study, 24 patients (96%) had road traffic accident, while 1 patient (4 %) had fall from height in Table 4 and Figure 7.

Nature of Injury- Closed/Open

Out of 25 patients, majority femur fracture were closed- 11 cases (44 %) followed by open type 2 in 7 cases (28 %), open type3A in 5cases (20 %), open type1 in 1 case (4 %) and open grade 3B in 1 patient (4 %) in Table 5 and Figure 8.

Injury-Surgery Interval

In our study of 25 cases, 9(36%) cases were operated within less than 10 days, 12(48%) cases operated between 10-20 days, 3(12%) cases were operated between 20-30 days and 1(4%) patient was

operated after 30 days. mean injury surgery interval 13.24 days in Table 6 and Figure 9.

Injury-surgery interval and duration of surgery

In our study of 25 patients, majority of patients were operated between 10-20 days of injury and most of patients require more than or equal to 100 minutes. we compared surgery injury interval and duration of surgery in all patients.

By applying Chi-square test(0.64) ,P value(0.14) there is a no any significant association observed between Injury-surgery interval and duration of surgery.

AO Classification

Distal femur fractures were classified according to AO classification. Out of total 25 patients, 11 cases (44%) are classified into Type A fracture, and majority were 14 cases (56 %) under Type C (see Table 7).

Primary Bone Graft

In our study of 25 patients, no bone graft required in 15(60%) patients, iliac crest bone graft required in 9(36%) patients and combined iliac crest and fibula strut graft in 1(4%) patient in Figure 10.

Knee Mobilization Starting Period

In our study of 25 patients, majority patients were started with knee mobilization within 4 weeks 10(40%) patients, 9 (36%) patients in 9-12 weeks, 3 (12%) patients in 5-8 weeks, 3 (12%) patients in 13-16 weeks in Table 8.

Malalignment

In our study, out of 25 patients 6(24%) patients had varus malalignment and 3 (12%) patients had valgus malalignment 16(64%) patients had no malalignment in Table 9.

Functional Outcomes

In our study of 25 patients, 10(40%) observed excellent result, 5(20%) observed good result, 7(28%) observed fair result and 3(12%) observed poor result in Figure 10.

AO classification and functional outcome

In our study we compared AO type classification and functional outcome in Table 10.

AO fracture type and functional outcome are compared and are statically significant p-0.0483.

CONCLUSIONS

Distal femoral fractures are common in young males in the age group of 30 – 50 years with high velocity high impact injuries. Closed type fracture and Extra articular fractures AO Type A fractures had

better functional outcomes. Bone grafting is necessary in case of comminution. Distal femur locking compression plate is an optimal tool for supracondylar fractures of femur especially AO Type A fractures and AO type C where we found higher Neer's scores. Accurate positioning and fixation are required to produce satisfactory results. It provides rigid fixation in the region of femur, where a widening canal, thin cortices and frequently poor bone stock with severe comminution make fixation difficult. But careful selection of patients and strict adherence to the basic principles of fracture fixation will help in reducing the complications of fracture fixation using locking compression plates. Regular Follow up and physiotherapy have great role. Rate of knee stiffness in our study was slightly higher as compared to standards, because of late knee mobilization starting period.

ACKNOWLEDGEMENT

Authors would like to thank Department of Orthopaedics, Krishna Institute of Medical Sciences, Karad, Maharashtra, India.

Funding Support

Nil

Conflict of Interest

I hereby declare that there is no conflict of interest related to this manuscript.

REFERENCES

- Bezwada, H. P., Neubauer, P., Baker, J., Israelite, C. L., Johanson, N. A. 2004. Periprosthetic supracondylar femur fractures following total knee arthroplasty. *The Journal of Arthroplasty*, 19(4):453-458.
- Choudhary, D. S., Gaonkar, D. N. K., Garud, D. A. B., Sahu, D. G. 2019. A study of the functional outcome of different operative modalities of treatment for distal femur fractures. *International Journal of Orthopaedics Sciences*, 5(2):911-922.
- Higgins, T. F., Pittman, G., Hines, J., Bachus, K. N. 2007. Biomechanical Analysis of Distal Femur Fracture Fixation: Fixed-Angle Screw-Plate Construct Versus Condylar Blade Plate. *Journal of Orthopaedic Trauma*, 21(1):43-46.
- Krishna, C., Shankar, R. 2016. Current concept of management of supracondylar femur fracture: retrograde femoral nail or distal femoral locking plate. *International Surgery Journal*, 3(3):1356-1359.
- Kumar, S. K., Ghosh, A., Dasgupta, S., Naiya, S., Chatterjee, D., Sarkar, A. 2017. Short Term Evalua-

- tion of Distal Femoral Fracture Fixation by Locking Plate. *Annals of International medical and Dental Research*, 3(4).
- Markmiller, M., Konrad, G., S??dkamp, N. 2004. Femur??LISS and Distal Femoral Nail for Fixation of Distal Femoral Fractures. *Clinical Orthopaedics and Related Research*, 426:252-257.
- Menon, R. R., Subramanian, V. 2014. Functional outcome of distal femoral fractures treated by minimally invasive surgery using locking condylar plate. *Kerala Journal of Orthopaedics*, (1):27-27.
- Ramu, A. C., Roshan, S. D., Anoophegde, Naveen, A. 2018. Functional outcome of management of fracture of distal femur. *A National Journal of Clinical Orthopaedics*, 2(1):32-36.
- R.V., S., M, S. 2015. Utility and outcomes of locking compression plates in distal femoral fractures. *International Journal of Research in Orthopaedics*, 1(1):15-15.
- Saini, D. R. A., Shah, D. N., Sharma, D. D. 2018. Functional outcome of distal femoral fractures treated with DF-LCP [Distal femur locking compression plate]. *International Journal of Orthopaedics Sciences*, 4(1g):439-444.
- Vallier, H. A., Hennessey, T. A., Sontich, J. K., Patterson, B. M. 2006. Failure of LCP condylar plate fixation in the distal part of the femur: A report of six cases. *JBJS*, 88(4):846-853.
- Vishwanath, C., Harish, K., Gunnaiah, K. G. 2016. Surgical outcome of distal femur fracture by locking compression plate. *International Journal of Orthopaedics*, 2(4):233-239.
- Zlowodzki, M., Bhandari, M., Marek, D. J., Cole, P. A., Kregor, P. J. 1989. Operative treatment of acute distal femur fractures: systematic review of 2 comparative studies and 45 case series. *Journal of orthopaedic trauma*, 20(5):366-371.