



## Development of biodegradable silkworm cocoon derived silk membrane for GTR in the treatment of grade II furcation

Archana R Sankar<sup>1</sup>, Sheela Kumar Gujjari<sup>\*1</sup>, Kulkarni PK<sup>2</sup>, Akhila AR<sup>2</sup>

<sup>1</sup>Department of Periodontology, JSS Dental College and Hospital, JSS Academy of Higher Education and Research, Mysuru-570015, Karnataka, India

<sup>2</sup>Department of Pharmaceutics, JSS College of Pharmacy, Mysuru-570015, Karnataka, India

### Article History:

Received on: 07.09.2019

Revised on: 14.12.2019

Accepted on: 28.12.2019

### Keywords:

Bone Fill,  
Collagen Membrane,  
Grade II furcation,  
Silk Fibroin Membrane,  
Xenograft

### ABSTRACT

This was a preliminary study to develop a biodegradable membrane from silkworm *Bombyx.mori*. The silk fibroin membrane prepared was analyzed for tensile strength and used in patients with grade II furcation defects, which was compared with collagen membrane. Though collagen is the gold standard, it has disadvantages, one of them being slow biodegradability. Hence this research was carried out to see if silk fibroin was good as a regenerative material in providing bone fill in the furcal area. As it is commonly accepted that treatment in the furcal area is better with bone graft and GTR membrane compared with just bone graft and flap surgery, this clinical trial with a common bone graft was carried out in addition to barrier membrane, which were of different sources. The patients fulfilling the inclusion criteria were randomized into test and control sites. The test sites received bone graft (colocast) and silk fibroin membrane while the control site received bone graft (colocast) and collagen membrane (cologide). The bone fill was analyzed radiographically using AUTOCAD software 2017. The results of the study showed that both the sites did not show any adverse effects, but improvement were noted clinically and radiographically. Radiographically significant improvement was seen in silk fibroin sites indicating that silk fibroin with bone graft would be better as a regenerative material.



### \*Corresponding Author

Name: Sheela Kumar Gujjari

Phone: 9448836777

Email: [sheelagujjari@gmail.com](mailto:sheelagujjari@gmail.com)

ISSN: 0975-7538

DOI: <https://doi.org/10.26452/ijrps.v11i2.2033>

Production and Hosted by

IJRPS | [www.ijrps.com](http://www.ijrps.com)

© 2020 | All rights reserved.

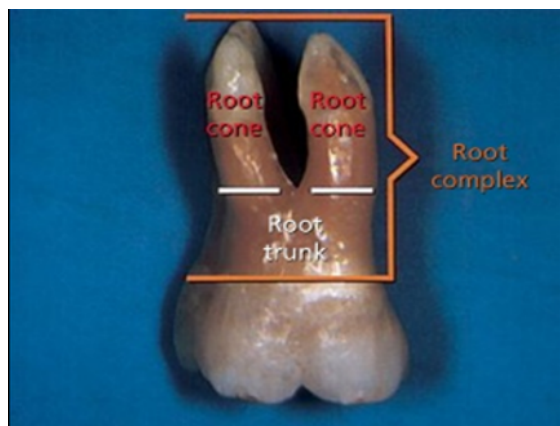
### INTRODUCTION

A challenge faced in the management of the periodontal disease is furcation involvement, which mainly affects the bifurcation and trifurcation of

multirooted teeth. It is indeed a challenge to the clinician as furcally involved teeth are difficult to treat as it is inaccessible for instrumentation as well as personal home care (Figure 1).

Various treatment approaches have been advocated for the treatment of furcation, which includes conservative, resective and regenerative techniques (Sanz *et al.*, 2015). Of the regenerative materials, bone grafts have been used as a gold standard of which xenograft has been quite popular. It has structural components similar to human bone, thereby improving the osteoconductive capability when compared to that of synthetically derived materials.

There is enough evidence which has proved that the combination of bone graft and barrier membrane helps in better regeneration of bone when com-



**Figure 1: Furcation**



**Figure 2: Cocoons in 2grams of sodium bicarbonate**



**Figure 3: Dialysis bag (cellulose membrane)**

pared to flap surgery alone or flap surgery plus bone graft (Mcclain and Schallhorn, 1993a; Lekovic *et al.*, 1990; Wallace *et al.*, 1994). Though collagen is the standard biodegradable membrane which has been most studied and versatile material in dentistry, it has disadvantages. This had led to researchers seeking a material which would be more biocompatible, cost-effective with better mechanical properties and has slow degradability since collagen degrades

within 3-4months. For ideal regeneration to take place, the barrier material should stay for a minimum of 4 weeks to 6 months.

With the advent of various technologies and with the emergence of tissue engineering, the barrier membranes have undergone various modifications according to the recent trend. The requisites of an ideal barrier membrane include biocompatibility, better handling properties, ability to adhere to root surface, promote tissue coverage with reduced barrier exposure rates, resist bacterial contamination, promote selective cell proliferation within the defect and should be absorbed at a rate that parallels regenerative tissue formation within 4 weeks to 6 months. There are very few membranes which fulfill these requirements. Hence the search is on for an innovative material from a natural source and with minimal side effects.

New insights have shown that silk could be the futuristic regenerative material due to its remarkable mechanical properties, biocompatibility and biodegradability as it degrades after a period of 12 months (Melke *et al.*, 2016). It is a novel biomaterial which has evolved from insects such as silkworm, mites, spiders and beetles and has proved to be a promising material as a scaffold which could help in tissue engineering as it has been used as a scaffold for periodontal ligament cells (Yang *et al.*, 2013).

Silk can be processed into different forms such as hydrogels, films, nanofibers and nanoparticles. The degradation rate can also be adjusted by controlling the (beta-sheet content) during processing (Nagal and Singla, 2013). Though silk fibroin has been studied as a scaffold for periodontal regeneration, these studies have been done only in vitro. There are no studies done in humans though this material has been extensively studied in regenerative medicine using animals. Thus this has kindled an interest in seeing it as a possible periodontal regenerative material. Though various technologies have been used to treat furcations, it is still an enigma for the clinician. So a comparative evaluation of silk fibroin over the collagen membrane with xenograft in the treatment of grade II furcation defects was carried out.

## MATERIALS AND METHODS

### Fabrication of silk fibroin membrane

Species of Bombyx.mori cocoons were obtained from (Satellite Silkworm Breeding Station, Coonoor (Nilgiris), Tamil Nadu, India) Sodium bicarbonate, Calcium chloride, Ethanol and Hydroxyl Propyl Methyl Cellulose from (Padmashree chemicals,

Mysuru, Karnataka, India) Cellulose membrane was obtained from Sigma Aldrich, Bengaluru, Karnataka, India. All the materials used for the study were of pharma grade and were generally regarded as safe (GRAS).

#### **Extraction of Silk fibroin from Bombyx mori**

5 grams of Bombyx mori silkworm cocoons were cut into small pieces with titanium scissors.

Pieces of cut cocoons were placed in a beaker of 1-liter capacity containing ultrapure water and boiled for half an hour. To the heated silk fibers, 2 grams of sodium bicarbonate was added to the beaker and occasionally stirring with a glass rod was done to obtain a dispersed phase of fibers. This process is called degumming. After cooling, the silk fibers were washed with water to remove an excess of sodium bicarbonate followed by squeezing of silk fibers to remove water. The degummed silk fiber was stored at room temperature (can be stored for a long term period) and wrapped in aluminium foil (Figure 2).

#### **Dialysis of degummed silk fiber**

A dialysis bag (cellulose membrane) was presoaked for 24 hours. The silk fibers were soaked in a medium consisting of 1:2:8 ratio of Calcium Chloride-Ethanol-Water, which was used as a pre-dissolving solvent mixture for the silk fibers. The soaked silk fibers were then placed in the cellulose membrane (dialysis cassette was replaced) and dialysed against ultrapure water for 4 days (Figure 3).

#### **Centrifugation**

Silk fibers and the supernatant was removed from the dialysis bag and centrifuged in an ultra-low centrifuge at 4000 rpm at 4°C for 40 minutes. The resultant viscous solution was then stored in a screw-capped tube and placed in a vacuum driver (Figure 4).

#### **Preparation of the membrane**

The extracted viscous solution was mixed with 0.2% hydroxyl propyl methylcellulose (HPMC), a copolymer to get a membrane. The solution was poured into Petri dishes and gently tapped for even dispersion of contents. The Petri dishes were placed in a vacuum driver (Mettler company) for one day at 39°C (Figure 5). The film/membrane, thus formed was stored in a sterile container and evaluated for tensile strength.

#### **Characterization**

Tensile strength of the membrane was determined using a universal testing machine at a speed of 1 mm/minute. A rectangular-shaped silk fibroin membrane with a thickness of 1.1 mm (10 cm in

length) was taken and fixed to Universal Testing Machine (UTM). This machine determined the tensile strength at peak load and break load with % elongation and yield strength.

#### **Sterilization**

The membrane was sterilized using gamma radiation using cobalt 60 at 15 kGy.

#### **Clinical trial design**

The patients were selected from the outpatient's department of Periodontology, JSS Dental College and Hospital, Mysuru. By purposive sampling, patients of both sexes who fulfilled the inclusion criteria and those who had given the informed consent were enrolled for this study. Randomization was done by lottery method and the patients were allocated into two sites, the test site (A) and control site (B).

The inclusion criteria comprised of systemically healthy patients within the age group of 30-50 years both males and females, patients who were willing and had given the informed consent, patients who could maintain their oral hygiene, clinical and radiographic evidence of mandibular buccal furcation defect  $\geq 3$  mm, vital teeth, presence of at least 2 mm of keratinized gingiva on selected tooth, vertical probing depth  $\leq 4$  mm.

The exclusion criteria comprised of patients on any medication, patients on antibiotic therapy within last 3 months, medically compromised or under therapeutic regimen that could have altered the probability of tissue and bone healing, pregnancy and lactation, smokers, acute infections- HIV, metabolic bone diseases- osteoporosis, rheumatoid arthritis, teeth with mobility and hopeless prognosis.

#### **Sample size calculation**

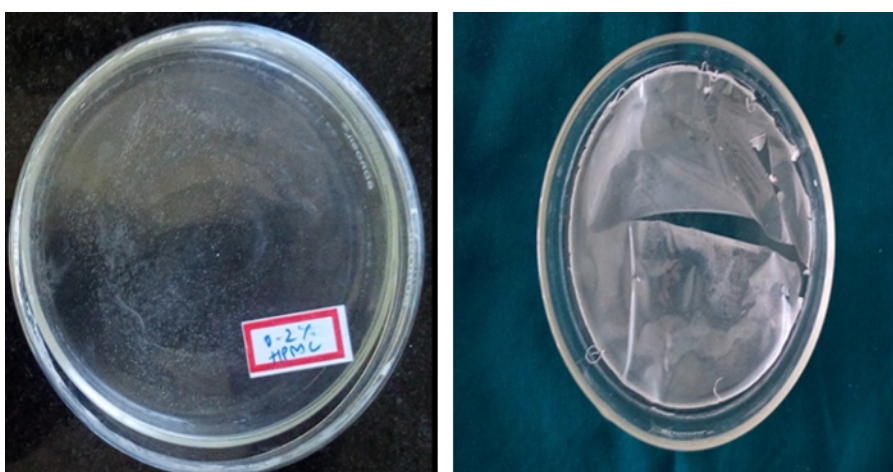This was estimated using hypothesis testing for 2 means (equal variances) using n masters software. The sample size was computed to be 11 per group at 5%  $\alpha$  error, 80% power with an effect size of 1.23 to identify a mean difference of 0.8 to be statistically significant. The sample size was finally rounded off to 15, anticipating some degree of dropouts.

#### **Study design**

This was a randomized controlled interventional study with a split-mouth design. By purposive sampling, 34 defect sites in 17 patients were selected. The selected sites were randomized using the lottery method into test and control sites (Figure 6). The randomization process was performed by an examiner blinded to the study. The allocation was concealed within opaque envelopes with numbers



**Figure 4: Fibroin solution placed in vacuum driver**



**Figure 5: Fibroin solution with 0.2%HPMC and the final silk fibroin membrane**

on it until immediately before surgery to determine which groups would receive test and control procedures.

Test site(A) – Flap surgery and the Silk Fibroin membrane with Xenograft(COLOCAST).

Control site (B) - Flap surgery and Collagen membrane(COLOGIDE) with Xenograft (COLOCAST).

#### **Ethical Clearance and Informed Consent”**

Institutional Review Board (IRB) of the JSS Academy of Higher Education and Research approved the study protocol. A prior written informed consent was taken from the participants. All principles outlined in the Declaration of Helsinki(1964, revised in 2008) on experimentation involving humans were observed. This trial was registered at clinical trials.gov as CTRI/2018/12/016509. The duration of the study was for 12 months.

#### **Pre Surgical Procedure**

Patients fulfilling the inclusion criteria and have willingly given informed consent underwent routine hematological investigations and Phase I ther-

apy comprising of scaling along with root planing. Mobility was checked for teeth with furcation involvement along with radiographic investigations.

#### **Radiographic parameters**

Conventional intraoral periapical radiographs(IOPAR) with an X-ray grid were taken with standardized parameters, exposure and processing. The films used were Kodak E speed of size 2. The grid, dental (from Bluedent India, Chennai) with RINN XCP film holder, was used. Exposures were fixed at 8mA, 70kvp with 2mm of aluminium filtration and underwent processing in an automatic processor. Radiographic assessments with grid were further analyzed using AutoCAD software 2017.

#### **Clinical data collection**

All clinical parameters were assessed by a calibrated examiner who was masked to the treatment provided. The recordings were done on the day of surgery (baseline) 3months, 6months and 12 months. The following were assessed:

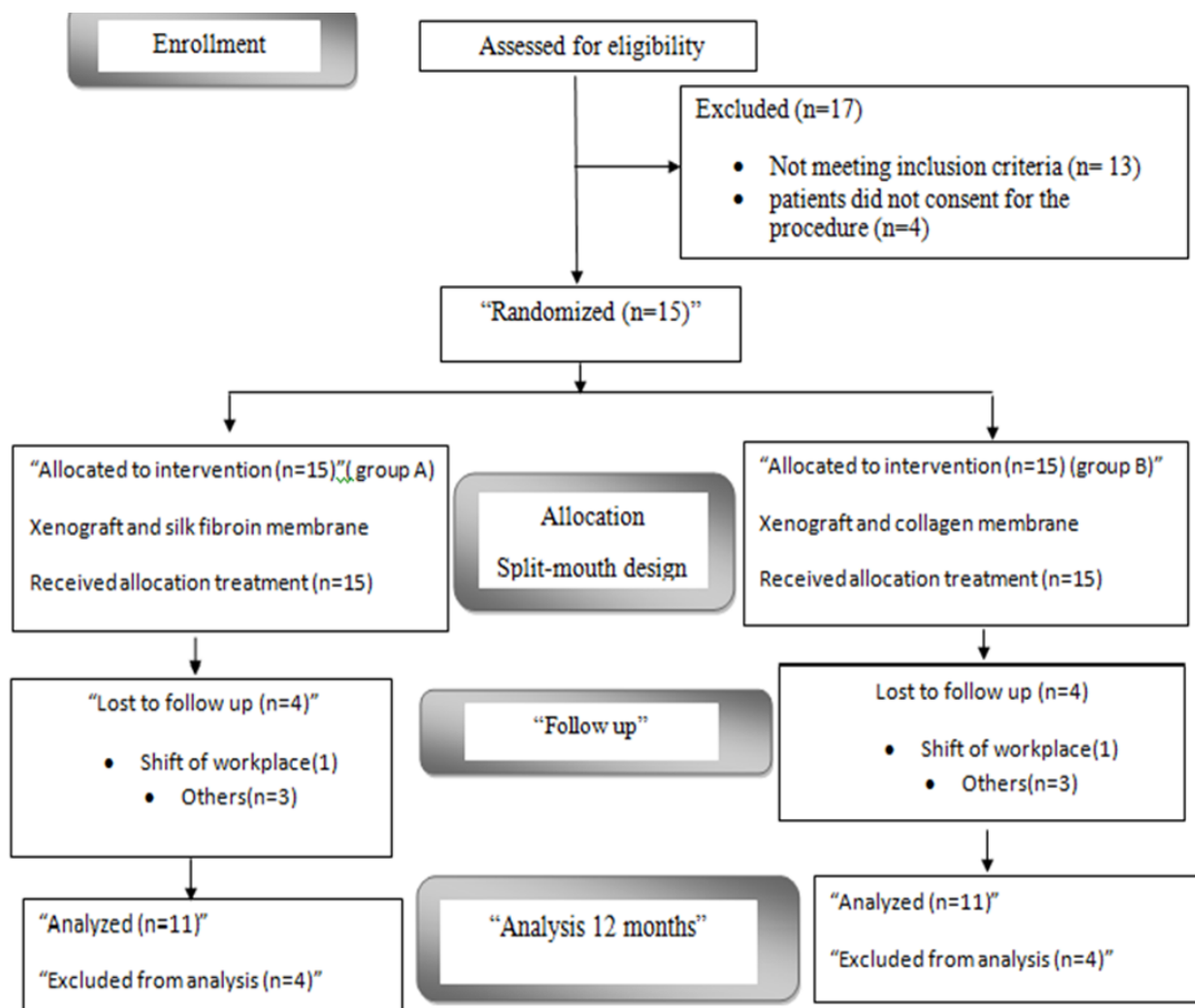


Figure 6: Flowchart

**Probing depth(PD)**

The distance between the gingival margin and the base of the pocket

**Clinical attachment level( CAL)**

The distance between the gingival margin and the base of the pocket

**Plaque index(PI)**

A mouth mirror and an explorer were used after air drying of teeth and gingiva to assess plaque. Four areas of the teeth (distofacial, facial, mesiofacial and lingual surfaces) were examined systematically for each tooth.

**Gingival index(GI)**

A mouth mirror and William’s graduated periodontal probe were used after drying the gingiva. Four areas of the teeth (distofacial papilla, facial margin, mesiofacial papilla and lingual gingival margin) were examined systematically for each tooth.

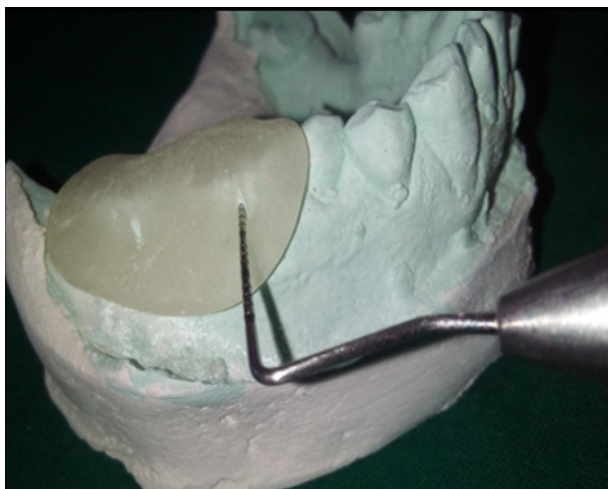**Vertical probing depth**

The UNC-15 probe was inserted into the periodontal pocket along the root surface to locate the initial fluting of the furcation. The distance from the gingival margin to the opening of the furcation was noted. The probe was then advanced apically until resistance was felt and the distance from the gingival margin to the vertical depth of probing was noted and the reading was recorded to the nearest millimeter as the difference between the two values.

**Horizontal probing depth**

A customized stent as a fixed reference point was made using self-cure clear resin extending up to the attached gingiva to go beyond the furcal entrance. A hole at the buccal extension of the stent coinciding with the furcal entrance to guide the probe penetration (UNC-15) in the same direction every time it is inserted for measurements was made. The outer surface of the hole served as the reference point for horizontal probing depth (Figure 7).

**Surgical Procedure**



**Figure 7: Acrylic stent**

After asepsis, the sites with furcal defects were anesthetized using 2% lidocaine with 1:80,000 adrenaline. Following intracrevicular incisions with blade 12, a full-thickness flap was raised using blunt dissection. The tooth, including the furcation area and bone surfaces, were carefully debrided with Gracey curettes to clear off all granulation tissue following which the root surfaces were thoroughly planed until it attained a hard and glassy surface. After instrumentation, the surgical area was irrigated thoroughly with saline to remove the remaining detached fragments. The test site received xenograft (colocast) and silk fibroin as a guided tissue regeneration (GTR) membrane (Figure 8). The contralateral control site received xenograft (COLOCAST) and collagen membrane (COLOGIDE), which was performed in less than 2 weeks (Figure 9). The flaps were repositioned and suturing was done using 3-0 silk sutures and periodontal dressing (Coe-Pak) was placed.

#### Postoperative care

Manifestations of any allergic reaction like irritation, itching, etc. were observed for 1-hour post-surgery, subsequent to which patients were discharged along with postoperative instructions. The patients were instructed to maintain their oral hygiene with regular home care, except in the operated area for a week. Antibiotics were prescribed for 5 days and analgesics were advised to be taken only if it was necessary on a 'need to treat' basis. Patients were asked to report after 7 days for suture removal and check-up.

#### Post-surgical evaluation

At one week follow up, periodontal pack and sutures were removed. The clinical parameters were evaluated at "3 months, 6 months and 12 months". Radio-

graphic parameters IOPAR with a grid which has markings of  $1\text{mm}^2$  was used as it can make linear measurements easy. These parameters were analyzed at "6 months and 12 months" using AUTO-CAD 2017 version which is a "commercial computer-aided design and drafting software application (Figure 10).

#### RESULTS AND DISCUSSION

The tensile strength of 1.1mm thick silk fibroin membrane was determined by the universal testing machine and was found to be 0.04 Newton/sqmm at peak load, and 0.001 Newton/sqmm at break load with a yield strength of 0.04 Newton/sqmm which is superior when compared to other polymers and synthetic materials (Figure 11).

The recordings from clinical and radiographic parameters were subjected to statistical analysis using SPSS version 22 software. The results were analyzed using descriptive statistics, repeated measures ANOVA and paired t-test. A total of 15 participants were selected for study, 11 of which were males and 4 were females. The mean age of males were  $40.00 \pm 5.2$ . The mean age of females were  $36 \pm 6.6$  (Table 1).

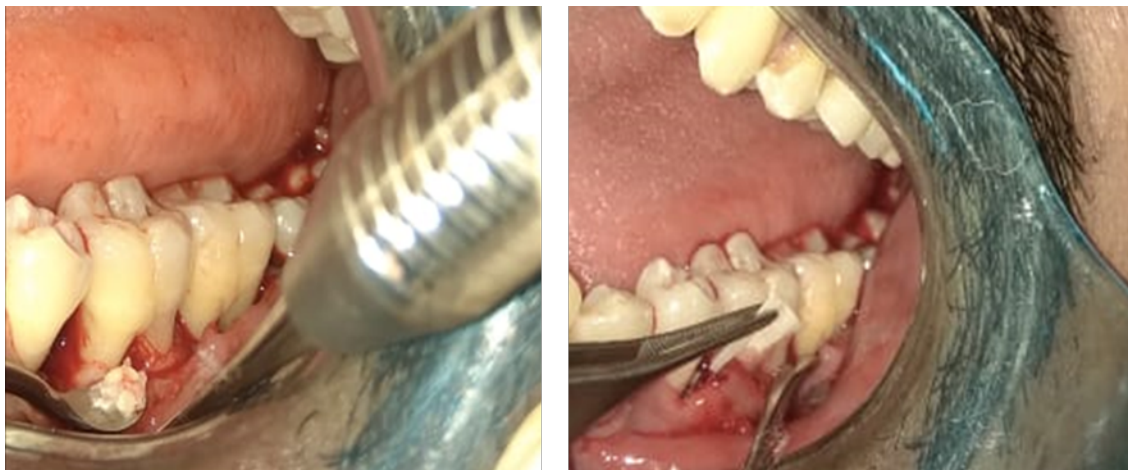
The mean plaque scores at baseline was  $1.39 \pm 0.38$ , which reduced to  $0.55 \pm 0.30$  at 12 months.

The results show statistically significance at  $p < 0.05$  indicating that the patients were maintaining good oral hygiene which had an effect on the overall outcome (Table 2).

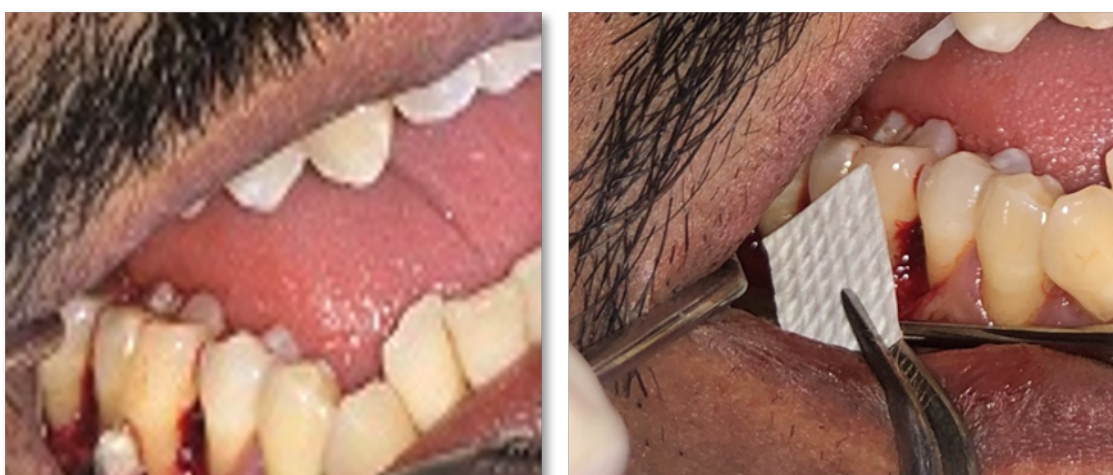The mean pocket probing depth in the test site at baseline was  $4.4 \pm 2.6$ ,  $2.45 \pm 1.03$  at 3 months,  $2.09 \pm 0.83$  at 6 months and  $1.63 \pm 0.67$  at 12 months. The mean pocket probing depth in the control sites at baseline was  $3.2 \pm 1.4$ ,  $2.81 \pm 0.87$  at 3 months,  $2.3 \pm 0.80$  at 6 months and  $1.9 \pm 0.70$  at 12 months. Both sites have shown a reduction in pocket depth. Repeated measures ANOVA has shown statistical significance where ( $p = 0.013$ ) (Table 3) (Figure 12).

The reduction could be due to the complete debridement of the defect as furcations are inaccessible for instrumentation and thereby, flap surgery would have facilitated incomplete debridement of the area, thereby causing a reduction in pocket probing depth.

The mean CAL at baseline is  $2.3 \pm 1.2$ , at 3 months it was  $1.8 \pm 0.87$ , at 6 months was  $1.2 \pm 0.46$  and at 12 months is  $1.00 \pm 0.63$ . The mean CAL at the test site had reduced from baseline to 12 months. At the control sites, it was  $2.5 \pm 1.5$  at baseline, at 3 months  $2.4 \pm 1.3$ , at 6 months  $2.00 \pm 1.41$  and at 12 months  $1.4 \pm 1.1$ . This shows a mean reduction in



**Figure 8: Bone graft and silk fibroin membrane in the test site**



**Figure 9: Bone graft and Cologide in the control site**

**Table 1: Demographic data**

|       | N  | Mean    | Std. Deviation | Std. Error | Minimum | Maximum |
|-------|----|---------|----------------|------------|---------|---------|
| M     | 11 | 40.0000 | 5.25357        |            | 33.00   | 48.00   |
| F     | 4  | 36.7500 | 6.65207        | 3.32603    | 31.00   | 43.00   |
| Total | 15 | 39.1333 | 5.60442        | 1.44706    | 31.00   | 48.00   |

**Table 2: Plaque and Gingival index scores**

|           | Plaque index | p value | Gingival index | p value <sup>a</sup> |
|-----------|--------------|---------|----------------|----------------------|
| Baseline  | 1.3918       |         | 1.5145         |                      |
| 3 months  | 1.1282       | 0.00    | 1.1255         | 0.00                 |
| 6 months  | .7727        |         | .7827          |                      |
| 12 months | .5527        |         | .5145          |                      |

<sup>a</sup>P value < 0.05 is significant

**Table 3: Mean probing depth, clinical attachment level, Horizontal and Vertical probing depths**

|          | Probing depth |         | Clinical attachment level |         | Horizontal Probing depth |         | Vertical probing depth |         |
|----------|---------------|---------|---------------------------|---------|--------------------------|---------|------------------------|---------|
|          | test          | control | test                      | control | test                     | control | test                   | control |
| Baseline | 4.4545        | 3.2727  | 2.3636                    | 2.5455  | 3.6364                   | 3.8182  | 3.4545                 | 3.1818  |
| 3months  | 2.4545        | 2.8182  | 1.8182                    | 2.4545  | 3.1818                   | 3.5455  | 3.0909                 | 2.7273  |
| 6months  | 2.0909        | 2.3636  | 1.2727                    | 2.0000  | 2.0000                   | 2.9091  | 2.6364                 | 2.3636  |
| 12months | 1.6364        | 1.9091  | 1.0000                    | 1.4545  | 1.3636                   | 2.4545  | 2.0000                 | 1.9091  |
|          | p=.013        |         | p=0.25                    |         | p=0.011                  |         | p=.795                 |         |

**Table 4: Mean Horizontal Bone Width, Vertical Bone Height and Bone Area Fill**

|          | Horizontal bone width |         | Vertical bone height |         | Bone area fill |         |
|----------|-----------------------|---------|----------------------|---------|----------------|---------|
|          | test                  | control | test                 | control | test           | control |
| baseline | 2.4581                | 2.2256  | 2.3640               | 2.3751  | 3.1636         | 2.7545  |
| 6months  | 2.5237                | 2.2026  | 2.4120               | 2.3004  | 3.6636         | 2.7636  |
| 12months | 2.6704                | 2.4311  | 2.5475               | 2.4125  | 4.5409         | 3.1636  |
|          | p=.010                |         | p=.064               |         | p=.03          |         |

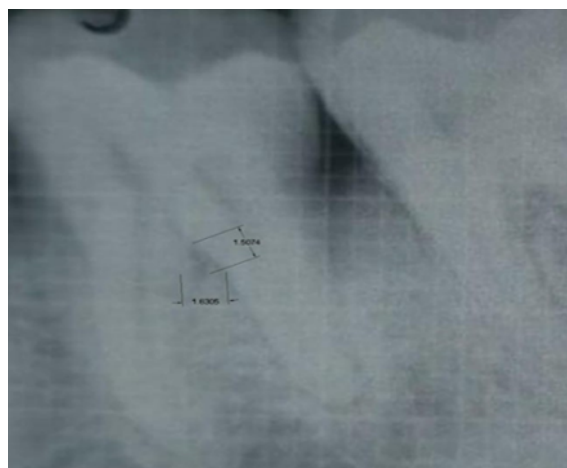CAL at the control sites as well over a period of 12 months. Repeated measures ANOVA shows statistically insignificance as  $p=0.25$ (Table 3),(Figure 13).

A statistical significance was also noted at the 3<sup>rd</sup> to 6<sup>th</sup> and 12 months in the test sites ( $p=0.006$  and  $p=0.01$ ) and in the control sites only at the 6<sup>th</sup> and 12th months ( $p=0.006$ ,  $p=0.00$ ). This could be a result of true periodontal regeneration via new attachment or of healing by repair. This is in accordance to a study where bilateral Class II furcation defects on lower first molars showed improvement in clinical attachment level (CAL) and change in class of clinically detectable furcation involvement when treated with bone graft and a barrier membrane (Leonardis *et al.*, 1999).

The test site shows a mean horizontal probing depth (HPD) of  $3.6 \pm 0.92$  at baseline,  $3.18 \pm 1.16$  at 3 months,  $2.00 \pm 0.77$  at 6 months and  $1.36 \pm 0.50$  at 12 months. The control site shows a mean HPD of  $3.8 \pm 1.07$  at baseline,  $3.5 \pm 1.2$  at 3 months,  $2.9 \pm 1.0$  at 6 months and  $2.4 \pm 1.0$  at 12 months. Both the sites have shown a reduction in mean HPD from baseline to 12 months with a greater reduction observed in the test sites. Repeated measures ANOVA showed a statistical significance of ( $p=0.01$ ) in the test sites (Table 3),(Figure 14).

This has been explained by factors such as partially resorbed particles of the bone graft used which can hinder probe penetration, true regeneration of connective attachment, which may have created and maintained a larger space underneath the barrier, allowing for selective cell repopulation (Urist, 1965)

or increased bone formation mainly induced by the xenograft and silk fibroin. Although this is supported by some studies, it requires further investigation.

**Figure 10: AUTOCAD software to measure bone fill in furcation**

The test sites have shown a mean vertical probing depth (VPD) to be  $3.4 \pm 0.68$  at baseline,  $3.0 \pm 0.83$  at 3 months,  $2.6 \pm 0.50$  at 6 months and  $2.0 \pm 0.77$  at 12 months. The control sites showed a mean of  $3.1 \pm 0.60$  at baseline,  $2.7 \pm 0.64$  at 3 months,  $2.3 \pm 1.02$  at 6 months and  $1.9 \pm 0.70$  at 12 months. Both the sites have shown a reduction in VPDs from baseline to 12 months. Repeated measures ANOVA is not statistically significant as ( $p=0.795$ ) This could be attributed to an increase in CAL (Table 3),(Figure 15)

#### Radiographic parameters



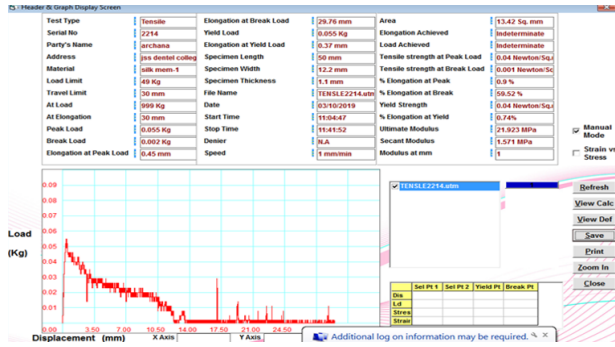


Figure 11: Tensile strength of silk fibroin membrane

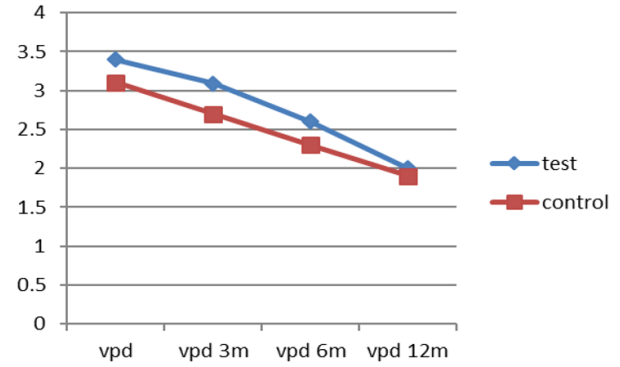


Figure 15: Vertical probing depth

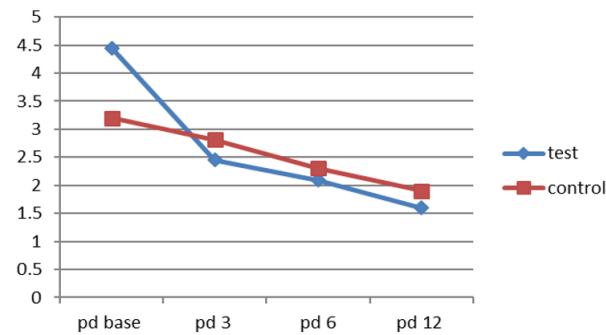


Figure 12: Pocket probing depth

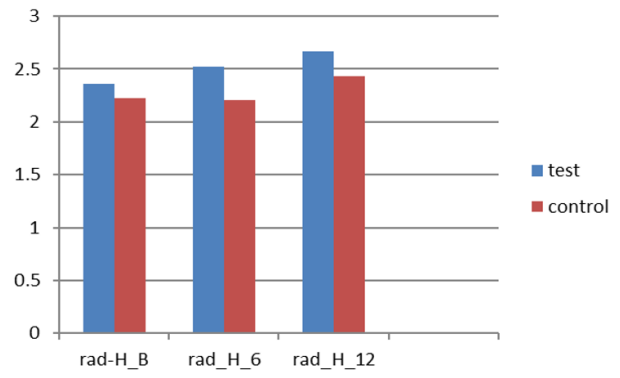


Figure 16: Horizontal bone width(H)

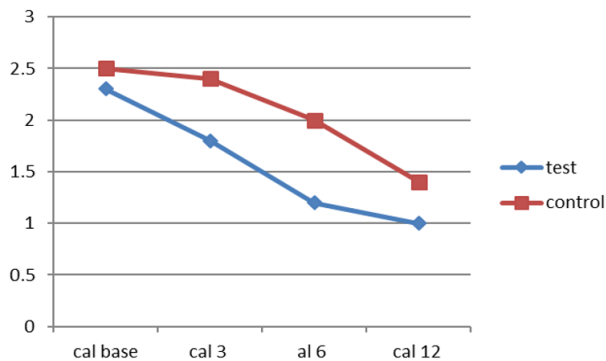


Figure 13: Cal (clinical attachment level)

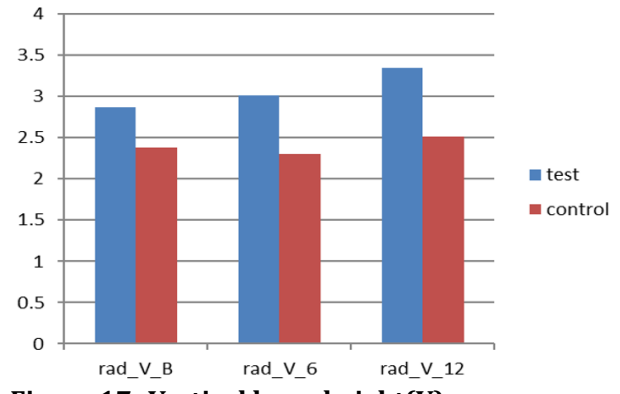


Figure 17: Vertical bone height(V)

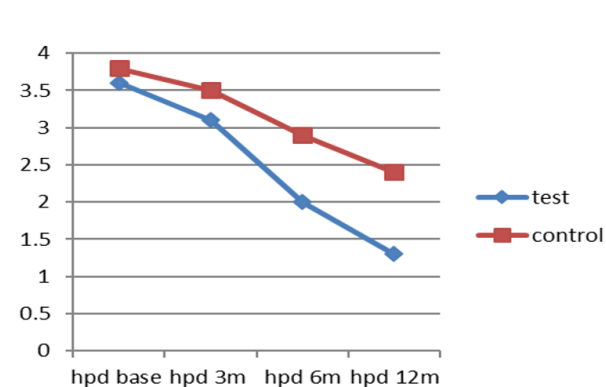


Figure 14: Horizontal probing depth

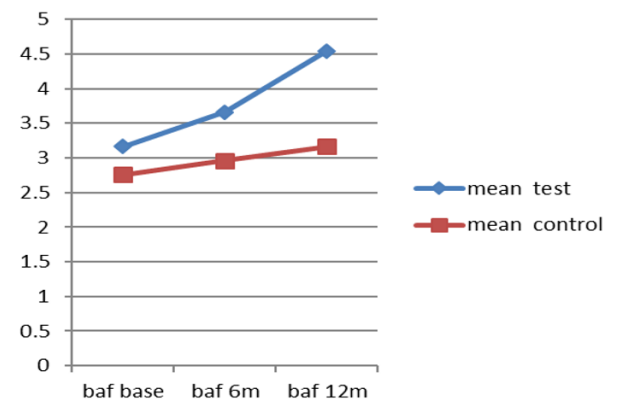


Figure 18: Bone area fill(A)

All the changes in bone fill were detected radiographically using consecutive radiographs. Conventional IOPAR with grid were used as reduces scattered radiation and improves image contrast (Deshpande and Bhargava, 2014). The radiographs were subjected to AUTOCAD version 2017 for analysis. The radiographs were enlarged to twice the original dimension and the area of interest was marked digitally so that any differences between preoperative and postoperative changes could be calculated. Although the X-ray grid can evaluate bone changes, AUTOCAD is more precise and can give values upto decimal points (Melke et al., 2016; Gowda et al., 2011). This is in accordance to a study done by (Yajamanya et al., 2017).

The test sites showed a mean horizontal bone width(H) of  $2.4 \pm 0.70$  at baseline,  $2.5 \pm 0.70$  at 6 months and  $2.6 \pm 0.50$  at 12 months. The control sites showed a mean (H) of  $2.2 \pm 0.73$  at baseline,  $2.2 \pm 0.54$  at 6 months and  $2.4 \pm 0.58$  at 12 months. Both the sites have shown improvements in(H) from baseline to 12 months. Repeated measures ANOVA shows statistical significance where ( $p=0.010$ ) with a higher significance for test sites (Table 4),(Figure 16).

The result is in accordance to a study by (Mobini et al., 2013; Bhumiratana et al., 2011) who showed the growth of mineralized bone matrix on silk scaffolds was a result of enhanced differentiation and faster recruitment of cells.

The test sites showed a mean radiographic vertical bone height(V) of  $2.3 \pm 0.88$  at baseline,  $2.4 \pm 0.85$  at 6 months and  $2.5 \pm 0.68$  at 12 months. The control sites showed a mean (V) of  $2.3 \pm 0.56$  at baseline,  $2.3 \pm 0.53$  at 6 months and  $2.4 \pm 0.41$  at 12 months. Both the sites have shown improvements in(V) from baseline to 12 months. Repeated measures ANOVA is not significant as ( $p = 0.064$ )(Table 4),(Figure 17).

The test sites show a mean bone area fill (A) of  $3.1 \pm 1.0$  at baseline,  $3.6 \pm 1.0$  at 6 months and  $4.5 \pm 1.5$  at 12 months. The control sites showed a mean (A) of  $2.7 \pm 1.2$  at baseline,  $2.7 \pm 1.2$  at 6 months and  $3.1 \pm 1.3$  at 12 months. Both the sites have shown an increase in the bone area fill from baseline to 12 months. Repeated measures ANOVA showed statistical significance ( $p=0.03$ ) in test sites (Table 4),(Figure 18).

These results are in accordance to the results of a meta-analysis of 10 studies that showed statistically significant greater vertical and horizontal bone fill for GTR + Osseous graft(OG) with OFD in furcation defects (Chen et al., 2013; McClain and Schallhorn, 1993b). It is also in accordance to a study

where bone volume in the Silk Fibroin group at 4 weeks were greater than in the Bio-Gide group in Sprague-Dawley rats (Lu et al., 2015; Seok et al., 2014) who showed that New Zealand white rabbits when treated with silk membranes of 0.5mm thickness, resulting in effective bone regeneration.

From the results of the study, it has been clearly stated that silk fibroin throws light to expand the family of regenerative barrier membranes with an enhanced performance for bone regeneration in the field of dentistry. It can thus be considered as a better material for periodontal regeneration with further longitudinal clinical trials.

### Future perspectives

Factors influencing the furcation fill, such as divergence of roots and interproximal bone height in association to the fornix of the furcation, needs to be evaluated. To confirm the regenerative potential of silk fibroin, a histological study needs to be done. Biodegradability studies would throw better light to the function of silk as a barrier membrane.

### Limitations of this study

Considering the prevalence of mandibular grade II furcation defects, the sample size was small. The degree of dropouts were high. The study did not compare xenograft with open flap debridement vs. silk fibroin and open flap debridement to know which among these components had lead to clinical and radiographic improvements. Though evidence from animal studies have shown that silk is highly biocompatible, nontoxic and degrades over a period of 1 year, cytotoxicity and biodegradability studies would have confirmed the results (Wang et al., 2008). Histological assessment of regeneration was not done.

### CONCLUSIONS

In this study, silk fibroin membranes were prepared and compared to collagen as it has advantages like good biocompatibility, better mechanical properties and slow biodegradability. Preclinical and clinical studies were carried out in animals to establish its efficacy in tissue engineering. This was the first human trial where silk fibroin as a scaffold was used in periodontal regeneration. Within the limitations, the study has proved that silk fibroin with xenograft alone is better when compared to collagen with xenograft. This study has also proved the efficacy of silk fibroin with xenograft over collagen with xenograft in treating grade II furcation defects. However, further longitudinal studies with larger sample size, longer follow up and detailed characterization is essential to prove its potential in peri-

odontal regeneration.

## REFERENCES

- Bhumiratana, S., Grayson, W. L., Castaneda, A., Rockwood, D. N., Gil, E. S., Kaplan, D. L., Vunjak-Novakovic, G. 2011. Nucleation and growth of mineralized bone matrix on silk-hydroxyapatite composite scaffolds. *Biomaterials*, 32(11):2812–2820.
- Chen, T. H., Tu, Y. K., Yen, C. C., Lu, H. K. 2013. A systematic review and meta-analysis of guided tissue regeneration/osseous grafting for the treatment of Class II furcation defects. *Journal of Dental Sciences*, 8(3):209–224.
- Deshpande, A., Bhargava, D. 2014. Intraoral Periapical Radiographs with Grids for Implant Dentistry. *Journal of Maxillofacial and Oral Surgery*, 13(4):603–605.
- Gowda, V., Kumara, A. G., Chava, V. 2011. An evaluation of a resorbable (semirigid) GTR membrane in human periodontal intraosseous defects: A clinic radiological re-entry study. *Journal of Indian Society of Periodontology*, 15(4):393–397.
- Lekovic, V., Kenney, E. B., Carranza, F. A., Danilovic, V. 1990. Treatment of Class II Furcation Defects Using Porous Hydroxylapatite in Conjunction With a Polytetrafluoroethylene Membrane. *Journal of Periodontology*, 61(9):575–578.
- Leonardis, D. D., Garg, A. K., Pedrazzoli, V., Pecora, G. E. 1999. Clinical Evaluation of the Treatment of Class II Furcation Involvements With Bioabsorbable Barriers Alone or Associated With Demineralized Freeze-Dried Bone Allografts. *Journal of Periodontology*, 70(1):8–12.
- Lu, S., Wang, P., Zhang, F., Zhou, X., Zuo, B., You, X., Tang, H. 2015. A novel silk fibroin nanofibrous membrane for guided bone regeneration: a study in rat calvarial defects. *American Journal of Translational Research*, 7(11):2244–2253.
- McClain, P. K., Schallhorn, R. G. 1993a. Long-term assessment of combined osseous composite grafting, root conditioning, and guided tissue regeneration. *The International Journal of Periodontics & Restorative Dentistry*.
- McClain, P. K., Schallhorn, R. G. 1993b. Long-term assessment of combined osseous composite grafting, root conditioning, and guided tissue regeneration. *The International Journal of Periodontics & Restorative Dentistry*, 13:9–9.
- Melke, J., Midha, S., Ghosh, S., Ito, K., Hofmann, S. 2016. Silk fibroin as biomaterial for bone tissue engineering. *Acta Biomaterialia*, 31:1–16.
- Mobini, S., Hoyer, B., Solati-Hashjin, M., Lode, A., Nosoudi, N., Samadikuchaksaraei, A., Gelin-sky, M. 2013. Fabrication and characterization of regenerated silk scaffolds reinforced with natural silk fibers for bone tissue engineering. *Journal of Biomedical Materials Research Part A*, 101(8):2392–2404.
- Nagal, A., Singla, R. K. 2013. Applications of Silk in Drug Delivery: Advancement in Pharmaceutical Dosage Forms. *Cureus*, 3(3):204–211.
- Sanz, M., Jepsen, K., Eickholz, P., Jepsen, S. 2015. Clinical concepts for regenerative therapy in furcations. *Periodontology*, 68(1):308–332.
- Seok, H., Kim, M. K., Kim, S. G., Kweon, H. 2014. Comparison of Silkworm-Cocoon-Derived Silk Membranes of Two Different Thicknesses for Guided Bone Regeneration. *The Journal of Craniofacial Surgery*, 25(6):2066–2069.
- Urist, M. R. 1965. Bone: Formation by Autoinduction. *Science*, 150(3698):893–899.
- Wallace, S. C., Gellin, R. G., Miller, M. C., Mishkin, D. J. 1994. Guided Tissue Regeneration With and Without Decalcified Freeze-Dried Bone in Mandibular Class II Furcation Invasions. *Journal of Periodontology*, 65(3):244–254.
- Wang, Y., Rudym, D. D., Walsh, A., Abrahamsen, L., Kim, H. J., Kim, H. S., Kaplan, D. L. 2008. In vivo degradation of three-dimensional silk fibroin scaffolds. *Biomaterials*, 29:3415–3428.
- Yajamanya, S., Chatterjee, A., Hussain, A., Coutinho, A., Das, S., Subbaiah, S. 2017. Bioactive glass versus autologous platelet-rich fibrin for treating periodontal intrabony defects: A comparative clinical study. *Journal of Indian Society of Periodontology*, 21(1):32–32.
- Yang, C., Lee, J. S., Jung, U. W., Seo, Y. K., Park, J. K., Choi, S. H. 2013. Periodontal regeneration with nano-hydroxyapatite-coated silk scaffolds in dogs. *Journal of Periodontal & Implant Science*, 43(6):315–315.