



## To Evaluate Aloe Vera- Chitosan Based Surgical Dressing to Chitosan Dressing Alone on the Healing of Palatal Donor Sites - A Pilot Study

Archana R Sankar<sup>1</sup>, Sheela Kumar Gujjari<sup>\*1</sup>, Kulkarni P K<sup>2</sup>

<sup>1</sup>Department of Periodontology, JSS Dental College and Hospital, Mysuru, Karnataka, India

<sup>2</sup>Department of Pharmaceutics, JSS College of Pharmacy, Mysuru, Karnataka, India



### Article History:

Received on: 15 Aug 2021

Revised on: 18 Sep 2021

Accepted on: 20 Sep 2021

### Keywords:

Aloe vera,  
Chitosan,  
Free Gingival Graft,  
Gingival Recession,  
Healing,  
Visual Analog Scale

### ABSTRACT

The present study was undertaken to clinically assess the synergistic effect of topically applied Aloe vera Chitosan to Chitosan alone on the healing of palatal donor sites in free gingival graft surgical procedures. 20 subjects (10 per group) were enrolled into this triple blinded randomized clinical trial, designed to evaluate the efficacy of Aloe vera Chitosan to Chitosan on free gingival graft surgical wounds. Subjects were assigned to either Group A (aloe vera + Chitosan) or Group B (Chitosan alone). Visual Analog Scale (VAS) and Wound healing index were recorded at 7<sup>th</sup> day, 14<sup>th</sup> day and 21 days postoperative. Results showed no statistical significance when considering VAS. However there was a statistical significance in wound healing ( $p=0.04$ ) in group A when compared to group B from 14- 21<sup>st</sup> day postoperative. It is the first human trial and was a pilot study to assess the synergistic effect of Aloe vera and Chitosan on wound healing. The study has shown that a combination of both acts synergistically in accelerating healing especially in areas where faster healing is necessary to provide overall comfort to the patient. It is therefore a futuristic and a promising material as a surgical dressing with further longitudinal trials.

### \*Corresponding Author

Name: Sheela Kumar Gujjari

Phone: 9448836777

Email: [sheelagujjari@gmail.com](mailto:sheelagujjari@gmail.com)

ISSN: 0975-7538

DOI: <https://doi.org/10.26452/ijrps.v12i4.4901>

Production and Hosted by

IJRPS | [www.ijrps.com](http://www.ijrps.com)

© 2021 | All rights reserved.

are noted (Kathariya *et al.*, 2015; Patel *et al.*, 2012). The migration, infiltration, proliferation and differentiation of these cells culminates in an inflammatory response, the formation of new tissue and ultimately closure of the wound. The oral cavity provides a unique environmental challenge for the epithelial healing of oral wounds produced during various periodontal procedures such as mucogingival surgeries where graft harvesting is required from donor site. The ability of the oral mucosa to repair itself after wounding is remarkable as it involves large exposure of the surgical area leading to pain, discomfort and healing by secondary intention.

### INTRODUCTION

Wound healing is a complex and dynamic process where cellular structures and tissue layers are formed which results in function and restoration of injured tissue. A coordinated effort of epithelial cells with several other cell types including fibroblasts, endothelial cells, macrophages and platelets

Various dressings have been used in periodontal therapy to protect the wound, the most popular being Eugenol (Wondr Pack) and Non Eugenol (Coe Pak) (Kathariya *et al.*, 2015). Whether to place a pack or not is still a controversy (Kathariya *et al.*, 2015) but in certain conditions where there is expo-

sure of large wound area such as in free gingival grafts, gingivectomies, depigmentation, there is still a need to protect the wound. Apart from these dressings ozonated oil (Patel *et al.*, 2012), erythropoietin (Yaghobee *et al.*, 2018) and plant extracts have also been tried to protect the wound in the palatal donor site which lead to overall patient comfort and stabilization of clot which is an essential element for wound healing. Though various dressings have shown improvement, the search is still on for an ideal surgical dressing material.

Various animal studies (Tameshloo *et al.*, 2012; Faleiro *et al.*, 2009) have demonstrated the healing potential of Aloe vera as it increases the blood supply, oxygenation, cell proliferating activity (Oliveira *et al.*, 2010; Chithra *et al.*, 1998), antibacterial, antiviral, antifungal and anti inflammatory properties (Oryan *et al.*, 2016; Atiba *et al.*, 2011; Wynn, 2005) which has kindled an interest among researchers in its usage as a dressing. Recently much of interest has also been developed towards Chitosan, a biopolymer obtained from the deacetylation of chitin a naturally occurring and abundantly available (in marine crustaceans) biocompatible polysaccharide (Ahmed and Ikram, 2016).

Evidence from animal studies have shown excellent biocompatibility, biodegradability, non-toxicity and non-allergenic nature and its potential role as an antimicrobial and anti inflammatory substance, ultimately resulting in favourable wound healing (Jayakumar *et al.*, 2011; Kmiec *et al.*, 2017; Ahmed and Ikram, 2015). It has been hypothesized that the mechanism of action of Aloe vera and Chitosan on wound healing may be connected in part to their antimicrobial effect but also with its ability to promote the liberation of growth factors, activate local antioxidant mechanisms and promote tissue repair.

Chitosan is shown to be highly mucoadhesive (Ways *et al.*, 2018) which helps in the retention of the dressing in the palate. An attempt was made to incorporate Aloe vera into Chitosan as Chitosan is essential to stabilize the polysaccharides present in Aloe vera which in turn helps to keep its natural biological activity stable (Silva *et al.*, 2013).

Although abundant animal studies are done with Aloe vera and Chitosan in the field of medicine, there are no human studies with a combination of both. Thus, this study was done to evaluate the synergistic efficacy of Aloe vera Chitosan based surgical dressing to Chitosan surgical dressing alone on healing of palatal surgical wounds.

## MATERIALS AND METHODS

### Materials used in the study

1. Commercially obtained high molecular weight Chitosan, with a degree of deacetylation above 85% was purchased from Everest Biotech, Bengaluru, Karnataka.
2. Commercially available Aloe vera gel (Patanjali) obtained from local markets.

### Preparation of Chitosan-Aloe Vera Blend

The gel form of chitosan was obtained by adding 5 g of commercially purchased chitosan to 100 mL of water in a blender for 10 min until the hydrogel was formed which was then packed in a sterile tubes, sealed and UV sterilized later. Preparation of Aloe vera Chitosan comprised of adding commercially obtained Aloe vera gel into the Chitosan gel (at a ratio of 1:2 v/v) which was stirred thoroughly to obtain a uniform mixture and was dispensed into sterile aluminium tubes (Silva *et al.*, 2013; Adil, 2016). Both gels had the same texture and colour. The tubes were coded as A and B. The coding was done by a Professor in Pharmacy which was decoded after the study (Figure 1).

The patients were selected from the outpatient's department of Periodontology, JSS Dental College and Hospital, Mysuru. By purposive sampling, patients of both sexes who fulfilled the inclusion criteria and who had given the informed consent were enrolled for this study. Randomization was done by lottery method and the patients were allocated into two groups (A) and (B) (Chart 1).

Group A- "Aloe vera- Chitosan dressing"

Group B- "Chitosan dressing alone"

The inclusion criteria comprised of systemically healthy patients within the age group of 20-40 both males and females, patients willing to undergo soft tissue grafts, Teeth showing localized recession in upper or lower anterior sextant, Subjects with Millers class I/II  $\geq 3$ mm who required soft tissue grafting, who were able to and willing to follow study procedure and instructions.

The exclusion criteria comprised of patients on medications such as antibiotics, corticosteroids, hormonal drugs in the past 2 months, systemic conditions known to affect the outcomes of periodontal therapy immunocompromised patients, smokers, pregnant and lactating women, subjects with prominent root surface, soft tissue loss interproximally, periodontal pockets, grade II or higher mobility, cervical abrasions restored.

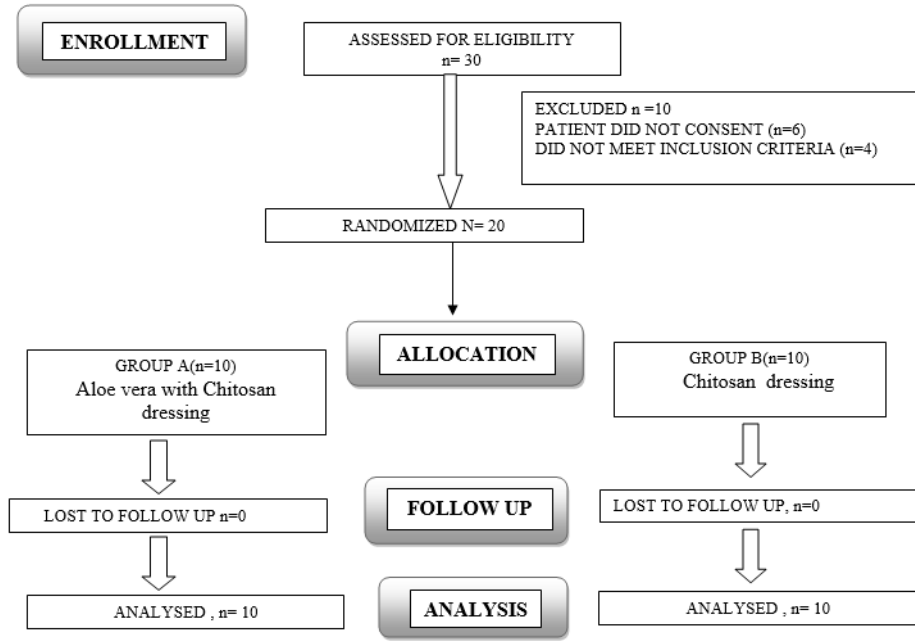
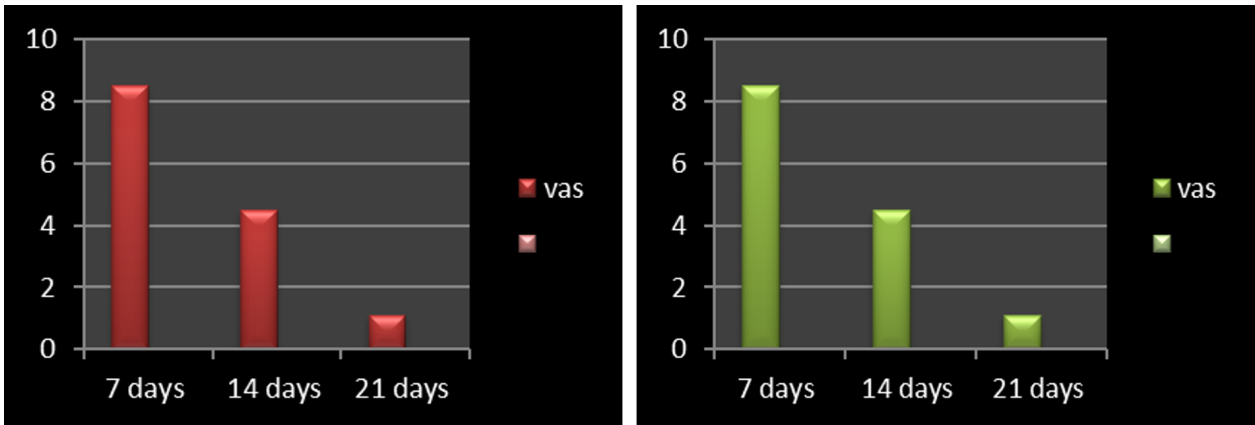
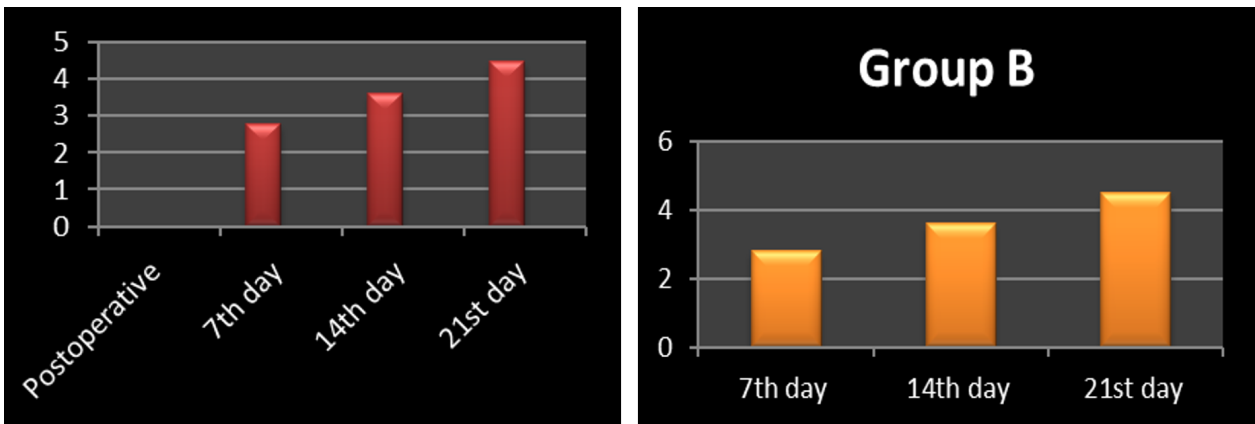


Chart 1: CONSORT chart



Graph 1: VAS



Graph 2: Healing Index Scores



(a)



(b)



(a)

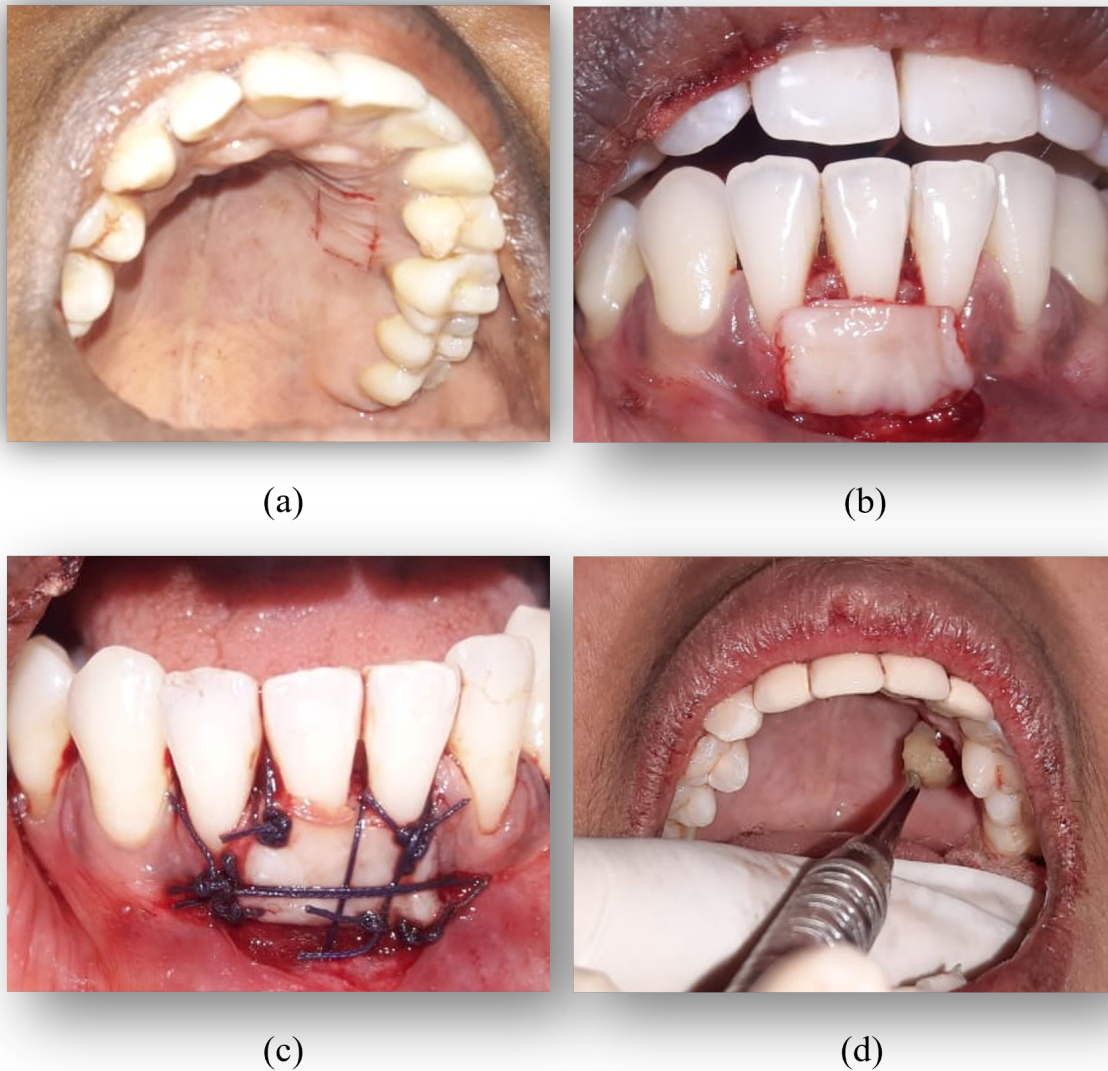


(d)

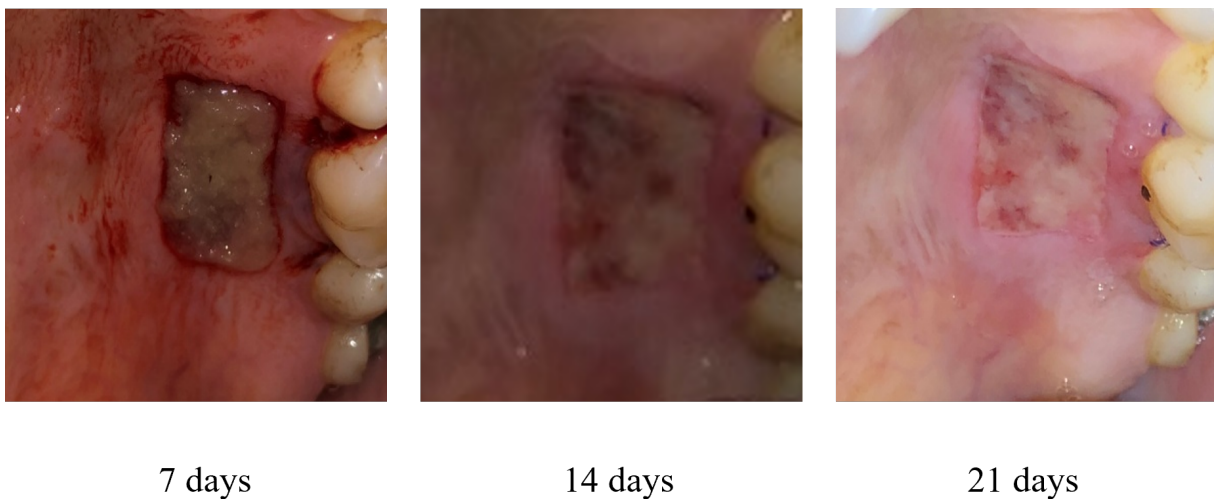


**Figure 1: Preparation of a blend of Aloe vera and Chitosan. (a & b) addition of Chitosan to Aloe vera gel & mixing both (c & d) transferring the mix to sterile packing tubes and sealing the ends**

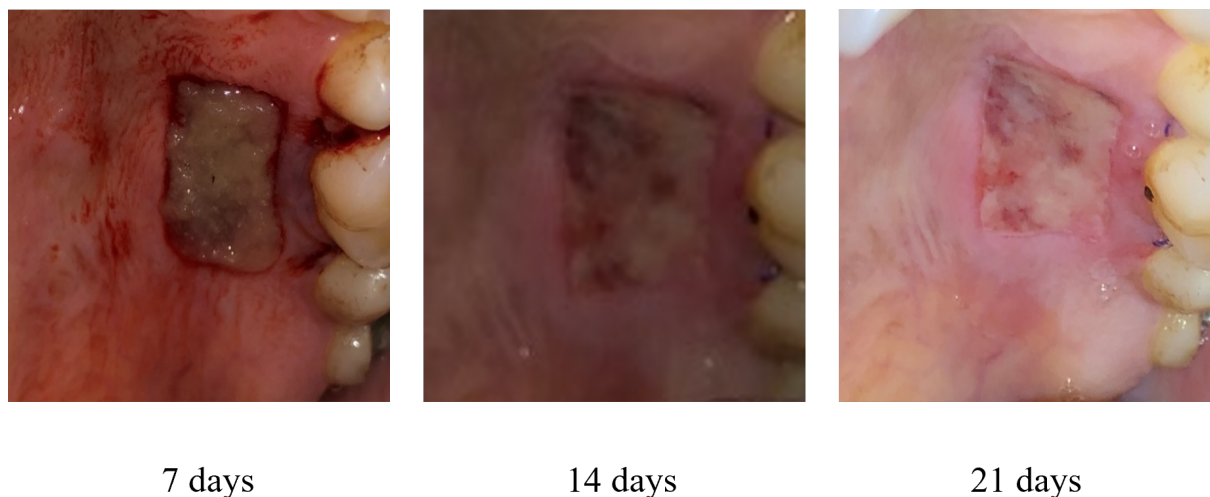




**Figure 2: Root Coverage Using Free Gingival Graft. (a) donor site for graft harvesting. (b & c) graft placed onto recipient bed and sutured (d) application of the gel either Aloe vera - Chitosan or Chitosan alone**



**Figure 3: Aloe Vera and Chitosan Group**



**Figure 4: Chitosan Group**

### Sample Size Calculation

The sample size was estimated based on hypothesis testing for two means (equal variance assumed) using n Masters software. The sample size was estimated to be 8 per group at a mean difference of 0.9, effect size 1.38, 80% power and 5% level of significance. Finally the sample size was rounded off to 10 per group (20 patients) anticipating some degree of drop out.

### Study Design

The study was a parallel arm, triple blinded, randomized controlled study which was carried out from August 2019 to February 2020. By purposive sampling, 10 subjects per group were selected. The randomization process was performed by an examiner blinded to the study. The allocation was concealed within opaque envelopes with numbers on it until immediately before surgery to determine which subjects would fall into Group A and Group B.

### Ethical Clearance and Informed Consent

Institutional Review Board (IRB) of JSS Academy of Higher Education and Research approved the study protocol. A prior written informed consent was taken from the participants. All principles outlined in the Declaration of Helsinki (1964, revised in 2008) on experimentation involving humans were observed.

### Pre Surgical Procedure

Patients fulfilling the inclusion criteria and have willingly given informed consent underwent routine hematological investigations and phase I therapy comprising of scaling along with root planing.

### Clinical Data Collection

Clinical parameters were recorded at baseline and on recall visits at 7<sup>th</sup>, 14<sup>th</sup>, 21<sup>st</sup> days and 1 month.

The clinical parameters recorded were

1. Wound Healing Index of Landry, Turnbull and Howley ([Landry et al., 1988](#)).
2. Wong Becker Visual analog scale

After examination and completion of initial periodontal therapy subjects with full mouth plaque score (FMPS) < 20% were selected for surgery. Before surgery, an impression of the palate was made to prepare a stent for donor site protection. All surgeries were performed by the same surgeon blinded to the study. The surgery was carried out according to the method of Sullivan and Atkins ([Sullivan and Atkins, 1968](#)).

After asepsis, the sites (donor+recipient) were anesthetized using 2% lidocaine with 1:80,000 adrenaline. The recipient bed was prepared by de-epithelialization. A standardized 10 × 15 mm template was used to obtain an identical palatal wound area. The donor site for graft harvesting was chosen to be distal to canine (to avoid the rugae) upto the 1<sup>st</sup> molar palatally ([Song et al., 2008](#)). Harvesting grafts from the same site in all patients resulted in a uniform technique to compensate for the differences in healing potentials. A rectangular shaped graft of sufficient thickness (upto 1.5mm) was harvested by sharp split thickness dissection. Care was taken to place the incision at least 2 mm apical from the gingival margins.

After graft removal wet gauze was compressed to the donor site with finger pressure until hemostasis was achieved. The graft was then sutured to recipient site using 5-0 vicryl. After suturing of graft, Group A received Aloe vera with Chitosan dressing

in the donor site and Group B received only Chitosan dressing which was done using sterile applicator tips and before the placement of stent (Figure 2). A soft stent was used to protect the wounded sites in both groups. Patients were advised to keep the stent in place for 1 week after which it was carefully removed for evaluation.

### Postoperative Care

Participants were instructed to avoid eating and drinking acidic/hot food. Manifestations of any allergic reaction like irritation, itching, etc. were observed for 1-hour post-surgery, subsequent to which patients were discharged along with postoperative instructions. The patients were instructed to maintain their oral hygiene with regular home care, except in the operated area. Antibiotic (Amoxicillin 500mg) was prescribed for 5 days and Analgesic (Aceclofenac 100 mg) was advised to be taken only if it was necessary on a 'need to treat' basis. The patients were also asked to make a note of the number of analgesics consumed along with the duration in a notebook.

At each appointment on the 7<sup>th</sup>, 14 and 21<sup>st</sup> days postoperatively, Visual Analog Scale ranging from 0 (no pain) to 10 (worst imaginable pain) (Chawla et al., 2016) and wound healing were assessed. Wound healing was assessed clinically using a Healing index by Landry et al., which grades the wound on a scale of 1-5 (Table 1) where 1 indicates very poor healing and 5 indicates excellent healing (Landry et al., 1988; Lingamaneni et al., 2019). The scores were given by a different examiner. The patients were also followed up routinely for a period of 3 months.

### Statistical Analysis

The results were analyzed using descriptive statistics, one way ANOVA and paired t-test using SPSS version 22 software.

### RESULTS

The study aimed to evaluate the synergistic efficacy of Aloe vera Chitosan based surgical dressing to Chitosan surgical dressing alone on healing of palatal surgical wounds. It was a parallel arm, triple blinded randomized controlled study wherein 10 subjects per group were selected and received either a combination of Aloe vera Chitosan or Chitosan alone.

After surgery the donor site of both groups received either a combination of Aloe vera- Chitosan or Chitosan dressing alone. No untoward incidents were reported. Patients were assessed for VAS and wound healing at 7<sup>th</sup> day, 14<sup>th</sup> day, 21<sup>st</sup> day and 1 month postoperative as complete epithelization requires

at least 1 month according to a study by Yaghobee et al. (2018).

A total of 20 participants were selected for study, 15 of which were males and 5 were females. The mean age of males were  $34.00 \pm 5.2$ . The mean age of females were  $30 \pm 7.5$  (Table 2).

VAS showed reduction in pain from baseline to 21 days although no statistical significance was noted between groups ( $p=0.07$ )(Table 3, Graph 1).

The mean healing scores as per the healing index in the donor site in group A was 3.2 at 7<sup>th</sup> day postoperative and 5.0 at 21 days. In group B the mean healing scores were 2.8 on the 7<sup>th</sup> day which improved to 4.0 at 21 days postoperative with a statistical significance of 0.004 favour of Group A (Table 4, Graph 2, Figure 3 and Figure 4).

### DISCUSSION

The study aimed to evaluate the synergistic efficacy of Aloe vera Chitosan based surgical dressing to Chitosan surgical dressing alone on healing of palatal surgical wounds. It was a parallel arm, triple blinded randomized controlled study wherein 10 subjects per group were selected and received either a combination of Aloe vera Chitosan or Chitosan alone.

Aloe vera and Chitosan were used synergistically because both have very good healing potential along with pain reduction and anti inflammatory property. In addition to this, Chitosan was used as it is highly mucoadhesive (Ways et al., 2018) which helps in the retention of the dressing in the palate. It has also been shown to stabilize the polysaccharides present in Aloe vera which in turn helps to keep its natural biological activity stable (Silva et al., 2013).

The randomization into group A and B were performed by an examiner blinded to the study and a calibrated examiner recorded the clinical parameters. The primary outcome of the study was to assess pain and wound healing. Pain was assessed using Wong Becker Visual analog scale and healing was assessed by Landry et al., healing index at 7<sup>th</sup> day, 14 day and 21<sup>st</sup> day postoperative Selection of palatal donor site as a healing assessment model is based on permitting standard wound creation, and easy access for clinical observation by means of being an open and shallow soft tissue healing model.

The area between distal finish lines of canine and first molar tooth - one of the most suggested donor site was selected for graft harvesting due to its anatomic advantages with regard to the course of the greater palatine artery and also to be able to make a comparison with the results of previous studies evaluating donor site outcomes following

**Table 1: Healing Index**

| Healing Index Score | Clinical Findings   |
|---------------------|---|
| Very poor (1)       | Tissue color: $\geq 50\%$ of gingiva red<br>Response to palpation: Bleeding<br>Granulation tissue: Present<br>Incision margin: Not epithelialized, with loss of epithelium beyond incision margin<br>Suppuration: Present |
| Poor (2)            | Tissue color: $\geq 50\%$ of gingiva red<br>Response to palpation: Bleeding<br>Granulation tissue: Present<br>Incision margin: Not epithelialized, with connective tissue exposed   |
| Good (3)            | Tissue colour: $\geq 25\%$ and $< 50\%$ of gingiva red<br>Response to palpation: No bleeding<br>Granulation tissue: None<br>Incision margin: No connective tissue exposed   |
| Very good (4)       | Tissue colour: $< 25\%$ of gingiva red<br>Response to palpation: No bleeding<br>Granulation tissue: None<br>Incision margin: No connective tissue exposed   |
| Excellent (5)       | Tissue color: All tissues pink<br>Response to palpation: No bleeding<br>Granulation tissue: None<br>Incision margin: No connective tissue exposed   |

**Table 2: Demographic Data**

|       | N  | Mean    | Std. Deviation | Std. Error | Minimum | Maximum |
|-------|----|---------|----------------|------------|---------|---------|
| M     | 15 | 34.0000 | 5.2768         |            | 32.00   | 47.00   |
| F     | 5  | 30.7500 | 7.5240         | 3.32603    | 30.00   | 44.00   |
| Total | 20 | 39.1444 | 6.6682         | 1.44706    | 31.00   | 47.00   |

**Table 3: VAS**

| VAS     | Group A | Group B | P Value |
|---------|---------|---------|---------|
| 7 Days  | 8.0     | 8.5     |         |
| 14 Days | 4.9     | 4.7     | 0.07    |
| 21 Days | 1.6     | 1.4     |         |

**Table 4: Intergroup Comparison of Healing Index Scores (Donor Site)**

| Postoperative day                  | Group A         | Group B         | Significance |
|------------------------------------|-----------------|-----------------|--------------|
| 7 <sup>th</sup> day postoperative  | 3.2 $\pm$ 0.573 | 2.8 $\pm$ 0.675 | 0.273        |
| 14 <sup>th</sup> day postoperative | 4.2 $\pm$ 0.667 | 3.1 $\pm$ 0.771 | 0.089        |
| 21 days postoperative              | 5 $\pm$ 0.1     | 4.0 $\pm$ 0.516 | 0.004        |



FGG (Pizzo *et al.*, 2002; Thoma *et al.*, 2012). All the surgeries were performed by the same periodontist and a standardized template was used to obtain a uniform thickness of the wound. Analgesic (Aceclofenac 100mg) was prescribed post-operatively as a rescue medicine as pain peaks 24 hours postoperatively (Hungund and Thakkar, 2011). The patients were also advised to make a note of how many analgesics were consumed during the week.

All patients consumed analgesics for 3 days as and when needed after surgery. 5 patients continued for 4 days postoperatively after which analgesics were discontinued. Pain was assessed at various intervals at 7<sup>th</sup>, 14<sup>th</sup> and 21<sup>st</sup> day. Wong Becker's scale was used as it is easy to administer and requires no equipment except for the photocopied faces. The absence of smiles and tears in this faces enables the patient to understand the scale better (Kumar and Tripathi, 2014).

A reduction in VAS scores were seen in both groups from 7<sup>th</sup> to 21<sup>st</sup> day postoperative, but was not statistically significant between the groups and at various time intervals. Though studies have shown the analgesic effects of aloe vera and chitosan (Haller, 1990; Okamoto *et al.*, 2002), in this study a statistical significance could not be appreciated. This could be attributed to application of the gel only once in both the groups and washing away of the gels by saliva thereby lowering its analgesic effect.

The patients reported that they had taken analgesics as rescue medication. So the gels did not show any analgesic effect, though anti-inflammatory effect was observed.

Healing index showed a statistical significance of  $p=0.004$  in favour of Group A (Aloe vera Chitosan) between 14<sup>th</sup> to 21<sup>st</sup> days. This is in accordance to various studies where Aloe vera and Chitosan were used individually and showed very good healing along with pain reduction which was contradictory to this study. Various other studies also showed Aloe vera gel to have cell proliferating-promoting activity and also stated that aloe vera gel improved wound healing by increasing blood supply, which increased oxygenation as a result (Reynolds and Dweck, 1999).

Two clinical trials on wound healing in genital herpes was researched and was concluded that Aloe vera showed better healing compared to placebo at the end of 2 weeks (Davis *et al.*, 1994).

The possible mechanism of Aloe vera in wound healing was explained in a systematic review. It was attributed that wound healing was due to Glucoman-

nan and plant growth hormone gibberellins which interacted with growth factor receptors of fibroblast and stimulated its activity and proliferation for the increase of collagen synthesis when applied topically and on oral administration (Hayes, 1999).

T. Reynolds in 1999 evaluated the healing benefits of aloe vera in fresh minor recurrent aphthous ulcer and showed reduction in the ulcer size, erythema, exudation, pain score, wound size and wound healing period (Reynolds and Dweck, 1999). A double blinded, split mouth, randomized clinical trial assessing the healing of sites treated with fresh *Aloe vera* extracts after periodontal flap surgery was conducted. Better healing was observed in test sites in comparison to control sites in the first postoperative week (Reynolds and Dweck, 1999), which is in accordance with our study. So better healing could be contributed by Aloe vera component which would have acted by mechanisms similar to that of the above mentioned studies.

It has been observed in another study that chitosan hydrogel was able to promote cell adhesion and proliferation making it a promising material for wound healing. Excellent pain relief was also conferred by Chitosan when it was applied as a topical agent to open wounds, such as burns, skin abrasions, skin ulcers and skin grafted areas (Okamoto *et al.*, 2002). Similarly Chitosan gel used in this study also could have shown similar effects. Thus, a combination of Chitosan and Aloe vera would have improved wound healing.

An in vitro study proved that addition of aloe vera to chitosan enhanced antimicrobial potential and exhibits spindle-like shape typical of fibroblasts, suggesting good adherence to the surface and enhancement of wound healing (Kim *et al.*, 2002; Ohshima *et al.*, 1987) which would have led to beneficial effects in terms of wound healing in this study.

From the results of the study, Aloe vera - Chitosan combination acted synergistically compared to Chitosan alone in healing of palatal donor sites. No statistical significance was noted when considering pain but a combination of aloe vera and chitosan was statistically significant when considering healing of palatal wounds, suggesting its role as a futuristic dressing material with further longitudinal trials.

### Limitations of the Study

Cytotoxicity and biodegradability tests in this study were not performed although animal and in vitro studies have confirmed the same.

Antimicrobial properties were not assessed. The study did not assess stability, absorption and release

patterns of the components in the gels. Wound healing markers such as Matrix metalloproteinases (MMPs) could have been assessed.

### Future Perspective

Although abundant evidence is available on aloe vera and chitosan, there is still a need to manipulate the physical properties of identified components and systems which are challenging to achieve the ideal objectives of a surgical dressing.

### CONCLUSION

This was a preliminary study done to assess the synergistic effect of aloe vera chitosan to chitosan alone as a surgical dressing in palatal donor sites. It is the first human trial where a combination of both were used in the oral cavity to assess pain and wound healing in the palate following harvesting of free gingival graft. The materials are economical and compatible to the patient. Although statistical significance was noted in aloe vera chitosan group in terms of wound healing further longitudinal studies with detailed characterization is essential to prove its potential as a wound dressing material.

### Funding Support

The authors declare that they have no funding support for this study.

### Conflict of Interest

The authors declare that there is no conflict of interest.

### REFERENCES

- Adil, P. 2016. Development and Evaluation of Chitosan and Aloe Vera Gel Mucilage Interpolymer Complex-Based Mucoadhesive Buccal Films of Tramadol Hydrochloride. *Asian Journal of Pharmaceutics*, 10(1).
- Ahmed, S., Ikram, S. 2015. Chitosan and its derivatives: a review in recent innovations. *International Journal of Pharmaceutical Sciences and Research*, 6(1):14-30.
- Ahmed, S., Ikram, S. 2016. Chitosan Based Scaffolds and Their Applications in Wound Healing. *Achievements in the Life Sciences*, 10(1):27-37.
- Atiba, A., Nishimura, M., Kakinuma, S., Hiraoka, T., Goryo, M., Shimada, Y., Ueno, H., Uzuka, Y. 2011. Aloe vera oral administration accelerates acute radiation-delayed wound healing by stimulating transforming growth factor- $\beta$  and fibroblast growth factor production. *The American Journal of Surgery*, 201(6):809-818.
- Chawla, K., Lamba, A. K., Tandon, S., Faraz, F., Gaba, V. 2016. Effect of low-level laser therapy on wound healing after depigmentation procedure: A clinical study. *Journal of Indian Society of Periodontology*, 20(2):184.
- Chithra, P., Sajithlal, G. B., Chandrakasan, G. 1998. Influence of aloe vera on the healing of dermal wounds in diabetic rats. *Journal of Ethnopharmacology*, 59(3):195-201.
- Davis, R. H., Donato, J. J., Hartman, G. M., Haas, R. C. 1994. Anti-inflammatory and wound healing activity of a growth substance in Aloe vera. *Journal of the American Podiatric Medical Association*, 84(2):77-81.
- Faleiro, C. C., Elias, S. T., Cavalcanti, L. C., Cavalcanti, A. S. 2009. Aloe vera, aloe vera leaf extract in experimental wound healing in rat skin, in a placebo-controlled trial 6. *CEP*, 29102:770.
- Haller, J. S. 1990. A drug for all seasons. Medical and pharmacological history of aloe. *Bulletin of the New York Academy of Medicine*, 66(6):647-659.
- Hayes, S. M. 1999. Lichen planus-report of successful treatment with aloe vera. *General Dentistry*, 47(3):268-272.
- Hungund, S., Thakkar, R. 2011. Effect of pretreatment with ketorolac tromethamine on operative pain during periodontal surgery: A case-control study. *Journal of Indian Society of Periodontology*, 15(1):55-58.
- Jayakumar, R., Prabakaran, M., Kumar, P. T. S., Nair, S. V., Tamura, H. 2011. Biomaterials based on chitin and chitosan in wound dressing applications. *Biotechnology Advances*, 29(3):322-337.
- Kathariya, R., Jain, H., Jadhav, T. 2015. To Pack or Not to Pack: The Current Status of Periodontal Dressings. *Journal of Applied Biomaterials and Functional Materials*, 13(2):73-86.
- Kim, M.-S., Sung, M.-J., Seo, S.-B., Yoo, S.-J., Lim, W.-K., Kim, H.-M. 2002. Water-soluble chitosan inhibits the production of pro-inflammatory cytokine in human astrocytoma cells activated by amyloid  $\beta$  peptide and interleukin-1 $\beta$ . *Neuroscience Letters*, 321(1-2):105-109.
- Kmieć, M., Pighinelli, L., Tedesco, M. F., Silva, M. M., Reis, V. 2017. Chitosan-Properties and Applications in Dentistry. *Advances in Tissue Engineering and Regenerative Medicine*, 2(4):00035.
- Kumar, P., Tripathi, L. 2014. Challenges in pain assessment: Pain intensity scales. *Indian Journal of Pain*, 28(2):61.
- Landry, R. G., Turnbull, R. S., Howley, T. 1988. Effectiveness of benzydamine HCl in the treatment

- of periodontal post-surgical patients. *Res Clin Forums*, 10:105–118.
- Lingamaneni, S., Mandadi, L. R., Pathakota, K. R. 2019. Assessment of healing following low-level laser irradiation after gingivectomy operations using a novel soft tissue healing index: A randomized, double-blind, split-mouth clinical pilot study. *Journal of Indian Society of Periodontology*, 23(1):53–57.
- Ohshima, Y., Nishino, K., Yonekura, Y., Kishimoto, S., Wakabayashi, S. 1987. Clinical application of chitin non-woven fabric as wound dressing. *European Journal of Plastic Surgery*, 10(2):66–69.
- Okamoto, Y., Kawakami, K., Miyatake, K., Morimoto, M., Shigemasa, Y., Minami, S. 2002. Analgesic effects of chitin and chitosan. *Carbohydrate Polymers*, 49(3):249–252.
- Oliveira, S., Soares, M., Rocha, P. D. S. 2010. Use of collagen and Aloe vera in ischemic wound treatment: study case. *Revista da Escola de Enfermagem da USP*, 44:346–351.
- Oryan, A., Mohammadipour, A., Moshiri, A., Tabandeh, M. R. 2016. Topical Application of Aloe vera Accelerated Wound Healing, Modeling, and Remodeling: An Experimental Study. *Annals of Plastic Surgery*, 77(1):37–46.
- Patel, P. V., Kumar, S., Vidya, G. D., Patel, A., Holmes, J. C., Kumar, V. 2012. Cytological Assessment of Healing Palatal Donor Site Wounds and Grafted Gingival Wounds after Application of Ozonated Oil: An Eighteen-Month Randomized Controlled Clinical Trial. *Acta Cytologica*, 56(3):277–284.
- Pizzo, M. D., Modica, F., Bethaz, N., Priotto, P., Romagnoli, R. 2002. The connective tissue graft: a comparative clinical evaluation of wound healing at the palatal donor site. *Journal of Clinical Periodontology*, 29(9):848–854.
- Reynolds, T., Dweck, A. C. 1999. Aloe vera leaf gel: a review update. *Journal of Ethnopharmacology*, 68(1-3):3–37.
- Silva, S. S., Caridade, S. G., Mano, J. F., Reis, R. L. 2013. Effect of crosslinking in chitosan/aloe vera-based membranes for biomedical applications. *Carbohydrate Polymers*, 98(1):581–588.
- Song, J.-E., Um, Y.-J., Kim, C.-S., Choi, S.-H., Cho, K.-S., Kim, C.-K., Chai, J.-K., Jung, U.-W. 2008. Thickness of Posterior Palatal Masticatory Mucosa: The Use of Computerized Tomography. *Journal of Periodontology*, 79(3):406–412.
- Sullivan, H. C., Atkins, J. H. 1968. Free autogenous gingival grafts. I. Principles of successful grafting. *Periodontics*, 6(3):121–129.
- Tarameshloo, M., Norouzian, M., Zarein-Dolab, S., Dadpay, M., Mohsenifar, J., Gazor, R. 2012. Aloe vera gel and thyroid hormone cream may improve wound healing in Wistar rats. *Anatomy and Cell Biology*, 45(3):170–177.
- Thoma, D. S., Sancho-Puchades, M., Ettlín, D. A., Hämmerle, C. H. F., Jung, R. E. 2012. Impact of a collagen matrix on early healing, aesthetics and patient morbidity in oral mucosal wounds—a randomized study in humans. *Journal of Clinical Periodontology*, 39(2):157–165.
- Ways, T. M. M., Lau, W. M., Khutoryanskiy, V. V. 2018. Chitosan and Its Derivatives for Application in Mucoadhesive Drug Delivery Systems. *Polymers*, 10(3):267.
- Wynn, R. L. 2005. Aloe vera gel: update for dentistry. *General Dentistry*, 53(1):6–9.
- Yaghobee, S., Rouzmeh, N., Aslroosta, H., Mahmoodi, S., Khorsand, A., Kharrazifard, M. J. 2018. Effect of Topical Erythropoietin (EPO) on palatal wound healing subsequent to Free Gingival Grafting (FGG). *Brazilian Oral Research*, 32:e55.