



INTERNATIONAL JOURNAL OF RESEARCH IN PHARMACEUTICAL SCIENCES

Published by JK Welfare & Pharmascope Foundation

Journal Home Page: <https://ijrps.com>

Tuberculosis in Skin – Be Suspicious?

Sharanya K*, Narasimhalu CRV and Muhilan J

Department of Dermatology, Venereology and Leprosy, Saveetha Medical College, Thandalam - 600128, Chennai, Tamil Nadu, India

Article History:

Received on: 05.03.2018
Revised on: 12.08.2018
Accepted on: 14.08.2018

Keywords:

Tuberculosis verrucosacutis,
Cutaneous tuberculosis,
Asymptomatic warty plaques,
Butcher's warts,
Verrucous tuberculosis

ABSTRACT

We report a case of Tuberculosis verrucosa cutis in an 18 years old female patient with absence of any primary tuberculosis focus. She had a substantial positive Mantoux test and normal chest radiograph. Tuberculosis is a common disease worldwide and is reported to be the second most common infectious cause of death after HIV. The causative organism is Mycobacterium tuberculosis (MTB), and it is capable of infecting virtually every organ of the body including the skin. Tuberculosis verrucosacutis is an exogenous infection occurring in the previously sensitized patient with a moderate to the high immune response by direct inoculation of the organism. The diagnosis in our patient was confirmed by history, clinical examination and histopathology. Lesion of tuberculosis verrucosacutis improved after anti-tuberculous treatment. Therefore, it is imperative on the biomedicine scientists to acknowledge the rampant high incidence of cutaneous TB for early recognition and treatment.



* Corresponding Author

Name: Dr. Sharanya K
Email: dr.sharanya26@gmail.com

ISSN: 0975-7538

DOI: <https://doi.org/10.26452/ijrps.v9i4.1660>

Production and Hosted by

IJRPS | <https://ijrps.com>
© 2018 | All rights reserved.

INTRODUCTION

Tuberculosis is a significant public health concern due to its high prevalence with higher morbidity and mortality. It is a mycobacterial infection that occurs commonly due to infection with *Mycobacterium tuberculosis* or *Mycobacterium bovis*, reflecting the immunity of an individual (Sehgal VN, Wagh SA 1990).

Tuberculosis of skin manifests with a broad spectrum of clinical findings depending on the source of infection and the immune status of the host (Niraimadhi S *et al.*, 2015). Tuberculosis verrucosacutis also known as warty tuberculosis, anatomist wart is an indolent warty plaque like a form of paucibacillary cutaneous tuberculosis resulting from inoculation of *Mycobacterium tuberculosis*

into the skin of a previously infected patient, with moderate to high degree of immunity (Halim MS *et al.*, 2013). Clinically it has a typical appearance: Starting as a small, asymptomatic warty papule which progresses over time to become a verrucous plaque with an irregular serpiginous outline and finger-like projection (Prasad PVS, Rao LL 1994).

CASE REPORT

An 18-year-old female, student by occupation presented with asymptomatic raised skin lesion over the right ankle region for the past 1 year. On examination, there was a single well-defined hyper-pigmented indurated verrucous plaque of size 2 x 3 cm over the posterior aspect of the right ankle. Her systemic examination was unremarkable. Her blood investigation showed raised erythrocyte sedimentation rate of 40mm/hr. Other investigations like blood sugar, renal and liver function tests were normal. Her Chest X-Ray and Computed Tomography of the chest did not show any signs of pulmonary tuberculosis. Her Mantoux test showed 20mm reaction in 48h. Biopsy taken from the lesion showed hyperplastic stratified squamous epithelium with few clusters of epithelioid histiocytes and Langhan's with the foreign body type of giant cell in the sub-epidermal region.

Based on the history, clinical picture and clinic-pathology reports, diagnosis of tuberculosis verrucosa cutis were made.

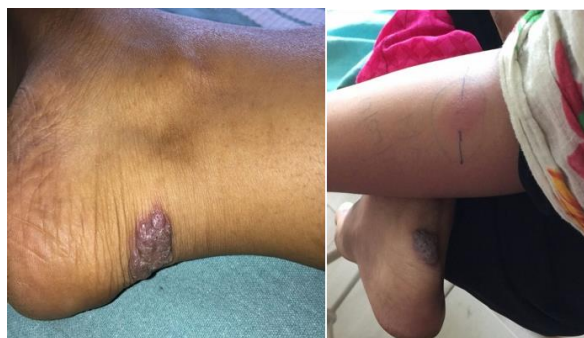

Figure 1: Well-defined hyper-pigmented indurated verrucous plaque over the posterior aspect of the right ankle.

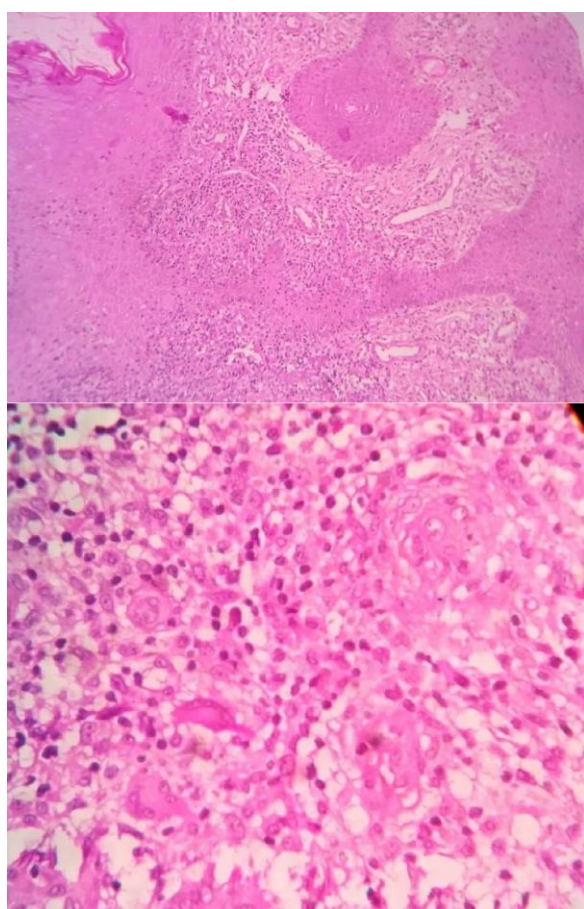


Figure 2: Epithelioid-histiocytes and Langerhans's with the foreign body type of giant cell.

DISCUSSION

Tuberculosis verrucosacutis is also known as warty tuberculosis, prosector's warts, butcher's wart, anatomist's wart and verrucous tuberculosis (Kumar B, Muralidhar S 1999). Tuberculosis verrucosacutis results from direct inoculation of the bacilli into the skin of previously infected patients with intact immunity.

In 2016, it was estimated that around 10.4 million were affected with tuberculosis. According to the

WHO TB statistics of 2016, in India, it is estimated to be around 2.79 million reported TB cases and the incidence of extra-pulmonary TB is found to be around 15-20% (Global TB Report 2017). The incidence of TBVC varies but is seen frequently in Asia. In India, TBVC is probably the third most common form after lupus vulgaris and scrofuloderma (Pomeranz MK *et al.*, 1996).

Lesions usually occur on areas exposed to trauma such as fingers and lower extremities. Physicians, pathologist and medical laboratory technicians are usually affected due to the handling of pathologic material. Indian reports indicate that Tuberculosis verrucosacutis occurred most commonly on the lower extremities and buttocks where hands were involved elsewhere (Gruber PC *et al.*, 2002). TBVC commonly affects children who contract the bacteria by walking barefoot and sitting on the ground contaminated with tuberculous sputum (Aliadaođlu C *et al.*, 2009).

The lesions are typically asymptomatic and start as a small papule or papulopustular, further progressing to warty or hyperkeratotic plaques. These plaques are firm with a verrucous surface and often have fissures with pus discharge. Regional nodes are not usually enlarged¹⁰. Marked pseudoepitheliomatous hyperplasia of the epidermis characterizes the histopathological features with hyperkeratosis and dense inflammatory cell infiltrate consisting of neutrophils, lymphocytes and mid-dermal epithelioid cell granuloma (Yates VM 2010; Foo CC and Tan HH 2005). Diagnosis is usually confirmed by typical clinical appearance, histopathological pattern and positive response to anti-tubercular treatment. The differential diagnosis includes blastomycosis, botryomycosis, and fixed sporotrichosis, a lesion caused by non-tubercular mycobacterium, lupus vulgaris (Chettikan Ramamurthy 2013) and tertiary syphilis. The preferred treatment is anti-tuberculous drugs (Al-Grawi *et al.*, 2018).

CONCLUSION

This case is reported because of its unique appearance and the indolent nature of the disease.

REFERENCES

- "Global TB Report 2017", WHO 2017.
- Al-Grawi, E.D.C., and G.R.L. Al-Awsi. 2018. "Expression of CDKN2A (P16/Ink4a) among Colorectal Cancer Patients: A Cohort Study." *Journal of Pharmaceutical Sciences and Research* 10 (5).
- Aliadaođlu C, Atasoy M, GüleçAY, Özdemir Đ, Erdem T, Engin RY. Tuberculosis verrucosa cutis. *Eur J Gen Med* 2009; 6: 268-73.

- Chettikan Ramamurthy, Venkata Narasimhalu et al. Apple Jelly Nodule. *Infectious Diseases in Clinical Practice* 2013; 21(1): 183-84.
- Foo CC1, Tan HH. A case of tuberculosis verrucosa cutis--undiagnosed for 44 years and resulting in fixed-flexion deformity of the arm. *Clin Exp Dermatol* 2005; 30(2): 149-51.
- Gruber PC, Whittam LR, du Viver A. Tuberculosis verrucosa cutis on the sole. *Clin Exp Dermatol* 2002; 27: 188-91.
- Halim MS, Ahmed SQ, Junaid M, Bashir MR. Tuberculosis verrucosa cutis in a patient with keloid over ear lobule. *BMJ Case Rep* 2013; 2013: bcr2013010294.
- Kumar B, Muralidhar S. Cutaneous tuberculosis: A twenty-year prospective study. *Int J Tuberc Lung Dis* 1999; 3: 494-500.
- Niraimadhi S, Anand V. Tuberculosis Verrucosa Cutis. *Journal of Current Trends in Clinical Medicine & Laboratory Biochemistry* 2015; 3(2): 42-45.
- Pomeranz MK, Orbuch P, Shupack J, Brand R. Mycobacteria and skin. In: Rom WM, Garay S, editors. *Tuberculosis*. Vol. 51.1sted. London: Little Brown Co.;1996. p. 657-74.
- Prasad PVS, Rao LL. Lupus vulgaris with tuberculosis verrucosa cutis. 1994; 60(6): 347-348.
- Sehgal VN, Wagh SA. Cutaneous tuberculosis- Current concepts. *Int J Dermatol* 1990; 29: 237-52.
- Yates VM. Mycobacterial Infections. In: Burns T, Breathnach S, Cox N, Griffiths C, editors. *Rook's Textbook of Dermatology*. 8th ed. UK: Wiley-Blackwell Publications Ltd; 2010.31.1-41.