



Recognition of glaucoma using otsu segmentation method

Naga Kiran D*, Kanchana V

Department of Computer Science, Amrita School of Arts and Sciences, Amrita Vishwa Vidyapeetham Mysuru Campus, India



Article History:

Received on: 13.03.2019

Revised on: 22.06.2019

Accepted on: 26.06.2019

Keywords:

glaucoma,
OC,
OD,
otsumethod,
NRR,
CDR,
RDR,
ISNT,
SVM classifier

ABSTRACT

Glaucoma is an eye disease once it occurs, it cannot be cured. Be that as it may, in the event that it is starting stage doesn't take the therapeutic treatment it prompts the lasting visual impairment. Most of the literature surveys explain various techniques which are used with the help of the optic cup and optic disc to detect glaucoma. It tends to be successfully identified through the best possible segmentation of optic cup and optic disc. In this paper, we proposed about, NRR [neuro retinal rim] OTSU segmentation based technique. The disease will be confirmed by calculating the CDR [cup to disk ratio], RDR [rim to disk ratio], ISNT ratio [inferior, superior, nasal, temporal] and in analysis of glaucoma detection CDR and SVM [support vector machine] play the major role in identifying the glaucoma present or not. Our experimental technique has got the outcome of 94% accuracy.

*Corresponding Author

Name: Naga Kiran D

Phone: 9620875838

Email: kiranharsha570@gmail.com

ISSN: 0975-7538

DOI: <https://doi.org/10.26452/ijrps.v10i3.1407>

Production and Hosted by

IJRPS | <https://ijrps.com>

© 2019 | All rights reserved.

INTRODUCTION

Glaucoma is a second leading Cause for vision loss which could damage the eyes optic-nerve, ensuing in thrashing of vision and thereby causing permanent blindness. Though there may be no medicine, early diagnosis with sufficient medication and care, it's possible to prevent it.

With the anticipated increase in life expectancy, the predicted quantity of human beings turning into blind from the disorder will rise noticeably inside the near destiny. Despite growing awareness in pub-

lic health and the provision of superior technology in diagnostic tests in developing nations, the practitioners find it difficult to diagnose the affected eye. There are three techniques used by ophthalmologists to detect glaucoma.

- i) Intraocular Pressure assessment
- ii) Abnormal visual field assessment
- iii) Damaged optic nerve head assessment.

The Intraocular pressure (IOP) is the inner pressure of the eye, and it's a major component in evaluating if a patient has a high risk of glaucoma or not. Even some patients' optic nerve may be affected due to various reasons which lead to glaucoma, even when the IOP measurement taken from tonometry is normal. Optical field checking needs a distinct device that is normally present in most of the eye hospitals. It is an individual examination as it accepts that patients fully recognize the checking orders, cooperate and do an entire test. Moreover, the check is normally time-consuming. Thus the facts found might not be reliable. The evaluation of optic nerve damage is advanced to other strategies. Optic nerve(ON) may be measured by way of educated experts or through 3-D imaging techniques, which

includes Ocular Computing Tomography (OCT) and Heidelberg Retinal Tomography (HRT).

The automatic and financial system is especially perfect for the discovery of glaucoma in a high range of viewing programs. The advanced shading fundus picture is a greater price powerful imaging methodology to measure ON damage as compared to HRT and OCT, and it is largely utilized in the latest years to detect various optical illnesses containing glaucoma. An ophthalmologist can analyze Glaucoma by methods for calculating the CDR, i.e., the proportion of the perpendicular height of the OC and OD.

Literature survey

(Sedai *et al.*, 2016) This paper proposed a fully computerized regression which is used to properly segment the optic cup and optic disc. Their method begins with an underlying shape, which is iteratively refreshed by each regressor in the gathering to get the final shape. They have used 50 unhealthy images to evaluate their proposed method, which results in 94% accuracy.

(Joshi *et al.*, 2011) this paper proposed a parameterization approach based on segmented optic disk and cup regions using monocular retinal images. Using the retinal images, the geometric parameter like CDR, are derived. This parameter plays a major role in detecting the progressing of glaucoma. They used structural indication like vessel bends to compute consistent separation of R-bends using multi-stage approach. To assess glaucoma, the proposed method shows effectiveness in both segmentation and subsequent OD parameterization.

(Zilly *et al.*, 2017) this paper proposes a novel approach ensemble learning-based convolutional neural network (CNN) architecture, which is used to detect glaucoma. This work proposes two stages first, a novel entropy sampling method and secondly to develop a learning framework. The results obtained from this learning framework are better compared to other methods.

(Singh *et al.*, 2016) This paper proposes a wavelet function abstraction from the segmented the optic disk and the blood vessels are removed. Different classifiers such as Random Forest, KNN, SVM are used for classifying the affected iris and the normal iris. This work is clinically significant, as the accuracy obtained in this study is efficient compared to other studies.

(Kavitha *et al.*, 2010) in this work, the component analysis and region of interest are used to segment and detect the disc and cup. The proposed method where the comparison of the clinical and calculated CDR is nearly approximate, which has been applied

to nearly three hundred images.

(Hatanaka *et al.*, 2014a) this paper proposes a method which uses the location of blood vessel bends using density gradient. CDR and RDR were calculated; the blood vessel bends helps to increase the cup outline. This method was evaluated for 45 retinal images where 32 non-healthy images were included.

(Mahalakshmi and Karthikeyan, 2014) This method uses Superpixel classifier for glaucoma screening. It also uses multimodalities including simple linear iterative clustering (SLIC) algorithm, K-Means clustering and Gabor filter of the color fundus camera image to obtain accurate boundary delineation.

(Youssif *et al.*, 2008) This paper proposed about adaptive histogram equalization method. It is used to compare the healthy and non-healthy eyes. 2-Dimension receptacles way matched sieve used for optic disc recognition. Corresponding the possible directional shape tends to optic disc direction process. Act and productivity in the proposed system Enhanced by blood vessel separation It Tested 80 out of 81 glaucoma images. and by using illumination equations method.

(Narasimhan and Vijayarekha, 2011) This paper proposed about Hough transformation method. This helps to extract the MRF and GLCM. It uses k means algorithm to segment the optic nerve head (ONH). Here rim disk ratio and cup disc ratio within ONH and ODC calculated and also used support vector machine classification. Using the above methods, glaucoma will be recognized. Finally, it gets 86% accuracy.

(Belghith *et al.*, 2013) This paper proposed about, initially it applies VEM algorithm to calculate the CDR. It used the 3d technique HRT [Heidelberg retinal tomography] and OCT to inside glaucomatic prognosis identification. This method is comfortable for ophthalmologist easily identifying disease.

(Hatanaka *et al.*, 2014b) This paper proposed retinal nerve fiber layer defect. Using the OCT technology, it can identify the nerves, blood vessels, range of disease that spread in the eye. Segmented into k means algorithm. And explain about OCT 3d technique, analysis on RNFL. It has a drawback that is less than 77% sensitivity and less than 95% accuracy.

(McIntyre *et al.*, 2004) This paper proposed about series of experiments testing the feasibility of using image-processing strategies for the feature extraction level in the implementation of a simple optic nerve picture classifier. Such a scheme completely eliminates the want for manually identifying the rim

of the optic nerve.

(Sheeba *et al.*, 2014) in This paper explain about different levels of glaucoma, namely mild, normal, severe. By the using of neural network identify the glaucoma stage, and simplify the operation find the parameter results. Here ISNT, NFLT and Central corneal Depth methods are used. Feed forward network used to improve the typical neural models. They described mat lab software, which enables the detection of glaucoma in the initial stage.

(Yun and Koh, 2013) This paper proposed about, digital fundus picture. Using the k means algorithm to segment the retinal images, find out the centroid point. Using 5 classifications they are, the PNN, decision tree a, SVM, Fuzzy classification. explained on HRT, OCT technique it identifies the glaucoma is infected or not. Each classifier are tested, and they get different results. Finally, it gets the accuracy of 92%, sensitivity of 85% and specificity of 99%.

(Akshay and Apoorva, 2017) This paper explain about automatically get the parameter disc ratios. Using the facet discovery technique, variation AL discovery technique, and it also used the NMF camera, to find the cup issues. Threshold level technique are used the value of threshold zero or one and finally calculated the CDR values.

MATERIALS AND METHODS

The below Figure 1 diagram depicts the proposed method for glaucoma detection. The proposed methodology is evaluated using the database *DIARETDB1*, where 60 images are used for the study.

This paper uses RGB color images as input. Each block in the diagram are explained separately below. Once the image is preprocessed like removing the noise, converting to grayscale, the ROI is found that will help to identify glaucoma. That is shown in Figure 2.

Image acquisition and processing

A. Color Channel Separation

In the proposed system, red, blue, green 3 channels are extracted, in that red channel nerves does not properly visible because it has low sensitivity, green channel nerves are visible but not better because it has average sensitivity. Blue channels nerves are visible properly, and it shows the nerves correctly because it has high sensitivity using OTSU method easily segmented the OD. These RGB 3 channels are applied in gray level images and extracted, as shown in Figure 3.

A. ROI extraction

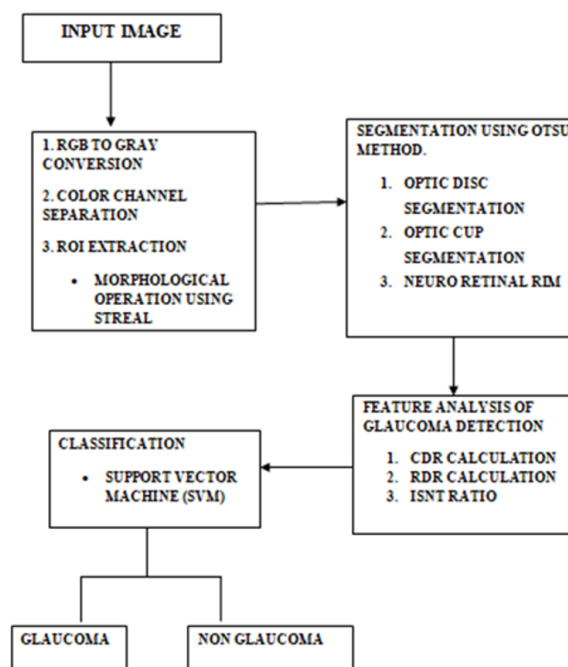


Figure 1: Block diagram for glaucoma detection

In order to extract the Region around OD, the mid-point of OD is first calculated. A frame of measurement $R \times \text{column}$ is formed, as shown in Figure 4. Here R is the radius of OD (Estimated). At that moment passing the frame through the Picture spatially, for all rows and columns, finding the maxima, we find the Row of OD center. Another frame of measurements $R \times R$ is shaped, as shown in Figure 4. This frame is distributed Through discovered Row to every column, and the maxima are Identified. Hence the synchronizes of the center of OC is found.

Morphological operation using strel

For the ROI selected position morphological functions like dilation, erosion is applied to identify the cup disc. Using strel function background are removed and smoothing the image. The ROI image is then converted into the binary image, as shown in Figure 5. Using this binary image, the optic disc is extracted using OTSU threshold method, which eliminates the blood vessels. The dilation of A and erosion of B is defined as $A-B = \{ | S|B - A \}$

The background pixels will be assigned value zero, which is black in color and for foreground pixels, which is white in color, is assigned the value one. Using these pixel values, the edge of the optic disc is extracted.

Segmentation using otsu method

OTSU segmentation method eliminates the background image and extracts only foreground image. It is an unsupervised and non-parametric technique. In the existing system, only green channel

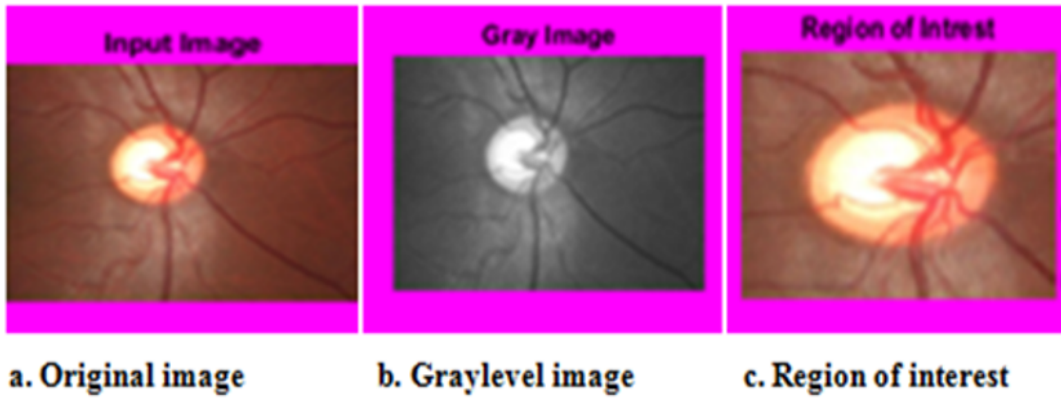


Figure 2: Selection of ROI Region

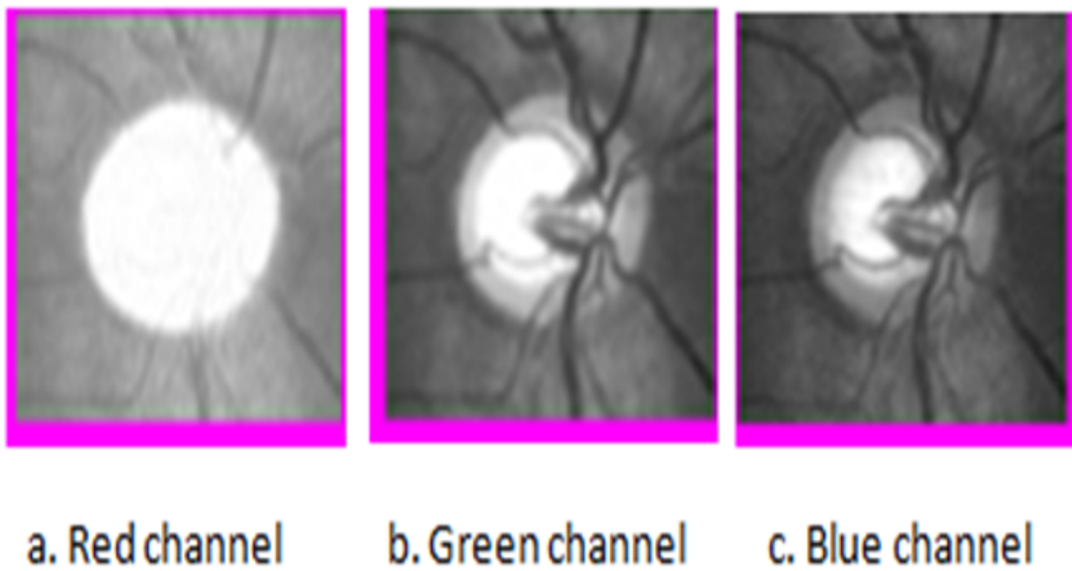


Figure 3: RGB Channels

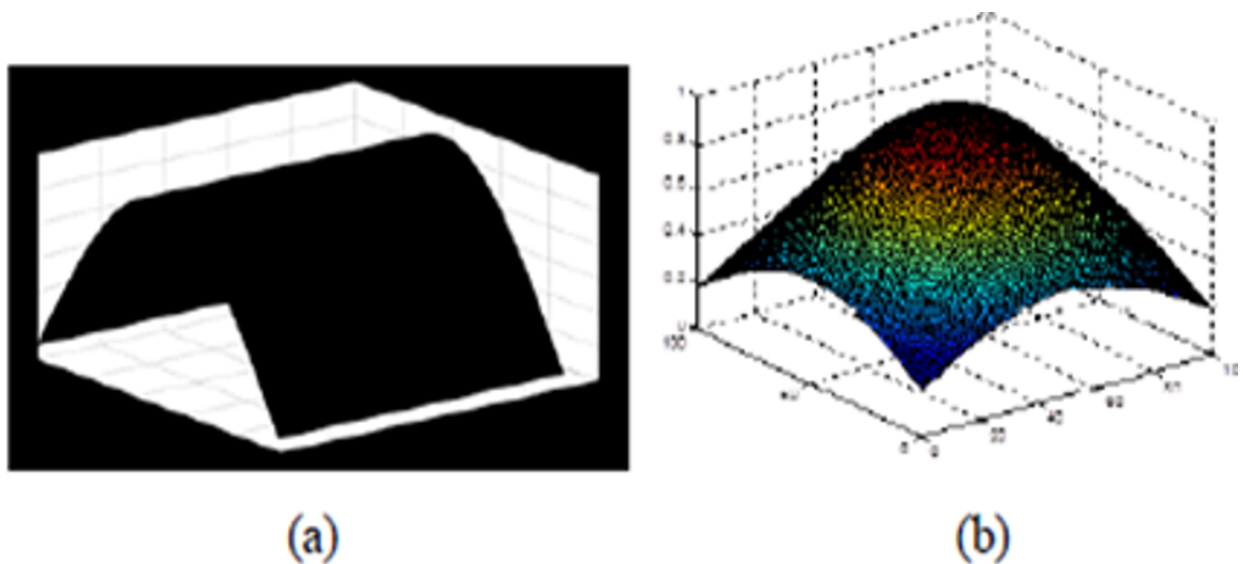


Figure 4: a) Frame 1 for optic disc Detection, (b) Frame 2 for optic disc detection




Figure 5: Image outcome after Morphological function.

are extracted by using OTSU Thresholding method, which chooses the best reliable OTSU- threshold by a discriminant standard that looks for maximizing the ability to separate the modules (That is, The substances of hobby and the heritage) in the greyscale photos. This technique considers two modules X0 (contextual) and X1 (items) start from an edge P. The magnificence containing all the images of a grey degree lower than edge value P, whereas the magnificence connected to the heritage includes all the images, with grey stages more than p. In this manner, the exercises have the ensuing dissipating.

$X_0 = \{ 0, 1, 2, 3, \dots, P \}$ and $X_1 = \{ P+1, P+2, P+3, \dots, M-1 \}$

In proposed system, RGB 3 channels are extracted and identifying the more specific regions using the binarization technique. Formula for weight sum variance calculation using OTSU method $\sigma_\omega^2(t) = \omega_0(t)\sigma_0^2(t) + \omega_1(t)\sigma_1^2(t)$

Weight = w_0, w_1 Threshold = t

Variance = and $P =$ probability

$I =$ number of rows, $J =$ number of columns

To find class probability

$$\omega_0(t) = \sum_{i=0}^{t-1} p(i)$$

$$\omega_1(t) = \sum_{i=t}^{L-1} p(i)$$

When the object region is smaller than the background region, the histogram couldn't exhibit bimodality. If the object size is smaller, the mean value difference and background density will decrease; hence, the 2-D OTSU method is used to overcome the above problems, which will increase the performance. Using this technique, binarization result enhanced for noise corrupted images. The formula for weight sum, variance calculation using 2-D OTSU method

$$\omega_0(t) = \sum_{i=0}^{8-1} \sum_{j=0}^{t-1} P_{i,j}$$

$$\omega_1(t) = \sum_{i=s}^{L-1} \sum_{j=t}^{L-1} P_{i,j}$$

The above formula is also used for calculating the gray level neighbourhood values. Using 2-D OTSU

method is easy and convenient to segment the images.

RESULTS AND DISCUSSION

Optic disc segmentation

The optic disc is known as a blind spot. It is formed in a circle shape. It is a beginning point of the main blood veins which provide the retina. This optic disc is situated of 3-4mm left side of the FOVEA Optic nerve which can be a threat. OTSU threshold technique is used to segment the optic disc shown in Figure 6. After the segmentation, inside the retinal layer are not found in the area, and segmentation of the vessel system can also sense the optic disc. To process the OD, there are 2 methods, namely identification of the centroid point and identification of the disc region.



Figure 6: Optic disc segmentation

Optic cup segmentation

Optic cup is the central region of the OD. The optic cup segmentation is difficult than optic disc segmentation. To segment, OC uses the binarization method because it resolves the image to black and white

image, as shown in Figure 7. To find the boundary of the cup from the color picture, there are two optical signs they are i) twist in small veins. ii) Change in dimensions of dim neighboring pallor edge. In the proposed system distance of boundary is calculated and overcome the stimulus of blood veins.



Figure 7: Optic cup segmentation

Neuro retinal rim

The tissue among optic disc and optic cup edge is called as NRR. Rim disc ratio (RDR) is represented like the relation of edge depth to drift separate over. Glaucoma prompts the absence of NRR and reduction in Neuroretinal Rim region. Neuroretinal edge is an area set concerning the edges of OD and OC. It is protected from using deducting OD from OC. Neuroretinal Rim is showed in Figure 8.



Figure 8: NRR [Neuroretinal Rim]

Feature analysis of glaucoma detection

Cup to Disk Ratio

It is a first parameter which is used to identify glaucoma. The cup region rises step by step in glaucoma

that tends to continue vision damage. By adding all white pixels, cup area-disc area can be calculated to classify glaucoma. When CDR value greater than 0.3, it is a glaucomatic or else it is non-glaucomatic. Cup disc ratio will be increased due to an overpressure in the eyes and reduced blood flow to the optic nerve.

To calculate the CDR using formula, i.e.,

$$CDR = \text{optic cup area} / \text{optic disc area}$$

Rim to Disk Ratio

RDR plays the second major role in detecting glaucoma after CDR. Using the rim disk ratio, the value of the cup disk ratio will increase, which helps in identifying the healthy rim tissues. So NRR tissue plays an essential function in detecting glaucoma. Rim to disc ratio will be calculated using a set of rules. That is defined as follows.

$$RDR = \text{Superior region-nasal rim region} / \text{Disc Region}$$

Optic cup increases the size and acquires the optic disc area, that particular area is the blind spot.

Cisnt Ratio

ISNT stands for inferior, superior, nasal, temporal. We apply ISNT rule on the image, convert the gray image to black and white image, masking on the converted images, and finding the centroid point using ISNT rule. Evaluating the region of veins in ISNT quadrant, the maximum veins are thought within the progressive and superior area of the OD (Figure 10). Generally, the veins convert around 29% of the OD. A move inside the ONH causes an initial stage within the area included for veins within the nasal spot and decreases the area safeguarded, Inferior and superior region subsequently the total of veins region of temporal and nasal area are used to calculate the area. Firstly binary images are used with the blood veins and crop to the 250×250 length image to shield minor position which have the OD center. The mask of 250×250 is apply to remove 1 of the quadrant. The mask are turned around with the help of 90 degree on every occasion. Binary blood veins images are used to get an area which is shielded in the manner of blood veins of each and every quadrants. In this system, we apply the mask to the image accurately. We take the ISNT region and find the ratio. Figure 9 indicates, the masking to the image and Figure 10, indicates the result outcomes through the masking. We should calculate the CDR, RDR, ISNT To make the support vector machine classifier to discovering glaucoma.

Algorithm steps

Step1: Image conversion

1. Read the image Color the image will be displayed in axis one.




Figure 9: ISNT Mask




Figure 10: ISNT mask multiplied with NRR

2. It will be converted RGB to Gray color.

$G1 = \text{RGB2Gray}(I)$;

Step2: ROI (region of interest)

1. Select the particular region of the image.
2. Prepare a strel with a disc size 10.
3. Apply the Geometric image function
Image size allocation (length stats)

Step3: segmentation

1. Initially obtained 3 color channels of the image. Otsu Segmentation method applied for a binary image obtained with an image index value and texture.

Step 4: Binary image conversion.

Step5: Applied ISNT Rule

1. Image it will convert black to white

2. Preparing the ISNT mask

3. Find the centroid of the NRR image

Step 6: SVM Classification

Identified glaucomatic or non-glaucoma

Simulation results and svm

SVM is used to classify glaucomatic or non-glaucomatic eye easily, and it is supervised learning, which provides a good result, as shown in Figure 11. We segmented the optic disc, optic cup and Neuroretinal rim by using OTSU method and take the CDR, RDR, ISNT factors analyze the glaucoma detection. We take 50 trained images to test, in that 25 are glaucomatic and remaining 25 images are non-glaucomatic. Then out of 25 non healthy eye images, 11 images are tested, and another healthy 11 images are tested. Finally, 22 samples are tested successful 94% accuracy, and 96% sensitivity. result is shown in Table 1.

Table 2 shows the results of both CDR and RDR calculated via anticipated, and the images are classi-

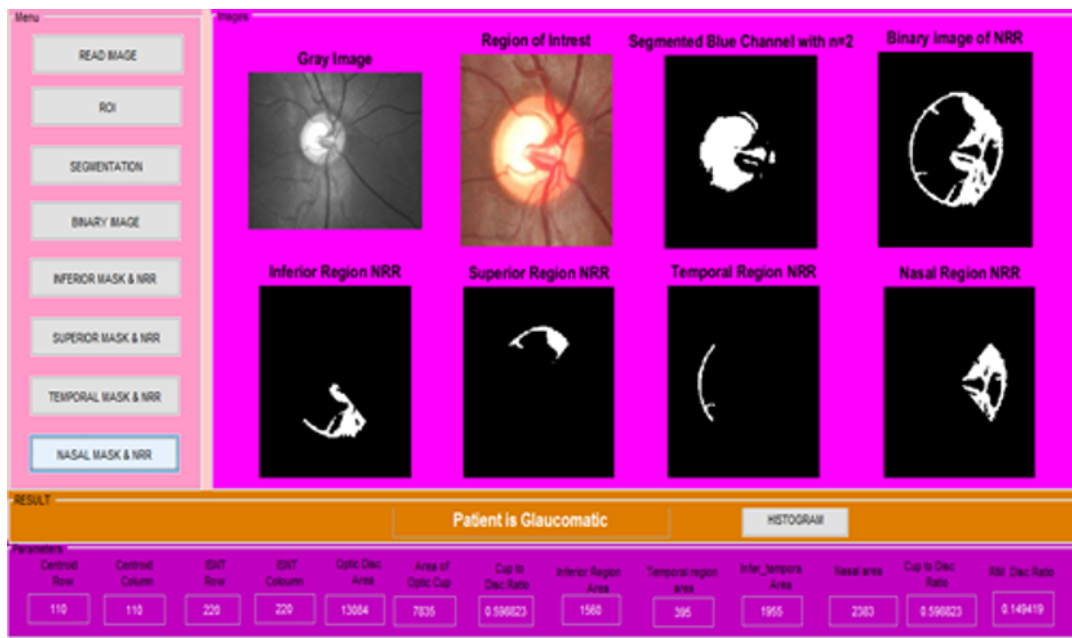


Figure 11: Result of tested images using OTSU method

Table 1: Accuracy result of SVM

Classification	Trained images	Test Sample	Accuracy	Sensitivity
SVM	50	22	94%	96%

Table 2: Glaucoma Detection with Sample Results

Sample	CDR	RDR	Experimental result
1	0.80	0.28	Glaucoma
2	0.50	0.46	Glaucoma
3	0.60	0.49	Glaucoma
4	0.54	0.36	Glaucoma
5	0.49	0.18	Glaucoma
6	0.33	0.25	Glaucoma
7	0.37	0.46	Glaucoma
8	0.28	0.61	Non-Glaucoma
9	0.41	0.47	Glaucoma
10	0.39	0.42	Glaucoma
11	0.16	0.54	Non-Glaucoma
12	0.20	0.59	Non-Glaucoma
13	0.18	0.64	Non-Glaucoma
14	0.14	0.58	Non-Glaucoma
15	0.25	0.68	Non-Glaucoma
16	0.31	0.35	Glaucoma
17	0.39	0.63	Glaucoma
18	0.13	0.31	Non-Glaucoma
19	0.18	0.50	Non-Glaucoma
20	0.32	0.49	Glaucoma
21	0.26	0.51	Non-Glaucoma
22	0.15	0.45	Non-Glaucoma

fied into glaucomatic or non-glaucomatic using SVM classifier.

CONCLUSION

In this paper, an OTSU segmentation method is used, which is called as Nobuyuki Otsu. Using different parameters, glaucoma will be identified by using improved RGB channels, CDR, RDR, NRR, ISNT. CDR and RDR are the 2 parameters used to calculate the ratio of OC and OD. ISNT is used to masking which is applied to find the central point. SVM classifies the images into glaucomatic and non-glaucomatic. If the CDR ratio is greater than 0.3, then it is classified as glaucomatic eye. If it is less than 0.3, then it is non-glaucomatic. We have applied morphological strel function on the ROI extracted pictures. Using all the above methods and by analyzing the test results, the accuracy are increased to 94%.

REFERENCES

- Akshay, S., Apoorva, P. 2017. *Segmentation and classification of FMM compressed retinal images using watershed and canny segmentation and support vector machine.*
- Belghith, A., Balasubramanian, M., Bowd, C., Weinreb, R. N., Zangwill, L. M. 2013. *Glaucoma progression detection using variational expectation maximization algorithm.*
- Hatanaka, Y., Nagahata, Y., Muramatsu, C., Okumura, S., Ogohara, K., Sawada, A., Fujita, H. 2014a. Improved automated optic cup segmentation based on detection of blood vessel bends in retinal fundus images. *Medicine and Biology Society, EMBC, 2014.*
- Hatanaka, Y., Nagahata, Y., Muramatsu, C., Okumura, S., Ogohara, K., Sawada, A., Fujita, H. 2014b. Improved automated optic cup segmentation based on detection of blood vessel bends in retinal fundus images. *Medicine and Biology Society, 126(129):10–1109.*
- Joshi, G. D., Sivaswamy, J., Krishnadas, S. R. 2011. Optic Disk and Cup Segmentation From Monocular Color Retinal Images for Glaucoma Assessment. *IEEE Transactions on Medical Imaging, 30(6):1192–1205.*
- Kavitha, S., Karthikeyan, S., Duraiswamy, K. 2010. *Early detection of glaucoma in retinal images using a cup to disc ratio.*
- Mahalakshmi, V., Karthikeyan, S. 2014. Clustering Based Optic Disc and Optic Cup Segmentation for Glaucoma Detection. *International Journal of Innovative Research in Computer and Communication Engineering, 2(4):3756–3761.*
- McIntyre, A. R., Heywood, M. I., Artes, P. H., Abidi, S. S. R. 2004. Toward glaucoma classification with moment methods. pages 265–272.
- Narasimhan, K., Vijayarekha, K. 2011. An efficient automated system for glaucoma detection using fundus image. *Journal of Theoretical and Applied Information Technology, 33(1):104–110.*
- Sedai, S., Roy, P. K., Mahapatra, D., Garnavi, R. 2016. Segmentation of optic disc and optic cup in retinal fundus images using shape regression. *Medicine and Biology Society, (EMBC),:3260–3264.*
- Sheeba, O., George, J., Rajin, P. K., Thomas, N., George, S. 2014. Glaucoma detection using artificial neural network. *International Journal of Engineering and Technology, 6(2):158.*
- Singh, A., Dutta, M. K., ParthaSarathi, M., Uher, V., Burget, R. 2016. *Image processing based automatic diagnosis of glaucoma using wavelet features of the segmented optic disc from fundus image, volume 124.*
- Youssif, A. A. H. A. R., Ghalwash, A. Z., Ghoneim, A. A. S. A. R. 2008. Optic Disc Detection From Normalized Digital Fundus Images by Means of a Vessels' Direction Matched Filter. *IEEE Transactions on Medical Imaging, 27(1):11–18.*
- Yun, W. L., Koh, J. E. W. 2013. Automated Detection of Glaucoma Using Fuzzy K -Means Algorithm and Fuzzy Sugeno Classifier. *Journal of Medical Imaging and Health Informatics, 3(4):592–597.*
- Zilly, J., Buhmann, J. M., Mahapatra, D. 2017. Glaucoma detection using entropy sampling and ensemble learning for automatic optic cup and disc segmentation. *Computerized Medical Imaging and Graphics.*