



Assessment of growth status by correlating the maturation stages of middle phalanx of the third finger and calcification stages of mandibular third molar in an institutional set up

Reshma Mohan, Ravindra Kumar Jain*, Nivethigaa Balakrishnan

Department of Orthodontics and Dentofacial Orthopaedics, Saveetha Dental College and Hospital, Saveetha Institute of Medical and Technical Sciences, Saveetha University, Chennai, Tamil Nadu, India

Article History:

Received on: 11 Nov 2020
Revised on: 07 Dec 2020
Accepted on: 11 Dec 2020

Keywords:

Growth Spurt,
Modified MP3 Method,
Demirjian Index,
Mandibular Third Molar

ABSTRACT

The present study aims to assess the correlation between maturation stages of the middle phalanx of the third finger and calcification stages mandibular of the third molar in 9-16 years old children in the South Indian population. A total of 39 subjects between the age of 9-16 years were included for this study. Their pretreatment digital panoramic and hand-wrist radiographs were retrieved from the DIAS software provided by Saveetha Dental College and Hospital, Chennai, TamilNadu, India. These records were analyzed with the help of Demirjian index, used for mandibular third molar maturation stage, and Modified MP3 method, used for Middle phalanx maturation stage. Pearson's Chi-Square tests were done to analyze the association between Mp3 stages and mandibular third molar calcification stages. The statistical tests were performed in SPSS software. The results of this study showed that there is a statistically significant association between Demirjian index and modified MP3 stages in both females ($p < 0.002$) and males ($p < 0.000$). Within the limitations of this study, it was concluded that calcification stages of the lower third molar could be used as a supportive tool to assess maturation. As third molars are known to have many alterations, individual variation should be taken under consideration.



*Corresponding Author

Name: Ravindra Kumar Jain
Phone: +919884729660
Email: ravindrakumar@saveetha.com

ISSN: 0975-7538

DOI: <https://doi.org/10.26452/ijrps.v11iSPL3.3696>

Production and Hosted by

IJRPS | <https://ijrps.com>

© 2020 | All rights reserved.

INTRODUCTION

Growth measurements are very often interpreted with reference to maturity levels in certain regions of the skeleton which has further clinical implications. Alterations seen with maturation are

observed in many regions of the body including the dentition and other craniofacial structures during growth and development. Time plays a critical role in determining the morphological and dimensional results at the end of development (Baccetti *et al.*, 2005). In growing children, certain orthodontic treatment procedures depend on the available growth and development. The orthodontic diagnosis followed by the formulation of treatment plans for the developing individuals must involve growth prediction, chiefly for treatment of skeletal problems (Hegde *et al.*, 2014). The understanding of an individual's stage of growth and development has a definite role in diagnosis, treatment planning, and stability of the treatment outcome (Mokhtar, 2019). Chronologic age depicts only an approximation of the maturational status of an individual. Consequently, dental and skeletal ages had been used as maturity indicators in many studies (Shah and Vig-

nesh, 2019). Growth modulation procedures that alter changes in the skeletal base, such as the use of extra oral orthopedic force or functional devices are suggested to be initiated during active growth periods (Priya and Felicita, 2018).

These active growth spans have to be evaluated objectively for the timing and the amount of active growth direction or vector of growth. Maturational status of an individual can be best evaluated relative to different stages of physiologic maturity rather than evaluating it with chronologic age. In some studies, gonial angle is used as a valuable marker to diagnose the growth pattern of individuals. Hand-wrist radiographs were employed as a supplemental diagnostic aid in addition to other essential diagnostic radiographs such as intraoral periapical (IOPA), orthopantomogram (OPG) and lateral cephalogram to assess skeletal growth. The credibility of hand-wrist radiographic analysis has been confirmed by numerous studies (Flores-Mir et al., 2006; Grave and Brown, 1976; Houston et al., 1980; Reddy et al., 2014).

The orthopantomogram is a radiographic examination instrumental in all dental specialties, especially orthodontics (Baskaran, 2017). Cephalometrics is an important diagnostic tool in the field of orthodontics (Kamath and Arun, 2016). It is used to assess the relationship of the jaws in all three spatial planes, namely, anteroposterior, vertical and transverse. CBCT is considered as an ideal advanced diagnostic imaging modality in the field of modern dental practice. But radiation exposure is high compared to other radiographic modalities. Hence, for this study, the use of CBCT was excluded. Many studies (Hegde et al., 2014; Reddy et al., 2014) have revealed a significant association between stages of skeletal maturation and dental calcification. In general, dental development can be estimated by either the stage of tooth eruption or level of tooth calcification (Krishnan et al., 2018; Samantha et al., 2017).

Assessment of skeletal maturity with stages of lower third molar calcification from an OPG provides an advantage over conventional hand-wrist radiographic methods as no other additional radiation exposure would be necessary for assessing skeletal maturity. This allows us to follow the "As Low As Reasonably Achievable" (ALARA) concept (Kumar et al., 2014). The most common problem in any diagnostic system is to establish a range of normality. Hence, this study was done to correlate the skeletal maturity by comparing the eight developmental stages of the third molar using the Demirjian index stages assessed on an OPG with that of six developmental stages of modified MP3 of the left-hand

wrist. The data obtained from the study were tabulated (Jain et al., 2014; Krishnan et al., 2018).

MATERIALS AND METHODS

This retrospective cross-sectional study was carried out at Saveetha Dental College, Chennai, Tamil Nadu, India. A total of 39 subjects between the age group of 9-16 years were selected for this study. Their respective OPG and hand-wrist radiographs were obtained from the patient record provided by the institution. The radiographs of the subjects with conditions like muscular dystrophy, congenital abnormalities which affect growth and development and traumatic lesions of the jaw or hand-wrist, also subject with other systemic conditions were excluded. Evaluation of the dental maturity of the mandibular third molar was done with the Demirjian Index on OPG. The evaluation of skeletal maturity was done on hand-wrist radiographs by the modified MP3 method. SPSS software was used to perform statistical analysis and data management for Windows and Google Excel Spreadsheet was used for data tabulation. Analyses were done in both males and females of the sample group. Pearson's Chi-square tests were done to estimate the association between maturation stages of MP3 and mandibular third molar.

RESULTS AND DISCUSSION

In the present study, a statistically significant association was noted between Demirjian Index and modified MP3 in males ($p < 0.000$) Figure 1 and females ($p < 0.002$) Figure 2. Among males, there is a statistically significant association between Demirjian index stage 4 and MP3 index stage 2 Figure 1. Among females, stage 4 of the Demirjian index has a significant association with stage 3 and 4 of the Modified MP3 index Figure 2. Previously our team had conducted numerous clinical trials (Felicita, 2017; Viswanath et al., 2015; Kamisetty et al., 2015), lab animal studies (Rubika et al., 2015; Kumar et al., 2011; Murugesan and Jain, 2020) and in-vitro studies (Felicita et al., 2012; Dinesh et al., 2013; Arvind and Jain, 2020) over the past five years. Now we are focusing on epidemiological surveys.

The idea for this survey stemmed from the current interest in our community (Vikram et al., 2017; Sivamurthy and Sundari, 2016). In this study, the results showed a statistically significant positive correlation between dental maturity (DI) and skeletal maturity (MP3) which is consistent with findings of Mehta et al. (Mehta et al., 2016), Suma et al. (Suma et al., 2011), Sun-Mi et al. (Cho and Hwang, 2009) and Engstrom et al. (Engström et al.,

1983). The correlation between the calcification stages of MP3 of left hand and mandibular third molar was found to be significantly high ($P < 0.002$) for both genders. A variety of cephalometric analyses have been reported described in the past for different applications in orthodontics by measuring individual planes, angles and lines between anthropometric landmarks recognized by prominent physical anthropologists and orthodontists. The primary use of such applications was to impart a means to compare individual dentofacial characteristics with a population average and also to ascertain areas of specific deviation, also a description of the spatial relationship between various parts of the craniofacial structures can be determined.

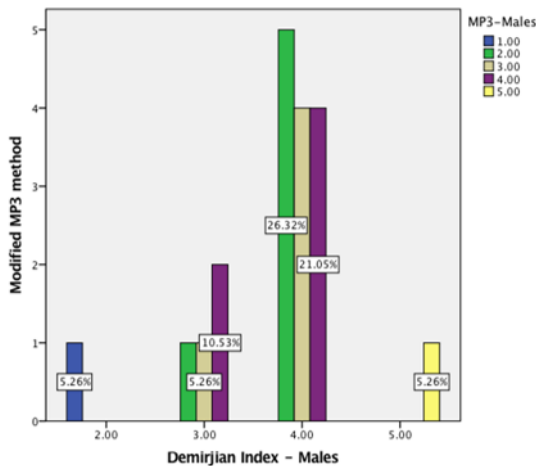


Figure 1: Bar chart represents the association between the Demirjian Index for mandibular third molar maturation and MP3 for skeletal maturation among the male population.

In the study done by Sun-Mi et al., the relationship between skeletal maturity and mandibular third molar calcification was probed into using skeletal maturation indicators, CVM indicators and Demirjian index. On the evaluation of the inter correlations, each showed a statistically significant correlation, with a slightly higher correlation seen between Demirjian index and skeletal maturation than Demirjian index and cervical maturation. The authors concluded that the end of growth spurt coincides with the formation of the pulp chamber, while the root length is either equal to or greater than the crown height of the third molar (Cho and Hwang, 2009). These findings are similar to those of Chertkow and Fatti (Chertkow and Fatti, 1979) and Engstrom et al. (Engström et al., 1983) who also report a strong correlation between third molar formation and skeletal maturity. Evaluation of a patient's puberty and developmental events is required for the execution of certain orthodontic treatments. Information about the pubertal growth

spurt of a patient plays a role in diagnosis objectives and treatment modality selection (Krailassiri et al., 2002). The use of hand-wrist radiographs has been recommended and practiced widely to assess the individual's skeletal age (Flores-Mir et al., 2006; Houston et al., 1980; Uysal et al., 2004).

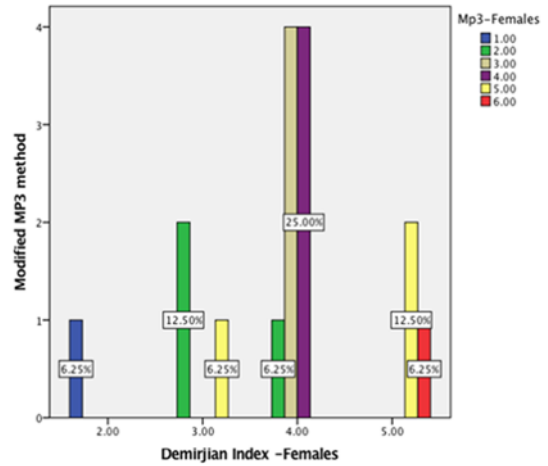


Figure 2: Bar chart represents the association between the Demirjian Index for mandibular third molar maturation and MP3 for skeletal maturation among the female population.

Many studies have reported that the period of pubertal growth changes happening in the craniofacial region is closely linked to specific ossification stages detected in the hand-wrist area of the skeleton. Hence, hand-wrist radiographs are believed to be a beneficial diagnostic tool in Orthodontics. However, these radiographs are associated with additional radiation exposure to the patient. The simplicity of differentiating the dental development stages and easy accessibility of OPG are main reasons for trying to assess the physiologic maturity as an alternative to hand-wrist radiographs. In contrast to the findings of this study, the studies done by Krailassiri et al. (Krailassiri et al., 2002) and Uysal et al. (Uysal et al., 2004) showed that the lower third molar demonstrated the lowest correlation. Garn et al. (Garn et al., 1963) and Tanner (Tanner, 1970) have reported insignificant correlations between the level of dental and skeletal maturation.

The low level of concordance among the results of previous studies may be due to the different methods used for assessing skeletal and dental maturity. This study in its entirety is a theoretical one and is based on well-known mathematical and physical formulae. It is important to note that different samples may affect the results of the correlation between the bone and dental maturity, especially in the I third molars, as they are known for their many alterations based on previous studies. The concordance between skeletal maturity and teeth develop-

ment could allow practitioners to use mandibular third molars as a substitute to evaluate the stage of skeletal maturity in the growing patients from the panoramic radiographs. The present study is limited to a certain population. It has a small sample size.

CONCLUSION

Within the limitations of the present study, it can be concluded that calcification stages of mandibular third molars can be considered for assessing skeletal maturity, which can be used to anticipate the growth status to determine the optimal time for orthodontic treatment. As third molars are known to have many developmental variations, individual variations should be taken under consideration.

Funding Support

The authors declare that they have no funding support for this study.

Conflict of Interest

The authors declare that they have no conflict of interest for this study.

REFERENCES

- Arvind, T. P., Jain, R. K. 2020. Skeletally anchored for-sus fatigue resistant device for correction of Class II malocclusions-A systematic review and meta-analysis. *Orthodontics and Craniofacial Research*, pages 1-10.
- Baccetti, T., et al. 2005. The Cervical Vertebral Maturation method for the assessment of optimal treatment timing in dentofacial orthopedics. *Seminars in Orthodontics*, 11(3):119-129.
- Baskaran, K. 2017. Comparison of the Image Quality of Intraoral Radiograph (IOPA) and Orthopantomograms (OPG). *International Journal of Science and Research*, 6(5):67-71.
- Chertkow, S., Fatti, P. 1979. The relationship between tooth mineralization and early radiographic evidence of the ulnar sesamoid. *Angle Orthodontist*, 49(4):282-288.
- Cho, S. M., Hwang, C. J. 2009. Skeletal maturation evaluation using mandibular third molar development in adolescents. *Korean Journal of Orthodontics*, 39(2):120-129.
- Dinesh, S., et al. 2013. An indigenously designed apparatus for measuring orthodontic force. *Journal of clinical and diagnostic research*, 7(11):2623-2626.
- Engström, C., et al. 1983. Lower third molar development in relation to skeletal maturity and chronological age. *Angle orthodontist*, 53(2):97-106.
- Felicita, A. S. 2017. Quantification of intrusive retraction force and moment generated during enmasse retraction of maxillary anterior teeth using mini-implants: A conceptual approach. *Dental Press Journal of Orthodontics*, 22(5):47-55.
- Felicita, A. S., et al. 2012. Determination of craniofacial relation among the subethnic Indian population: A modified approach - (Sagittal relation). *Indian Journal of Dental Research*, 23(3):305.
- Flores-Mir, C., et al. 2006. Correlation of skeletal maturation stages determined by cervical vertebrae and hand-wrist evaluations. *The Angle Orthodontist*, 76(1):1-5.
- Garn, S. M., et al. 1963. Third Molar Polymorphism and its Significance to Dental Genetics. *Journal of Dental Research*, 42(6):1344-1363.
- Grave, K. C., Brown, T. 1976. Skeletal ossification and the adolescent growth spurt. *American Journal of Orthodontics*, 69(6):611-619.
- Hegde, G., et al. 2014. A new system for assessment of growth using mandibular canine calcification stages and its correlation with modified MP3 stages. *Journal of Pharmacy and Bioallied Sciences*, 6(1):58-63.
- Houston, W. J., et al. 1980. Relationships between skeletal maturity estimated from hand-wrist radiographs and the timing of the adolescent growth spurt. *European Journal of Orthodontics*, 2(2):81-93.
- Jain, R. K., et al. 2014. Comparison of intrusion effects on maxillary incisors among mini implant anchorage, j-hook headgear and utility arch. *Journal of clinical and diagnostic research*, 8(7):21-24.
- Kamath, M. K., Arun, A. V. 2016. Comparison of cephalometric readings between manual tracing and digital software tracing: A pilot study. *International Journal of Orthodontic Rehabilitation*, 7(4):135-138.
- Kamisetty, S. K., et al. 2015. SBS vs Inhouse recycling methods-An invitro evaluation. *Journal of clinical and diagnostic research*, 9(9):ZC04-ZC08.
- Krailassiri, S., et al. 2002. Relationships between dental calcification stages and skeletal maturity indicators in Thai individuals. *Angle Orthodontist*, 72(2):155-166.
- Krishnan, S., et al. 2018. Angular photogrammetric analysis of the soft-tissue facial profile of Indian adults. *Indian Journal of Dental Research*, 29(2):137.
- Kumar, K. R., et al. 2011. Depth of resin penetration into enamel with 3 types of enamel conditioning

- methods: A confocal microscopic study. *American Journal of Orthodontics and Dentofacial Orthopedics*, 140(4):479–485.
- Kumar, S. P., et al. 2014. Comparison of intrusion effects on maxillary incisors among mini-implant anchorage, j-hook headgear and utility arch. *Journal of clinical and diagnostic research*, 8(7):ZC21–ZC24.
- Mehta, N., et al. 2016. Evaluation of skeletal maturation using mandibular third molar development in Indian adolescents. *Journal of Forensic Dental Sciences*, 8(2):112–113.
- Mokhtar, M. A. M. 2019. Assessment of pubertal growth spurt in Egyptian adolescent females using modified middle phalanx of the middle finger stages and its relation to body height Aswan and El Minia governments A cross sectional study. *Cu Theses*, pages 1–15.
- Murugesan, A., Jain, R. K. 2020. A 3D comparison of dimension of infrazygomatic crest region in different vertical skeletal patterns: A retrospective study. *International Orthodontics*, 18(4):770–775.
- Priya, B., Felicita, A. S. 2018. Evaluation of correlation between cervical vertebra, MP3 and canine calcification in Chennai population. *Drug Invention Today*, 10(1):2614–2617.
- Reddy, V. V., et al. 2014. A Comparison of Skeletal Maturation assessed from MP3 and its Correlation with Dental Maturation. *Journal of Indian Orthodontic Society*, 48(4):325–328.
- Rubika, J., et al. 2015. Gonial Angle as an Indicator for the Prediction of Growth Pattern. *World Journal of Dentistry*, 6(3):161–163.
- Samantha, C., et al. 2017. Comparative evaluation of two Bis-GMA based orthodontic bonding adhesives-A randomized clinical trial. *Journal of Clinical and Diagnostic Research*, 11(4):ZC40–ZC44.
- Shah, P. M., Vignesh, R. 2019. Correlation of dental age, skeletal age, and chronological age among children aged 7-16 years: A retrospective study. *Journal of Indian Society of Pedodontics and Preventive Dentistry*, 11(1):5–9.
- Sivamurthy, G., Sundari, S. 2016. Stress distribution patterns at mini-implant site during retraction and intrusion—a three-dimensional finite element study. *Progress in Orthodontics*, 17(1):4.
- Suma, G. N., et al. 2011. Radiographic correlation of dental and skeletal age: Third molar, an age indicator. *Journal of Forensic Dental Sciences*, 3(1):14–18.
- Tanner, J. M. 1970. Growth and Development at Adolescence. *Endocrinology of Development and Maturation*, pages 117–130.
- Uysal, T., et al. 2004. Relationships between dental and skeletal maturity in Turkish subjects. *Angle Orthodontist*, 74(5):657–664.
- Vikram, N. R., et al. 2017. Ball Headed Mini Implant. *Journal of clinical and diagnostic research*, 11(1):ZL02–ZL03.
- Viswanath, A., et al. 2015. Obstructive sleep apnea: awakening the hidden truth. *Nigerian Journal of clinical practice*, 18(1):1–7.