



Prevalence of type of maxillary labial frenal attachment among 18-30 years: A retrospective study

Jitesh S¹, Arvina Rajasekar*¹, Madhulaxmi M²

¹Department of Periodontics, Saveetha Dental College & Hospitals, Saveetha Institute of Medical and Technical Sciences, Saveetha University, Chennai-77, Tamil Nadu, India

²Department of Oral and Maxillofacial Surgery, Saveetha Dental College & Hospitals, Saveetha Institute of Medical and Technical Sciences, Saveetha University, Chennai-77, Tamil Nadu, India



Article History:

Received on: 25 Jul 2020
Revised on: 09 Oct 2020
Accepted on: 03 Dec 2020

Keywords:

Frenum,
Maxilla,
Frenulum,
Oral mucosa,
Interdental papilla

ABSTRACT

The frenum has its origin from the remnant of central cells of vestibular lamina which predominantly has connective tissue and least amount of muscle fibers. Labial frenum is a vertical band of oral mucosa that attaches the cheeks and lips to the alveolar mucosa of the mandibular and maxillary arches, limiting the movement of the lips and cheeks. The aim of the study was to find out the prevalence of the type of maxillary labial frenal attachment among 18-30 years. The present retrospective study was conducted among 100 outpatients who reported to a private institution in Chennai from June 2019 to March 2020. Data regarding the type of frenal attachment was collected and analysed. From our current study, it was found out that out of 100 patients, 41% had a gingival type, 27% had a mucosal and papillary type, 5% had the papillary penetrating type of maxillary labial frenal attachment and there was no significant association between gender and type of frenal attachment (Pearson Chi-Square test - 1.105, df-3, p value - 0.776(>0.05); statistically not significant). Within the limitations of the present study, the most prevalent type of maxillary frenal attachment in the given population was a gingival type. Least prevalent type was papillary penetrating and there was no significant association between gender and type of frenal attachment.

*Corresponding Author

Name: Arvina Rajasekar
Phone: +91 9486442309
Email: arvinar.sdc@saveetha.com

ISSN: 0975-7538

DOI: <https://doi.org/10.26452/ijrps.v11iSPL3.3650>

Production and Hosted by

IJRPS | <https://ijrps.com>

© 2020 | All rights reserved.

iting the movement of the lips and cheeks (Parker, 1937; Thamaraiselvan *et al.*, 2015). Maxillary labial frenum has fibrous tissue which runs in the anterior-posterior direction and it ends by merging to the submucosal fibers of the lips (Dewel, 1946; Kavarthapu and Thamaraiselvan, 2018). The frenum has its origin from the remnant of central cells of vestibular lamina which predominantly has connective tissue and least amount of muscle fibers. The maxillary labial frenum is also said to be the posteruptive remnant of tecto labial bands (Dewel, 1946; Varghese *et al.*, 2015).

INTRODUCTION

Labial frenum is a vertical band of oral mucosa that attaches the cheeks and lips to the alveolar mucosa of the mandibular and maxillary arches, lim-

Frenal attachments are at different levels at various stages of growth and development (Ceremello, 1953). Frenal attachments are classified as four types by Placek *et al.* (Mirko *et al.*, 1974). Mucosal - when the frenal fibers are attached upto mucogin-

gival junction; Gingival - when fibers are inserted within attached gingiva; Papillary - when fibers are extending into interdental papilla; Papilla penetrating - when the frenal fibers cross the alveolar process and extend up to palatine papilla.

Papillary and papillary penetrating type of frenal attachments are said to be pathological beyond mixed dentition. As the pull of the abnormal frenal attachment is greater than normal, it produces a constant force on the attached gingiva leading to localized gingival recession and requires treatment (Arvina and Kumar, 2019; Khalid *et al.*, 2016; Mootha *et al.*, 2016). It may also lead to midline diastema, which leads to flaring of the two upper central incisors due to the presence of thick bands of the frenum, which is not self correcting and it requires minor surgical correction (Avinash *et al.*, 2017; Panda *et al.*, 2014).

Clinically, papillary and papilla penetrating frenum have been found to be associated with loss of papilla, recession, diastema, difficulty in brushing, malalignment of teeth and it may also prejudice the denture fit or retention leading to psychological disturbances to the individual (Mootha *et al.*, 2016; Janarthanan *et al.*, 2019).

The type of the maxillary labial frenal attachment and its morphology in Chennai has not been studied extensively. The purpose of this retrospective study was to determine the prevalence of the type of maxillary frenal attachment among 18-30 years.

MATERIALS AND METHODS

This retrospective study was undertaken using a convenience sample of patients aged 18 to 30 years reported to a private institution in Chennai from June 2019 to March 2020. The study consisted of a total of 100 patients, including 61 males and 39 females. Data regarding the type of frenum was collected and categorized based on the classification by Placek *et al.* and the prevalence was assessed. Ethical approval for the study was obtained from Saveetha University Ethical Review Board (SDC/SIHEC/2020/DIASDATA/0619-0320).

RESULTS AND DISCUSSION

Data collected were entered in SPSS version 20 and was subjected to statistical analysis. Results were tabulated and represented graphically. Out of 100 patients, 61% were males and 39% were females. (Figure 1) Also, regarding the type of frenal attachment, 41% had a gingival type, 27% had a mucosal and papillary type, 5% had the papillary penetrating type of maxillary labial frenal attachment (Fig-

ure 2). The association between the type of frenal attachment among males and females. X axis represents the gender and Y axis represents the percentage distribution of the subjects. Association tested by Pearson Chi-Square test - 1.105, df-3, p value - 0.776(>0.05); statistically not significant. (Figure 3) Gingival type of frenal attachment (green) is more likely to occur in males and females. However, there was no significant association between gender and type of frenal attachment.

The maxillary labial frenum is in a passive relationship with the maxillary alveolar process and its pattern of development is dependent on alveolar growth (Khalid, 2017; Khalid *et al.*, 2016). In this present study, the prevalence of the type of maxillary labial frenal attachment among Chennai population was assessed. In this present study, we followed Placek *et al.* classification of frenal attachments, as this classification is extensively used among children and adults in numerous studies (Janczuk and Banach, 1980; Addy *et al.*, 1987; Boutsis and Tatakis, 2011).

If the papillary penetrating type of frenal attachments persists even after mixed dentition, it may lead to several consequences, such as midline diastema and dental caries (Ramesh *et al.*, 2016, 2017; Kavarthapu and Thamaraiselvan, 2018). The treatment of midline diastema is most commonly frenectomy followed by orthodontic treatment to correct a malalignment. Abnormal frenal attachment may also lead to speech abnormality, poor oral hygiene maintenance (Priyanka, 2017). In this study, there was no significant association of frenal type with gender. Both males and females had more or less equal distribution which is in accordance with a study done in Greece (Boutsis and Tatakis, 2011; Ravi *et al.*, 2017; Ramamurthy and Visha, 2018).

In the present study, the most common type of frenal attachment was found to be gingival. Similarly, Boutsis *et al.*, (Boutsis and Tatakis, 2011) Addy *et al.*, (Addy *et al.*, 1987) Kaimenyi, (Kaimenyi, 1998) in their studies showed the most prevailing type of frenal attachment was gingival. However, Placek *et al.* (Mirko *et al.*, 1974) and Janczuk and Banach (Janczuk and Banach, 1980; Ramesh *et al.*, 2016) had found the mucosal type of frenal attachment to be common in Czech and Polish teens.

The limitation of this study is its smaller sample size. A similar study should be conducted on a larger scale involving a large number of samples for more reliable results (Ramamurthy and Visha, 2018; Ramesh *et al.*, 2019). Therefore, extensive studies need to be conducted to assess the type of frenal attachment

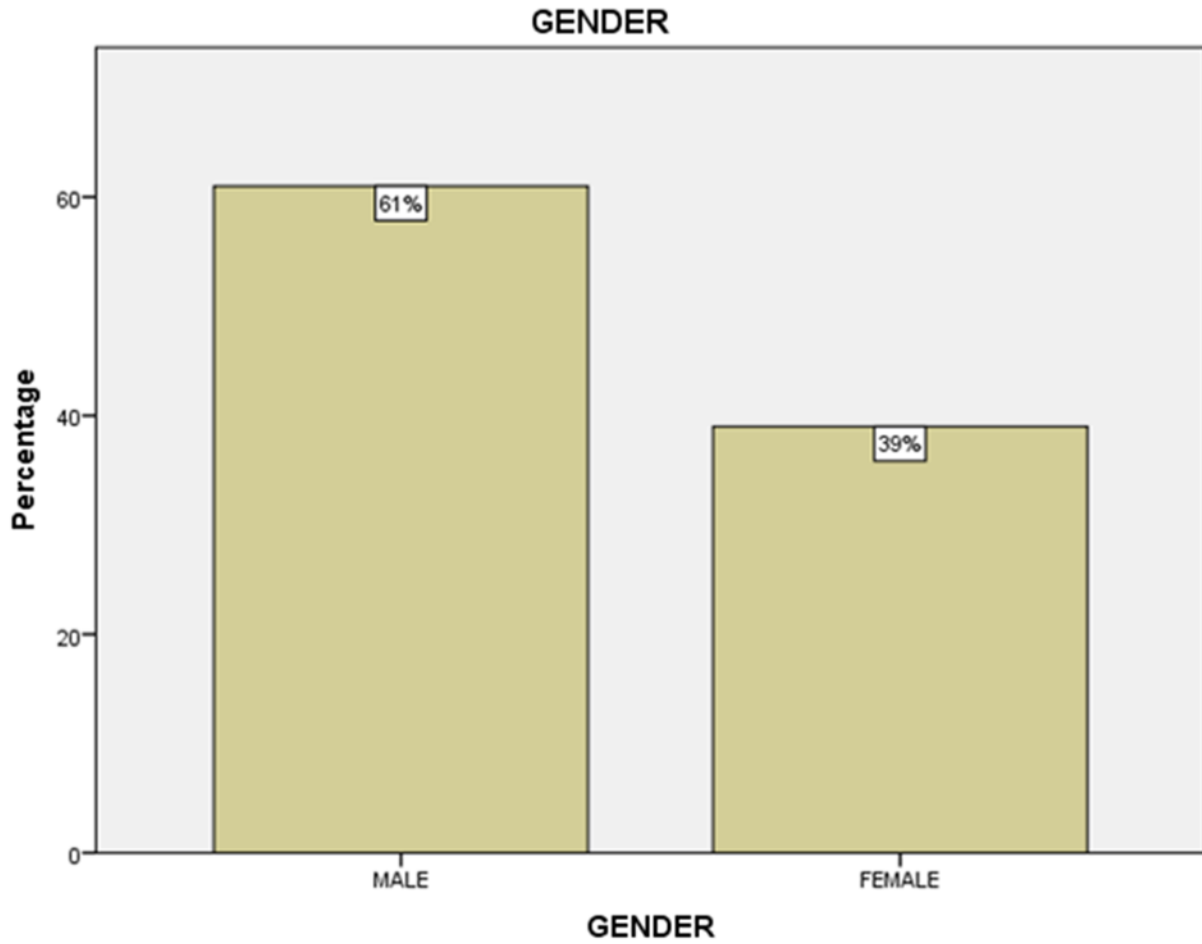


Figure 1: Bar chart depicts the gender distribution of the present study

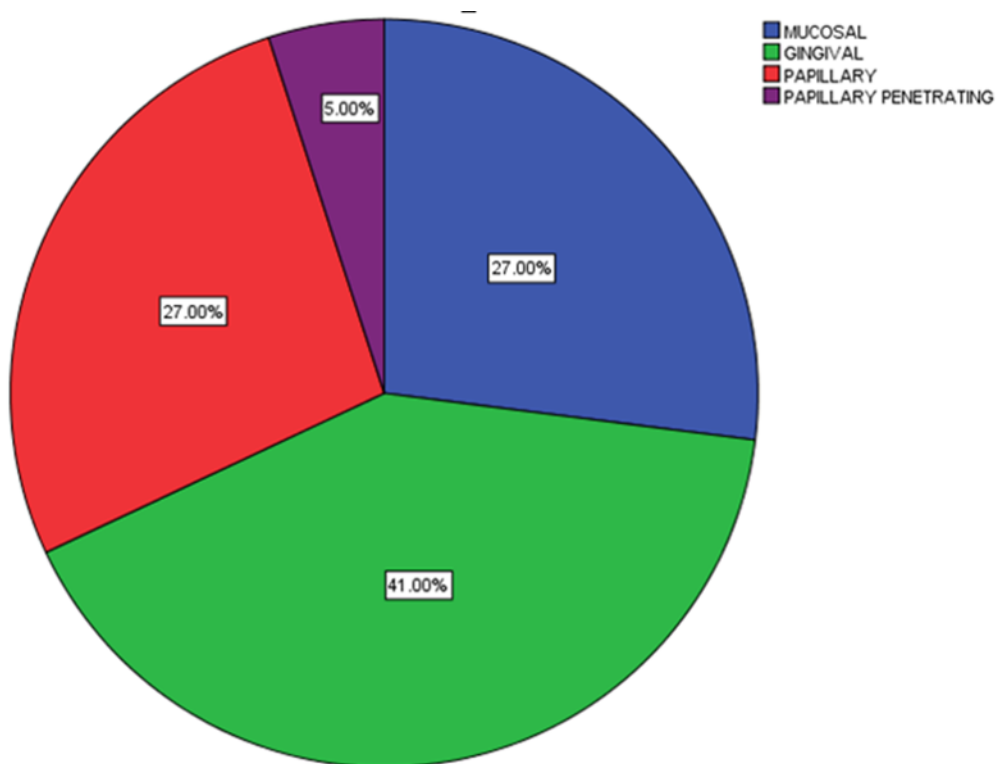


Figure 2: Pie chart shows the type of frenal attachment

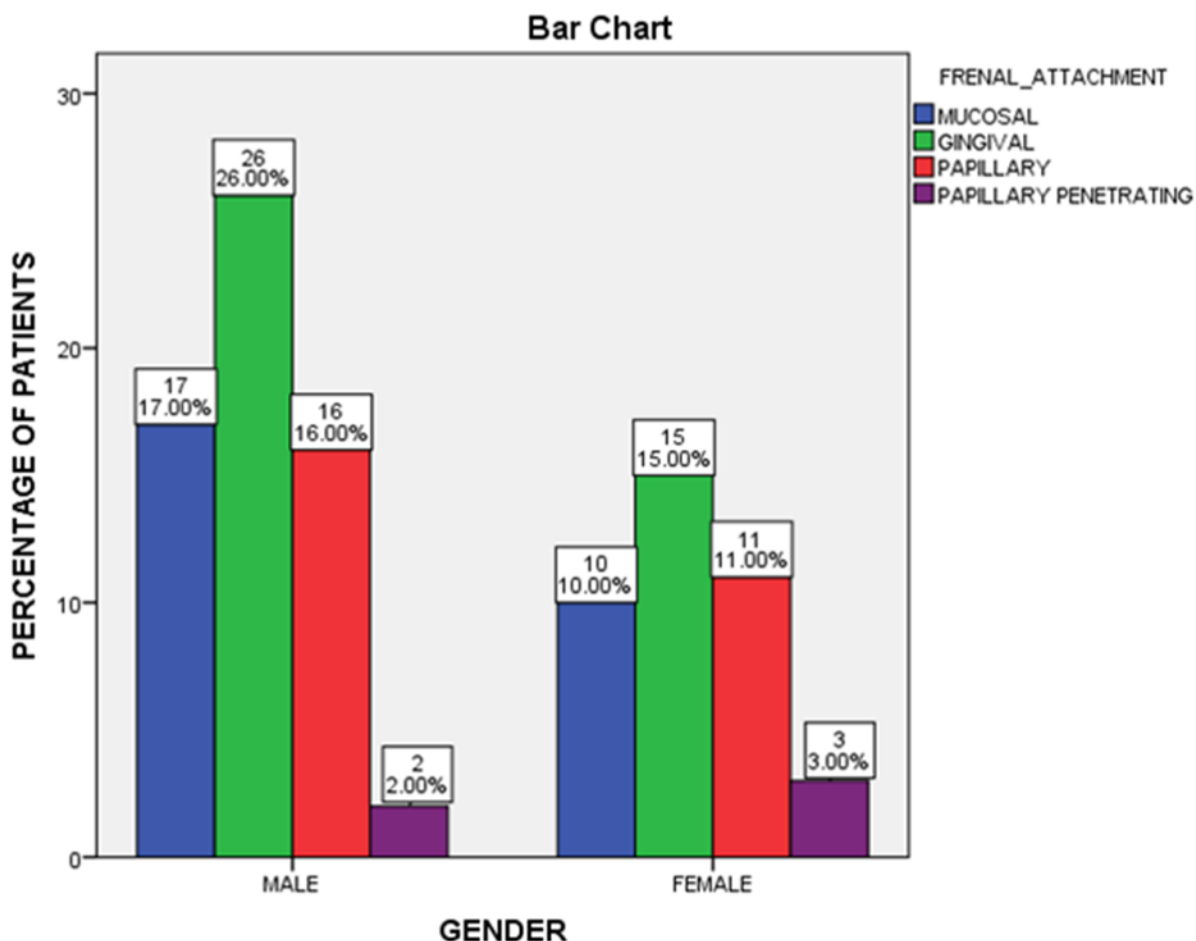


Figure 3: Bar graph depicting the association between the type of frenal attachment among males and females

and associated complications.

CONCLUSION

Within the limits of the present study, the most prevalent type of maxillary labial frenal attachment among 18-30 years was found to be gingival type (41%) and the least prevalent type was papillary penetrating (5%). Also, there was no significant association between gender and type of frenal attachment.

ACKNOWLEDGEMENT

The authors of this study would like to express their gratitude towards everyone who facilitated and enabled us to carry out this study successfully.

Funding Support

The authors declare that they have no funding support for this study.

Conflict of Interest

The authors declare that they have no conflict of interest for this study.

REFERENCES

Addy, M., Dummer, P. M. H., Hunter, M. L., Kingdon, A., Shaw, W. C. 1987. A Study of the Association of Fraenal Attachment, Lip Coverage, and Vestibular Depth with Plaque and Gingivitis. *Journal of Periodontology*, 58(11):752-757.

Arvina, R., Kumar, B. V. 2019. Frenectomy with Laterally Displaced Flap: A Case Report. *Research Journal of Pharmacy and Technology*, 12(8):3669.

Avinash, K., Malaippan, S., Dooraiswamy, J. N. 2017. Methods of Isolation and Characterization of Stem Cells from Different Regions of Oral Cavity Using Markers: A Systematic Review. *International Journal of Stem Cells*, 10(1):12-20.

Boutsi, E. A., Tatakis, D. N. 2011. Maxillary labial frenum attachment in children. *International Journal of Paediatric Dentistry*, 21(4):284-288.

Ceremello, P. J. 1953. The superior labial frenum and the midline diastema and their relation to growth and development of the oral structures. *American Journal of Orthodontics*, 39(2):120-139.

- Dewel, B. F. 1946. The Normal and the Abnormal Labial Frenum: Clinical Differentiation. *The Journal of the American Dental Association*, 33(5):318–329.
- Janarthanan, S., Arun, R. T., Srinivasan, S., Kumar, S. S. 2019. Frenectomy with laterally displaced flap: A case series. *Indian Journal of Dental Sciences*, 11(2):112.
- Janczuk, Z., Banach, J. 1980. Prevalence of narrow zone of attached gingiva and improper attachment of labial frena in youths. *Community Dentistry and Oral Epidemiology*, 8(7):385–386.
- Kaimenyi, J. T. 1998. Occurrence of midline diastema and frenum attachments amongst school children in Nairobi, Kenya. *Indian Journal of Dental Research : Official Publication of Indian Society for Dental Research*, 9(2):67–71.
- Kavarthapu, A., Thamaraiselvan, M. 2018. Assessing the variation in course and position of inferior alveolar nerve among south Indian population: A cone beam computed tomographic study. *Indian Journal of Dental Research*, 29(4):405.
- Khalid, W. 2017. Comparison of Serum Levels of Endothelin-1 in Chronic Periodontitis Patients Before and After Treatment. *Journal of Clinical and Diagnostic Research*, 11(4).
- Khalid, W., Vargheese, S., Lakshmanan, R., Sankari, M., Jayakumar, N. D. 2016. Role of endothelin-1 in periodontal diseases: A structured review. *Indian Journal of Dental Research*, 27(3):323.
- Mirko, P., Miroslav, S., Lubor, M. 1974. Significance of the Labial Frenum Attachment in Periodontal Disease in Man. Part 1. Classification and Epidemiology of the Labial Frenum Attachment. *Journal of Periodontology*, 45(12):891–894.
- Mootha, A., Malaiappan, S., Jayakumar, N. D., Vargheese, S. S., Thomas, J. T. 2016. The Effect of Periodontitis on Expression of Interleukin-21: A Systematic Review. *International Journal of Inflammation*, 2016:1–8.
- Panda, S., Jayakumar, N. D., Sankari, M., Vargheese, S., Kumar, D. 2014. Platelet rich fibrin and xenograft in treatment of intrabony defect. *Contemporary Clinical Dentistry*, 5(4):550.
- Parker, D. B. 1937. Surgical consideration of abnormal frena. *International Journal of Orthodontia and Oral Surgery*, 23(11):1141–1148.
- Priyanka, S. 2017. Detection of cytomegalovirus, Epstein-Barr virus, and Torque Teno virus in subgingival and atheromatous plaques of cardiac patients with chronic periodontitis. *Journal of Indian Society of Periodontology*, 21(6):456–460.
- Ramamurthy, J., Visha, M. G. 2018. Comparison of effect of hiora mouthwash versus chlorhexidine mouthwash in gingivitis patients: a clinical trial. *Asian Journal of Pharmaceutical and Clinical Research*, 11(7):84.
- Ramesh, A., Ravi, S., Kaarthikeyan, G. 2017. Comprehensive rehabilitation using dental implants in generalized aggressive periodontitis. *Journal of Indian Society of Periodontology*, 21(2):160–160.
- Ramesh, A., Vargheese, S., Doraiswamy, J., Malaiappan, S. 2016. Herbs as an antioxidant arsenal for periodontal diseases. *Journal of Intercultural Ethnopharmacology*, 5(1):92.
- Ramesh, A., Vellayappan, R., Ravi, S., Gurumoorthy, K. 2019. Esthetic lip repositioning: A cosmetic approach for correction of gummy smile – A case series. *Journal of Indian Society of Periodontology*, 23(3):290.
- Ravi, S., Malaiappan, S., Vargheese, S., Jayakumar, N. D., Prakasam, G. 2017. Additive Effect of Plasma Rich in Growth Factors With Guided Tissue Regeneration in Treatment of Intrabony Defects in Patients With Chronic Periodontitis: A Split-Mouth Randomized Controlled Clinical Trial. *Journal of Periodontology*, 88(9):839–845.
- Thamaraiselvan, M., Elavarasu, S., Thangakumaran, S., Gadagi, J., Arthie, T. 2015. Comparative clinical evaluation of coronally advanced flap with or without platelet rich fibrin membrane in the treatment of isolated gingival recession. *Journal of Indian Society of Periodontology*, 19(1):66.
- Vargheese, S., Thomas, H., Jayakumar, N. D., Sankari, M., Lakshmanan, R. 2015. Estimation of salivary tumor necrosis factor-alpha in chronic and aggressive periodontitis patients. *Contemporary Clinical Dentistry*, 6(6):152.