



INTERNATIONAL JOURNAL OF RESEARCH IN PHARMACEUTICAL SCIENCES

Published by JK Welfare & Pharmascope Foundation

Journal Home Page: <https://ijrps.com>

The possible protective effect of trimetazidine on imiquimod-induced psoriasis like skin inflammation in an animal model

Mohammed R. Al-Notazy*¹, Mukhallad A. Al-Rubye², Munaf S. Aal-Aaboda³, Haider F. Al-Saedi³, Ban J. Qasim⁴

¹Department of Clinical Pharmacy, College of Pharmacy, Misan University, Iraq

²Department of Pathology, College of Medicine, Misan University, Iraq

³Department of Pharmacology and Toxicology, College of Pharmacy, Misan University, Iraq

⁴Department of Pathology, College of Medicine, Al-Nahrin University, Iraq

Article History:

Received on: 09.09.2018
Revised on: 13.12.2018
Accepted on: 15.12.2018

Keywords:

Psoriasis,
Trimetazidine,
Imiquimod,
IL-8

ABSTRACT

The main objective of our study was to investigate the effects of topical application of trimetazidine on imiquimod induce psoriasis-like skin lesion. 18 mice had the back shaved for topical application and were grouped as follow. In the control group, mice were daily treated with vaseline base only for six days. The induction group included the mice daily treated with 62.5 mg of commercially available 5% IMQ cream (Aldara, MEDA) for 7 days. Trimetazidine group were daily treated with both 62.5 mg of commercially available 5% IMQ cream (Aldara, MEDA) and 2.5% trimetazidine cream for 7 days. Based on the psoriasis area and severity index (PASI), visual inspection of scaling and erythema were independently scored on a scale from 0 to 4 (0, none; 1, slight; 2, moderate; 3, marked; 4, very marked). Hematoxyline-Eosin was used for the histopathological study. In addition, IL-8 was compared across groups by an Immunosorbent Assay (ELISA) test. There was a significant reduction of both epidermal thickness, scaling and erythema in the trimetazidine treated group compared to imiquimod treated group ($p < 0.05$). IL-8, as a marker of inflammation, was decline significantly in trimetazidine treated group compared to the imiquimod group ($p < 0.05$). The histopathological study showed trimetazidine treated group has a marked regression of the proliferation and thickness of the epidermal cell that has been induced by imiquimod.



* Corresponding Author

Name: Mohammed R. Al-Notazy
Phone: 009647732375450
Email: mohammedr291@gmail.com

ISSN: 0975-7538

DOI: <https://doi.org/10.26452/ijrps.v10i1.1782>

Production and Hosted by
IJRPS | <https://ijrps.com>

© 2019 | All rights reserved.

INTRODUCTION

Psoriasis is a chronic inflammatory, a noninfectious and noncurable disease with a negative impact on patients' quality of life (QoL). It can be seen

in all age groups. However, it is most commonly diagnosed in the 50–69 age group (Organization, 2016). Although Psoriasis is usually defined as inflammatory and proliferative conditions of the skin, it may be associated with systemic manifestations affecting a variety of organs (Pariser *et al.*, 2016). For an instant, it is frequently reported that patients with psoriasis have a risk of developing other conditions such as cardiovascular and non-communicable diseases (Alshami, 2010, Augustin *et al.*, 2015).

Both genetic and environmental factors have an impact on the etiology and pathogenesis of psoriasis (Burden and Kirby, 2016). A considerable amount of literature has been published on psoriasis. These works have shown that psoriasis could be triggered by mild trauma (Sagi and Trau, 2011), sunburn, infections (Griffiths and Barker, 2007),

systemic drugs (Ni and Chiu, 2014), alcohol (Zou *et al.*, 2015) etc. In spite, the pathogenesis of psoriasis has received considerable attention among researchers, yet there is a lot of information have to be known. Furthermore, psoriasis is now recognizable as an immune-mediated disorder (Griffiths and Barker, 2007). TNF alpha, dendritic cells and T cells also have a key role in its pathogenesis (Bejarano and Valdecantos, 2013). A variety of inflammatory mediators are usually expressed in psoriasis skin lesions (TNF, vascular endothelial growth factor (VEGF), interferon- γ , IL-1, IL-6, IL-8, IL-17, IL-22, IL-23, etc.) (Davidovici *et al.*, 2010).

Regarding psoriasis treatment, many therapeutic modalities have been implemented just to reduce the symptoms and appearance of the disease (Griffiths and Barker, 2010). Well-Known examples of psoriasis treatment strategies are topical and oral corticosteroids, cyclosporine, psoralen plus ultraviolet (UV)-A, methotrexate, and oral and topical retinoids. A combination of these therapies has been suggested in order to allow the lower possible doses of each and to increase the drug's effectiveness (Griffiths and Barker, 2010). Adjuncts to treatment included sunshine, moisturisers, and salicylic acid as a scale-removing agent. Although these therapeutic strategies express a good short-term efficacy, long-term use of these agents may cause a wide range of adverse effects like cardiovascular complications, hepatitis, renal diseases, skin cancers, and other organs toxicity (Shear, 2006). Hence, restricted administration of these medications is recommended, and new intermittent, rotational and combination therapy has been applied.

Imiquimod (IMQ) is a ligand for TLR7 and TLR8 and a powerful immune modulator, indicating topically for the treatment of genital warts caused by human papillomavirus (Lebwohl *et al.*, 2004). It has been reported that IMQ can induce and exacerbate psoriasis in well-controlled psoriasis patients during topical treatment of pre-cancerous skin lesions such as actinic keratosis and superficial basal cell carcinomas (Rajan and Langtry, 2006, Fanti *et al.*, 2006). Van der Fits *et al.* 2009 concluded that "the sole application of the innate TLR7/8 ligand IMQ rapidly induces dermatitis closely resembling human psoriasis, critically dependent on the IL-23/IL-17 axis" (van der Fits *et al.*, 2009). The rapid influx of pDC has been seen after application of IMQ on mouse skin (Amberg *et al.*, 2017).

Trimetazidine (TMZ) is commonly used in the treatment of coronary artery diseases as cellular metabolic anti-ischemic agent (Tsioufis *et al.*, 2015). The main action is illustrated by inhibition the long-chain mitochondrial 3-ketoacyl coenzyme A thiolase enzyme, which results in enhancing of

mitochondrial metabolism through inhibition of myocardial fatty acid uptake and oxidation and consequent stimulation of glucose oxidation (Fillmore and Lopaschuk 2013). Existing research on TMZ suggest that TMZ can act as an antioxidant, improve endothelial function (Fragasso *et al.*, 2003), reduce infiltration of neutrophil after ischemia (Shehata, 2014) and inhibit the process of necrosis and apoptosis (Di Napoli, 2008). Having discussed the pathogenesis of psoriasis, this paper will investigate the role of TMZ in reducing the severity of symptoms and reversing the histopathological changes in imiquimod induce psoriasis-like skin lesion in mice model.

MATERIALS AND METHODS

Preparation of cream Formulations: Trimetazidine (2.5 % w/w) was dissolved in glycerin (4% w/w). The preparation was mixed with ethanol to increase the trimetazidine solubility. Cream base was added to complete the volume to 100 g in order to obtain the required concentration.

Physicochemical Evaluation of Prepared Trimetazidine cream: The cream was inspected macroscopically for their physical properties such as colour, clarity, homogeneity and phase separation. The TMZ cream was yellowish, and formulation showed homogeneity with the absence of syneresis and lumps. The pH of the cream formulations was measured with a pH meter. pH of trimetazidine was about 4.8 (4.842 ± 1.2) that considered acceptable to get rid of the risk of skin irritation. Each process repeated in a triplicate manner to express the result as a mean of pH with standard deviation. The spreadability of the formulation was also inspected as mentioned below. 0.5 g of the cream was put within a circle of 1 cm diameter pre-marked on the glass plate of 20×20 cm, over which a second glass plate placed. A weight of 500 g was allowed to rest on the upper glass for 5 min. Then, the increase in diameter due to cream spreading was measured. Formulated cream spreadability of trimetazidine was 6 cm/sec (6 ± 1.5 cm/sec). This is considered as good value compared to other formulations with lower spreadability because of its high micro-viscosity

Irritation Test: The skin irritation study of formulated cream was carried out on human volunteers with consent. There was no irritation that has been seen on the applied surface in all formulations.

Animals and experiment models: Eighteen healthy male adult mice (Albino mice) (25-32 g) obtained from the (National Center for Drug Control and Research) (NCDCR) in Iraq. Mice were housed in polypropylene cages and fed on a standard pellet diet and water *ad libitum*. The room was maintained under controlled condition (12 h light-

dark cycle at 22±2°C) at Misan university/college of pharmacy. Animals were allowed to acclimatise for 7 days prior to experiments being carried out.

Imiquimod-induced psoriasis-like skin lesion in Mice models: In the present study, every 6 mice were grouped as described below and then each mouse had the back shaved for topical application. In the control group, mice were daily treated with vaseline base only for six days. The imiquimod (IMQ) group included the mice daily treated with 62.5 mg of commercially available 5% IMQ cream (Aldara, MEDA) for 7 days. Trimetazidine group were daily treated with both 62.5 mg of commercially available 5% IMQ cream (Aldara, MEDA) and 2.5% trimetazidine cream for 7 days.

Preparation of tissue Homogenate: Freshly harvested 1 gm dorsal tissue stored in 9 ml of phosphate buffered saline. The tissue was homogenized by mortar and pestle, then cool centrifuged adjusted to 5000 rpm for 10 minutes were used. The supernatant was harvested and frozen at -80 °C for further assessment.

Measurement of Biomarkers of Psoriasis: Estimation of mouse IL-8 level in the serum was performed by Enzyme-linked Immunosorbent Assay (ELISA) test using kits purchased from MyBioSource (Cat No. MBS261967, Canada). The ELISA was performed according to the manufacturer's instructions. Detection range was between 15.6–1000 pg/ml which represent the values of the standard curve. The minimum detectable mouse IL-8 up to 5 pg/ml. Any level of interleukin below the lowest level of standard curve considers as negative despite its value, while the levels which located between the range of standard curve consider as positive. The kit was highly specific for mouse IL-8 and has no cross-reaction with other factors.

Score the Severity of Inflammation: Based on the psoriasis area and severity index (PASI), objective severity scoring system of inflammation of the mice back skin was developed. Scaling and erythema were independently scored on a scale from 0 to 4 (0, none; 1, slight; 2, moderate; 3, marked; 4, very marked). The erythema level was scored using a scoring table with red taints. The cumulative score of scaling and erythema has been served as a measure of the severity of inflammation (scale 0–12) (van der Fits *et al.*, 2009).

Statistical analysis: Statistical analysis was performed using a Statistical Package for Social Sciences (SPSS 22). Descriptive statistics for the numerical data were formulated as mean and standard deviation (SD). Visual scoring changes were done by semi-quantitative analysis in which each sample was given a grade (0-4) according to

changes seen. Visual scores comparison between two groups were performed by using the Mann-Whitney U test. An independent t-test was used to compare between groups where P values of less than 0.05 were considered significant (Indrayan and Malhotra, 2017).

RESULTS

Table 1: The effects imiquimod and trimetazidine on erythema

Groups	Mean	Std. Deviation	P value
Control	0.125	0.33000	-
Imiquimod	2.5143	1.19224	0.020
Trimetazidine	1.1700	0.69101	0.035

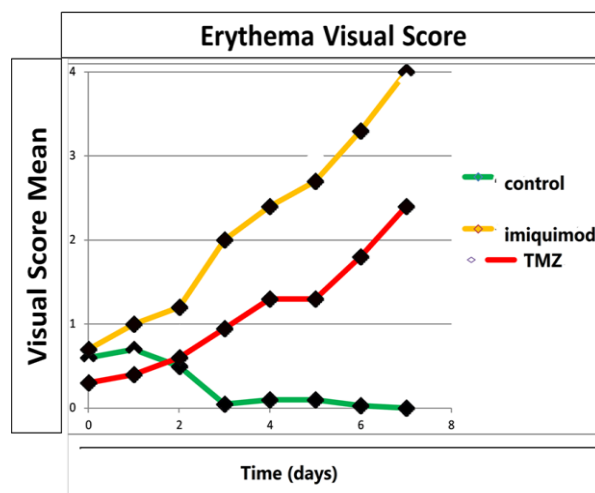


Figure 1: The effects of imiquimod and trimetazidine on erythema

Table 2: The effects of imiquimod and trimetazidine on scaling

Groups	Mean	Std. Deviation	P value
Control	0.000	0.000	-
Imiquimod	2.9143	1.11867	0.001
TMZ	1.1143	0.45981	0.015

Scoring of Clinical Parameters

Clinical parameter scores of psoriatic diseases on mice skin were based on the degree of erythema and scaling on a score of 0-4 (0, none; 1, slight; 2, moderate; 3, marked; 4, very marked). The control group was treated with vaseline showed a non-erythematous skin whereas the imiquimod group exhibited very severe erythema (Table 1, figure 1). In compared to the imiquimod group, the trimetazidine group displayed nearly moderate erythema. Regarding the scaling effect, the imiquimod group showed severe scaling in comparison to the control group. Whatever, the trimetazidine group exhibited a moderate scaling compared to the imiquimod group. The scaling scores were illustrated in table 2 and figure 2.

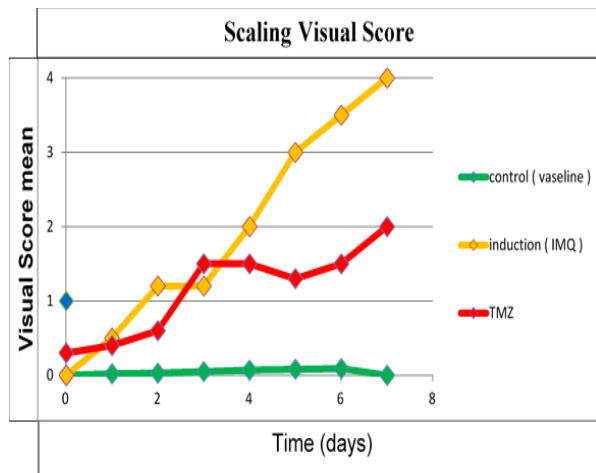


Figure 2: The effects of imiquimod and trimetazidine on Scaling

Table 3: The mean serum IL-8 level among the group of the study

Study Groups	Serum IL8 (pg/l)± SD
Control	0.012±0.006
Imiquimod	0.073±0.007
Trimetazidine	0.018±0.002

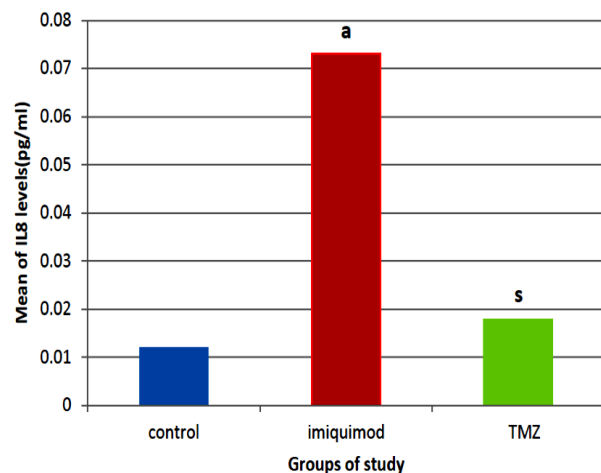


Figure 3: Levels of IL8 as a marker of inflammation in the study groups. (a) imiquimod group of mean p-value ≤ 0.05 when compared to control group; (s), Trimetazidine treated a group of mean p-value ≤ 0.05 when compared to imiquimod induce psoriasis group

The effect of Trimetazidine on serum Interleukin 8 (IL-8) level

This set of analysis shows the impact of trimetazidine on IL8 in imiquimod induce psoriasis-like skin lesion in the mice model. The average level of serum IL-8 in the imiquimod group was significantly higher than of control (Figure 3) (mean±SD, imiquimod 0.073 ±0.007 pg/l versus control 0.012±0.006; $p \leq 0.05$). On average, trimetazidine group was shown to have a significant reduction in serum IL-8 level comparable to imiquimod group (Mean±SD, Imiquimod group 0.073±0.007 pg/l versus Trimetazidine group 0.018±0.002; $p \leq 0.05$) (Figure 3).

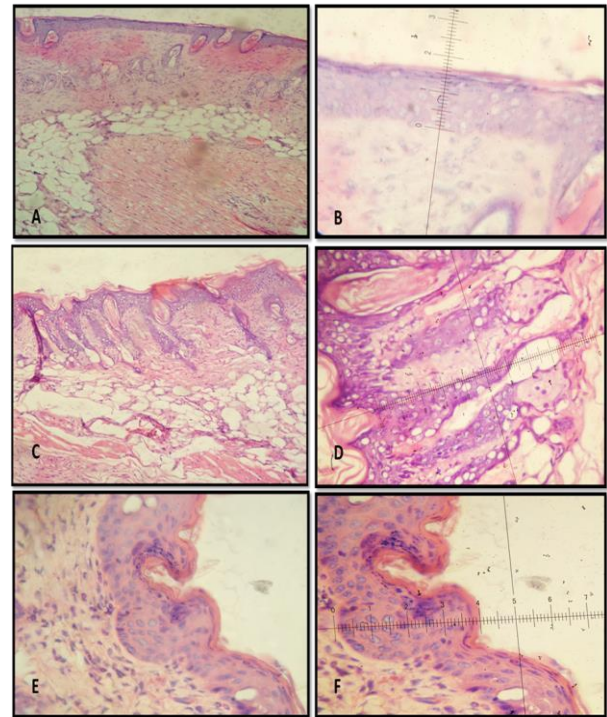


Figure 4: Histological study (A) Skin section from animals of control group reveal normal epidermal and dermal layer (125X) H&E. (B) Skin section from animals of the control group shows the histometric measurement of the epidermal layer (500X) H&E. (C) Skin section from animals treated with Imiquimod (IMQ) shows epidermal thickening with the extension of retepegs to produce Psoriasis-like model (125X) H&E. (D) Skin section from animals treated with Imiquimod (IMQ) shows the histometric measurement of the epidermal extension in Psoriasis-like model (500X) H&E. (E) Skin section from animals treated with Trimetazidine shows normal dermal-epidermal junction with no extension (125X) H&E. (F) Skin section from animals treated with Trimetazidine shows histometric measurement of epidermal thickness appearing with slight thickening (500X) H&E

Histological study

Histopathological results of the skin in the control group revealed that the structure in the animal of the group mentioned appearing with normal appearance (Figure 4; A and B panales). Skin of the animals in the group which has been treated with imiquimod revealed an exaggerated proliferation of the epidermal layer, in which long extension of the epidermal cells has shown clearly. These extensions extend deeply in the dermal layer, as well as there was a thick keratin layer in the superficial aspect of the epidermis producing a psoriasis-like lesion (Figure 4; C and D panels). Finally, skin sections of trimetazidine treated animals revealed marked regression in the proliferation of an epidermal cell, ultimately, there were marked regression in the overall epidermal thickness.

DISCUSSION

Psoriasis is a chronic inflammatory disease of the skin and may be associated with systemic manifestations in a variety of organs (Pariser *et al.*, 2016). (Alshami, 2010, Augustin *et al.*, 2015). Whereas both genetic and environmental factors have implicated in psoriasis aetiology, there would be a great deal of work to be performed to elucidate the disease pathogenesis (Burden and Kirby, 2016). According to recent studies, it is now commonly accepted that psoriasis is an immune-mediated disorder (Griffiths and Barker, 2007). TNF alpha, dendritic cells and T cells play a fundamental role in psoriasis pathogenesis (Bejarano and Valdecantos, 2013). TNF, vascular endothelial growth factor (VEGF), interferon- γ Il-1, Il-6, Il-8, IL-17, IL-22, IL-23, and other inflammatory mediators are usually expressed in psoriatic skin lesion (Davidovici *et al.*, 2010).

Despite a good short-term efficacy of the current treatment modalities, the long-term application may cause a range of systemic adverse effects (Shear, 2006).

A strong relationship between imiquimod and psoriasis-like skin inflammation has been elucidated in the previous studies. Leslie *et al.* 2009 demonstrate that “the skin lesions induced by topical application of IMQ closely resemble human psoriasis lesions” and conclude that “this system is also very suitable for a rapid first in vivo screening of potential antipsoriasis drugs” (van der Fits *et al.*, 2009). Trimetazidine is a metabolic drug commonly used as adjuvant therapy in ischemic heart disease. The main action illustrated by selectively inhibiting KAT enzymes and decreasing oxidation of fatty acids, shifting the metabolism toward glycolysis leading to the formation of a higher amount of ATP (Bellardinelli *et al.*, 2007). Other TMZ actions have been suggested by existing studies including that it can act as a powerful antioxidant, and can increase nitric oxide production which leading to improve endothelial function (Fragasso *et al.*, 2003), it can also inhibit infiltration of neutrophil after ischemic attack (Shehata, 2014), and reduces necrosis and apoptosis by reducing cell damage (Di Napoli, 2008).

This study was carried out with the aim of assessing the importance of trimetazidine as new therapeutics option in imiquimod-induce psoriasis-like skin lesion in mice. The most obvious finding to emerge from the current study is that trimetazidine has an apparent effect on erythema and scaling visual score during the days of the study (Table 1 and 2, Figure 1 and 2) — both erythema and scaling reduced significantly in trimetazidine treated group compared to imiquimod treated group.

Additionally, A firm relationship between serum IL-8 and psoriasis has been reported in the literature (Nickoloff *et al.*, 1991, Schulz *et al.*, 1993). We are able to show for the first time that trimetazidine can significantly reduce the circulating levels of IL-8 as a marker of inflammation to the near normal level seen in the control group (Figure 3). This set of results are in accord with a previous study indicating that the IL-8/IL-8R pathway may have a fundamental role in the pathogenesis of psoriasis and interference with this pathway may offer important mechanism illustrating the therapeutic efficacy of different agents such as cyclosporin A and tacrolimus (Lemster *et al.*, 1995).

Another important finding was that the histopathological changes of the imiquimod-treated group had shown an epidermal thickness with the extension of epidermal into the dermal area. (Figure 4 C and D). These histopathological findings agreed with other previous findings on skin mice after imiquimod application (Gilliet *et al.*, 2004). In contrast, the trimetazidine treated group shows nearly normal dermal-epidermal junction with no extension, however, slight epidermal thickening was also observed compared to the control group (Figure 4 E and F).

CONCLUSION

The main aim of the current study was to examine for the first time the protective effect of trimetazidine on imiquimod-induced-psoriasis-like skin lesion in the mice model. Significant findings to emerge from this study is that trimetazidine can apparently improve the visual scoring of psoriasis-like skin lesion including erythema and scaling. The second major finding was that serum IL-8 level, which is commonly implicated in the pathogenesis of psoriasis, reduced significantly to the near-normal level of the control. Furthermore, the histopathological change also supports our set of findings and show how trimetazidine can rectify the psoriasis-like change induced by imiquimod. The scope of this study was limited in terms of time and sample size. Notwithstanding these limitations, this work offers valuable insights into the treatment of psoriasis. Finally, a further study is required to assess the long-term therapeutic efficacy and safety of trimetazidine on an animal model, hoping to translate the work on human studies.

REFERENCES

- Alshwami, M. 2010. Clinical Profile of Psoriasis in Yemen, A 4 Years Retrospective Study Of 241 Patients. *Journal Of the European Academy of Dermatology & Venereology*, (24), 14.
- Amberg, N., Holcmann, M., Stulnig, G., Gltzner, E. & Sibilja, M. 2017. Effects Of Depilation Methods

- On Imiquimod-Induced Skin Inflammation in Mice. *Journal Of Investigative Dermatology*, (137), 528-531.
- Augustin, M., Radtke, M. A., Glaeske, G., Reich, K., Christophers, E., Schaefer, I. & Jacobi, A. 2015. Epidemiology And Comorbidity in Children with Psoriasis and Atopic Eczema. *Dermatology*, (231), 35-40.
- Bejarano, J. J. R. & Valdecantos, W. C. 2013. Psoriasis As Autoinflammatory Disease. *Dermatologic Clinics*, (31), 445-460.
- Belardinelli, R., Solenghi, M., Volpe, L. & Purcaro, A. 2007. Trimetazidine Improves Endothelial Dysfunction In Chronic Heart Failure: An Antioxidant Effect. *European Heart Journal*, (28), 1102-1108.
- Burden, A. D. & Kirby, B. 2016. Psoriasis And Related Disorders. *Rook's Textbook of Dermatology*.
- Davidovici, B. B, Sattar, N., Jörg, P. C., Puig, L., Emery, P., Barker, J. N., Van De Kerkhof, P., Stähle, M., Nestle, F. O. & Girolomoni, G. 2010. Psoriasis And Systemic Inflammatory Diseases: Potential Mechanistic Links Between Skin Disease and Comorbid Conditions. *Journal Of Investigative Dermatology*, (130), 1785-1796.
- Di Napoli, P. 2008. Anti-Ischemic Cardioprotection with Trimetazidine. *Heart Metab*, (41), 25-29.
- Fanti, P., Dika, E., Vaccari, S., Miscial, C. & Varotti, C. 2006. Generalised Psoriasis Induced by Topical Treatment of Actinic Keratosis with Imiquimod. *International Journal of Dermatology*, (45), 1464-1465.
- Fragasso, G., Pm Piatti, M., Monti, L., Palloshi, A., Setola, E., Puccetti, P., Calori, G., Lopaschuk, G. & Margonato, A. 2003. Short-and Long-Term Beneficial Effects of Trimetazidine in Patients with Diabetes and Ischemic Cardiomyopathy. *American Heart Journal*, (146), 854.
- Gilliet, M., Conrad, C., Geiges, M., Cozzio, A., Thürliemann, W., Burg, G., Nestle, F. O. & Dummer, R. 2004. Psoriasis Triggered by Toll-Like Receptor 7 Agonist Imiquimod in The Presence of Dermal Plasmacytoid Dendritic Cell Precursors. *Archives Of Dermatology*, (140), 1490-1495.
- Griffiths, C. E. & Barker, J. N. 2007. Pathogenesis and Clinical Features of Psoriasis. *The Lancet*, .271-263,(370)
- Indrayan, A. & Malhotra, R. K. 2017. *Medical Biostatistics*, Chapman and Hall/Crc.
- Lebwohl, M., Dinehart, S., Whiting, D., Lee, P. K., Tawfik, N., Jorizzo, J., Lee, J. H. & Fox, T. L. 2004. Imiquimod 5% Cream for The Treatment of Actinic Keratosis: Results from Two Phase Iii, Randomized, Double-Blind, Parallel Group, Vehicle-Controlled Trials. *Journal of The American Academy Of Dermatology*, (50), 714-721.
- Lemster, B., Carroll, P., Rilo, H., Johnson, N., Nikaein, A. & Thomson, A. 1995. Il-8/Il-8 Receptor Expression In Psoriasis and The Response to Systemic Tacrolimus (Fk506) Therapy. *Clinical & Experimental Immunology*, (99), 148-154.
- Ni, C. & Chiu, M. W. 2014. Psoriasis And Comorbidities: Links and Risks. *Clinical, Cosmetic and Investigational Dermatology*, (7), 119.
- Nickoloff, B., Karabin, G., Barker, J., Griffiths, C., Sarma, V., Mitra, R., Elder, J., Kunkel, S. & Dixit, V. 1991. Cellular Localization of Interleukin-8 And Its Inducer, Tumor Necrosis Factor-Alpha in Psoriasis. *The American Journal of Pathology*, (138), 129.
- The organisation, W. H. 2016. *Global Report on Psoriasis*, World Health Organization.
- Pariser, D., Schenkel, B., Carter, C., Farahi, K., Brown, T. M., Ellis, C. N. & Group, P. P. I. S. 2016. A Multicenter, Non-Interventional Study to Evaluate Patient-Reported Experiences of Living with Psoriasis. *Journal Of Dermatological Treatment*, (27), 19-26.
- Rajan, N. & Langtry, J. 2006. Generalised Exacerbation Of Psoriasis Associated with Imiquimod Cream Treatment of Superficial Basal Cell Carcinomas. *Clinical And Experimental Dermatology*, (31), 140-141.
- Sagi, L. & Trau, H. 2011. The Koebner Phenomenon. *Clinics In Dermatology*, (29), 231-236.
- Schulz, B. S., Michel, G., Wagner, S., Süß, R., Beetz, A., Peter, R. U., Kemény, L. & Ruzicka, T. 1993. Increased Expression of Epidermal Il-8 Receptor in Psoriasis. Down-Regulation by Fk-506 In Vitro. *The Journal of Immunology*, (151), 4399-4406.
- Shear, N. H. 2006. Fulfilling An Unmet Need in Psoriasis. *Drug Safety*, (29), 49-66.
- Shehata, M. 2014. Cardioprotective Effects of Oral Trimetazidine in Diabetic Patients with Anterior Wall Myocardial Infarction Treated with Thrombolysis. *Cardiology Research*, (5), 58.
- Tsioufis, K., Andrikopoulos, G. & Manolis, A. 2015. Trimetazidine and Cardioprotection: Facts and Perspectives. *Angiology*, (66), 204-210.
- Van Der Fits, L., Mourits, S., Voerman, J. S., Kant, M., Boon, L., Laman, J. D., Cornelissen, F., Mus, A.-M.,

Florencia, E. & Prens, E. P. 2009. Imiquimod-Induced Psoriasis-Like Skin Inflammation in Mice Is Mediated Via the Il-23/Il-17 Axis. *The Journal of Immunology*, (182), 5836-5845.

Zou, L., Lonne-Rahm, S.-B., Helander, A., Stokkeland, K., Franck, J. & Nordlind, K. 2015. Alcohol Intake Measured by Phosphatidylethanol in Blood and The Lifetime Drinking History Interview are correlated with the Extent of Psoriasis. *Dermatology*, (230), 375-380.