



## Incidence of Cleft Lip and Cleft Palate - An Institutional Based Retrospective Study

Inchara R<sup>1</sup>, Archana Santhanam\*<sup>1</sup>, Subhashree R<sup>2</sup>

<sup>1</sup>Department of Oral Pathology, Saveetha Dental College and Hospitals, Saveetha Institute of Medical and Technical Sciences, Saveetha University, Chennai - 600077, Tamil Nadu, India

<sup>2</sup>Department of Prosthodontics, Saveetha Dental College and Hospitals, Saveetha Institute of Medical and Technical Sciences, Saveetha University, Chennai - 600077, Tamil Nadu, India

### Article History:

Received on: 14 Jul 2020  
Revised on: 16 Aug 2020  
Accepted on: 18 Aug 2020

### Keywords:

Cleft Lip,  
Cleft Palate,  
Orofacial Defect

### ABSTRACT

Cleft lip or the palate is the congenital birth defect with which is characterised by complete or partial cleft lip or palate. The congenital cleft involving the facial structures may vary from trace of notching of the lip to a complete non fusion of lip and the palate. This study was done to determine the incidence of cleft lip and palate. It is a single centered retrospective study. Data was collected from the patient record system used in a private dental institution and following parameters such as gender, type of cleft lip and palate, unilateral or bilateral was recorded. 86000 patient details were analysed between June 2019 to March 2020 out of which 74 patients who fulfilled the inclusion and exclusion criteria were included in the study. The data was statistically analysed using SPSS software. In this study, it was observed that cleft lip was most commonly seen in males and cleft palate in females. Unilateral cleft lip is common in both males and females. Incomplete cleft palate is more common followed by complete cleft palate. Orofacial defects are most commonly seen at the time of birth.



### \*Corresponding Author

Name: Archana Santhanam  
Phone:  
Email: drarch.s@gmail.com

ISSN: 0975-7538

DOI: <https://doi.org/10.26452/ijrps.v11iSPL3.3407>

Production and Hosted by

IJRPS | <https://ijrps.com>

© 2020 | All rights reserved.

[sha and Brundha, 2017](#)). Cleft lip and palate (CL/P) are one of the most common congenital malformations ([Sruthi and Sivakumar, 2018](#)). Nutrition plays a role in the formation of teeth and bones for mastication. ([Sivaramakrishnan and Ramani, 2015](#)). Reducing the incidence of developmental abnormalities could result in significant public health benefit ([Venkatesan and Rajesh, 2003](#)). The incidence of orofacial defects has increased in the past two decades ([Gheena and Ezhilarasan, 2019](#)). It is therefore important to identify patients who are at higher risk of developing orofacial defects ([Viveka et al., 2016](#)).

### INTRODUCTION

The word 'cleft' means split or fissured. Cleft lip and palate (CL/P) can occur in isolation or in combination as syndromes due to chromosomal aberrations ([Pujari et al., 2018](#)). The term developmental disturbances refers to an abnormality that occurs in the early stage of intrauterine life ([Har-](#)

[sha et al., 2019](#)). Occlusal complications are common in children with CL and CP. Parents are often negligent about dental health in patients with orofacial defects ([Nagappan and John, 2015](#); [Gupta and Ramani, 2016](#)). A cleft lip can be median or paramedian cleft and may or may not involve the palate ([Baskar, 2014](#); [Nagappan et al., 2019](#)).

Cleft lip and palate are also associated with some syndromes but knowledge on genetic factors leading to such conditions is minimal (Baskar, 2014). Till date, there are no established biomarkers to identify the pregnant mothers who are at higher risk (Thangaraj et al., 2016). Number of factors such as infection, toxicity, poor diet, hormonal imbalance, and genetic interferences that affect the mother in the first trimester of pregnancy can lead to development of cleft lip and palate. Interactions between epithelial cells and the connective tissue play a major role in many biological processes (Jayaraj et al., 2015b). Orofacial defects are easy to diagnose as it causes obvious changes in the facial appearance (Sivanagini et al., 2018; Sherlin et al., 2015).

Management of cleft patients is approached as teamwork and treatment is being split depending on their age group (Missier et al., 2019). Despite the advances in the field of diagnostic and therapeutics, the disorder remains a challenge for medical professionals (Sridharan et al., 2019). The treatment goals for any kind of orofacial defects are normalized facial esthetics, speech, hearing and airway patency. Early detection and prompt diagnosis can lead to better prognosis and help in the implementation of successful clinical treatment (Sridharan et al., 2017; Shree et al., 2019; Hannah et al., 2018). Accurate histopathological assessment is very crucial in order to develop an effective treatment plan (Jayaraj et al., 2015a). A variation in the study population is also a factor that has to be taken into consideration (Jayaraj et al., 2015c; Swathy et al., 2015). This study aims at determining the incidence of cleft lip and palate in private Dental Institution, Chennai from June 2019 to March 2020.

## MATERIALS AND METHODS

It is a single centered retrospective study conducted in a private dental institution, Chennai. The data was collected from the dental hospital management system. 86000 patient details were analysed between June 2019 to March 2020 out of which 74 patients who fulfilled the inclusion and exclusion criteria were included in the study. Subjects were divided into 2 groups, group 1: subjects with cleft lip, group 2: subjects with cleft palate. Ethical clearance for this study was obtained from the Institutional review board.

The data included a varied population predominantly South Indian. All the details of the patients from June 2019 to March 2020 were collected. All the case sheets were reviewed and were cross verified by another examiner. The internal validity included diagnosed cases as per criteria, medical

history, chief complaints and clinical findings.

The data collected were tabulated under following parameters: Age, gender, types of cleft lip and palate. The independent variable includes age, gender and dependent variables includes type of CLP and associated anomalies. The data analysis was performed using SPSS software of version 19. The chi-square test and Pearson correlation were done.  $p$ -value  $< 0.005$  was considered statistically significant.

## RESULTS AND DISCUSSION

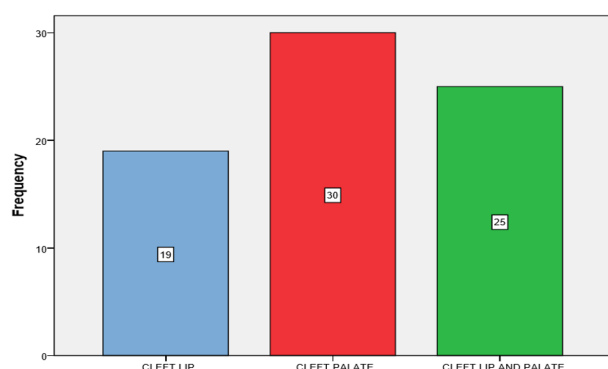
Among the 74 patients, 19 patients had cleft lip and 30 patients with cleft palate in which 25 patients had both cleft lip associated with cleft palate. Also, among 74 patients, 11 patients with cleft lip and 8 patients with cleft palate under the age group of 0-1 year, followed by 1 patient between 2-3 years cleft lip and 4 patients with cleft palate. Between 4-10 years of age, 4 patients had cleft lip and 13 patients had cleft palate. And under 11-20 years of age group there were 3 patients with cleft lip and 5 patients with cleft palate (Figure 1)

In a study conducted by Srinivas gosla reddy et al., males are commonly affected (65%) in all the districts. Incidence of oral-facial clefting shows ethnic variation (Reddy et al., 2010). In the study done by Chan KW, 2013 out of all the children studied, boys were more commonly affected with CL (66%) while CP was more common in girls (62%). The study by Gulnaz et al. (2017) an overall higher frequency of isolated cleft lip was seen in males than in females with a higher incidence of unilateral cleft lip in males compared to a higher incidence of bilateral cleft lip in females. This is mainly due to differences between hormones and developmental stages and also due to genetic differences between males and females. A difference between male and female incidence can be due to the smaller sample size for this region.

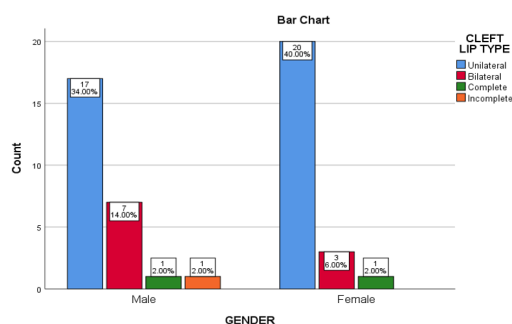
In correlation between gender and type of cleft lip, in this study the results showed that males (52%) were most commonly affected with cleft lip compared to females. The unilateral cleft lip (74%) was more common among both males and females (Figure 2). The chi-square value was 0.124 which is statistically not significant. Literature supports that 30.2% of the CLP group had bilateral cleft and 69.8% had unilateral cleft (Yilmaz et al., 2019). This is because the cleft lip deformity is characterised by tissue deficiency and attach structures to either side of the cleft.

In correlation between gender and type of cleft

palate, cleft palate is most common in females (52%) compared to males. The complete cleft palate was most common among females and incomplete cleft palate (37.5%) was most common in males (Figure 3). The chi-square value was 0.452 which is not significant. In the study done by Gatti *et al.* (2017), the most common cleft type was incomplete cleft palate (152 patients) (Gatti *et al.*, 2017). Medical neglect and medical non-adherence are the main reasons for the development of cleft palate (Konda *et al.*, 2018). Possibilities may include small size of palatal shelves, unsuccessful elevation of shelves, defective process of fusion and inability of the tongue to descend in between the shelves (Gulnaz *et al.*, 2017).



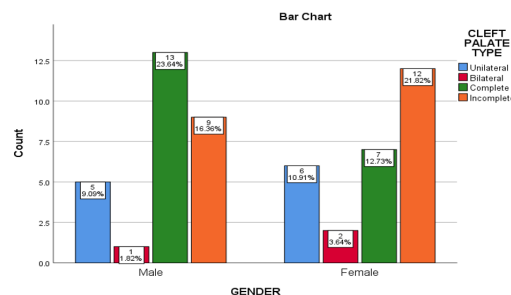
**Figure 1: Bar graph depicting the prevalence pattern of cleft lip and cleft palate**



**Figure 2: Bar graph depicting association between gender and cleft lip type with P-value =0.124>0.05 statistically not significant**

The prime concerns of the patients with cleft are difficulty in speech, swallowing, suckling and also poor oral hygiene leading to embarrassment in social groups (Jangid *et al.*, 2015). The pregnant mothers with a habit of smoking, alcohol abuse, and patients not taking folic acid and multivitamins are at high risk of developing congenital defects (Angulo-Castro *et al.*, 2017). Pregnant mothers with a history of cleft should consult with genetic counsellors to assess the risk factors (Kawalec *et al.*, 2015).

The limitations of the study includes, it is a single



**Figure 3: Bar graph depicting association between gender and cleft palate type with P value =0.452 > 0.05 statistically not significant**

centered study with a small population and does not include information about consanguineous marriage, genetic disorder, prenatal problems and does not include any ethnic groups, races.

The future scope of the study includes it can be used for further studies with a higher population. Awareness must be created among the individuals and pregnant women about the problems associated with it.

## CONCLUSION

Congenital developmental defects involving the face is one of the major concerns in India due to the limited resources that are available to treat patients with cleft. Thus, it can be concluded that in the sample of patients in this study, the treatment needs very significant importance and awareness on health problems associated with consanguineous marriage, problems associated with orofacial defects for clefts should be created among individuals as prevention is better than cure.

## ACKNOWLEDGEMENTS

The authors would like to thank the study participants for their participation and kind cooperation throughout the study.

## Funding Support

The authors declare that they have no funding support for this study.

## Conflict of Interest

The authors declare that there is no conflict of interest for this study.

## REFERENCES

Angulo-Castro, E., *et al.* 2017. Maternal Risk Factors Associated with the Development of Cleft Lip and Cleft Palate in Mexico: A Case-Control Study. *Ira-*

- nian journal of otorhinolaryngology, 29(93):189-195.
- Baskar, S. 2014. Prevalence of Orofacial Defects Due to Familial Aggregation, at Tertiary Care Centre in Chennai-A Cross Sectional Study. *Journal of Medical Science And Clinical Research*, 2(6):1428-1437.
- Gatti, G. L., Freda, N., Giacomina, A., Montemagni, M., Sisti, A. 2017. Cleft Lip and Palate Repair. *Journal of Craniofacial Surgery*, 28(8):1918-1924.
- Gheena, S., Ezhilarasan, D. 2019. Syringic acid triggers reactive oxygen species-mediated cytotoxicity in HepG2 cells. *Human & Experimental Toxicology*, 38(6):694-702.
- Gulnaz, H., Majeed, N., Ijaz, S. 2017. Patterns of Orofacial Clefts in Patients with Consanguineous Parents. *Pakistan Journal of Medical & Health Sciences*, 11(2):791-794.
- Gupta, V., Ramani, P. 2016. Histologic and immunohistochemical evaluation of mirror image biopsies in oral squamous cell carcinoma. *Journal of Oral Biology and Craniofacial Research*, 6(3):194-197.
- Hannah, R., Ramani, P., Sherlin, H. J., Ranjith, G., Ramasubramanian, A., Jayaraj, G., Don, K. R., Archana, S. 2018. Awareness about the use, Ethics and Scope of Dental Photography among Undergraduate Dental Students Dentist Behind the lens. *Research Journal of Pharmacy and Technology*, 11(3):1012.
- Harsha, L., Brundha, M. P. 2017. Prevalence of dental developmental anomalies among men and women and its psychological effect in a given population. *Journal of Pharmaceutical Sciences and Research*, 9(6):869.
- Jangid, K., Alexander, A., Jayakumar, N., Varghese, S., Ramani, P. 2015. Ankyloglossia with cleft lip: A rare case report. *Journal of Indian Society of Periodontology*, 19(6):690.
- Jayaraj, G., Ramani, P., Sherlin, H. J., Premkumar, P., Anuja, N. 2015a. Inter-observer agreement in grading oral epithelial dysplasia - A systematic review. *Journal of Oral and Maxillofacial Surgery, Medicine, and Pathology*, 27(1):112-116.
- Jayaraj, G., Sherlin, H., Ramani, P., Premkumar, P., Anuja, N. 2015b. Cytomegalovirus and Mucoepithelioid carcinoma: A possible causal relationship? A pilot study. *Journal of Oral and Maxillofacial Pathology*, 19(3):319.
- Jayaraj, G., Sherlin, H. J., Ramani, P., Premkumar, P., Natesan, A. 2015c. Stromal myofibroblasts in oral squamous cell carcinoma and potentially malignant disorders. *Indian Journal of Cancer*, 52(1):87.
- Kawalec, A., Nelke, K., Pawlas, K., Gerber, H. 2015. Risk factors involved in orofacial cleft predisposition - review. *Open Medicine*, 10(1):10.
- Konda, S. R., Mohapatra, D. P., Babu, P. 2018. Incomplete cleft palate in a child with De Barsy syndrome. *Journal of Cleft Lip Palate and Craniofacial Anomalies*, 5(1):56.
- Missier, M. S., Jain, R. K., Kumar, M. P. 2019. Nasoalveolar molding and their effects on the dentoalveolar arch: A systematic review. *Drug Invention Today*, 11(1).
- Nagappan, N., John, J. 2015. Oral hygiene and dental caries status among patients with cleft lip, cleft palate and cleft lip, alveolus and palate in Chennai, India. *Journal of Cleft Lip Palate and Craniofacial Anomalies*, 2(1):49.
- Nagappan, N., Madhanmohan, R., Gopinathan, N., Stephen, S., Pillai, D. M., Tirupati, N. 2019. Oral health-related quality of life and dental caries status in children with orofacial cleft: An Indian outlook. *Journal of Pharmacy And Bioallied Sciences*, 11(6):169.
- Pujari, D., Charmode, S., Hs, K. 2018. The Study of Cleft Lip And Palate In North Karnataka Region. *International Journal of Anatomy and Research*, 6(4.3):6014-6017.
- Reddy, S. G., Reddy, R. R., Bronkhorst, E. M., Prasad, R., Ettema, A. M., Sailer, H. F., Bergé, S. J. 2010. Incidence of cleft Lip and palate in the state of Andhra Pradesh, South India. *Indian Journal of Plastic Surgery*, 43(2):184.
- Sherlin, H., Ramani, P., Premkumar, P., Kumar, A., Natesan, A. 2015. Expression of CD 68, CD 45 and human leukocyte antigen-DR in central and peripheral giant cell granuloma, giant cell tumor of long bones, and tuberculous granuloma: An immunohistochemical study. *Indian Journal of Dental Research*, 26(3):295.
- Shree, K. H., Ramani, P., Sherlin, H., Sukumaran, G., Jeyaraj, G., Don, K. R., Santhanam, A., Ramasubramanian, A., Sundar, R. 2019. Saliva as a Diagnostic Tool in Oral Squamous Cell Carcinoma - a Systematic Review with Meta Analysis. *Pathology and Oncology Research*, 25(2):447-453.
- Sivanagini, Y., Ganapathy, D., Jain, A. R. 2018. Anxiety levels among mothers with cleft palate children receiving feeding plate obturators. *Drug Invention Today*, 10(10):1986-1991.
- Sivaramakrishnan, S. M., Ramani, P. 2015. Study on the Prevalence of Eruption Status of Third Molars in South Indian Population. *Biology and Medicine*, 07(04).
- Sridharan, G., Ramani, P., Patankar, S. 2017. Serum metabolomics in oral leukoplakia and oral squa-

- mous cell carcinoma. *Journal of Cancer Research and Therapeutics*, 13(3):556.
- Sridharan, G., Ramani, P., Patankar, S., Vijayaraghavan, R. 2019. Evaluation of salivary metabolomics in oral leukoplakia and oral squamous cell carcinoma. *Journal of Oral Pathology & Medicine*, 48(4):299-306.
- Sruthi, S., Sivakumar, A. 2018. Knowledge, awareness, and attitude on cleft lip and palate management among dental students. *Drug invention today*, 10.
- Swathy, S., Gheena, S., Varsha, S. L. 2015. Prevalence of pulp stones in patients with history of cardiac diseases. *Research Journal of Pharmacy and Technology*, 8(12):1625.
- Thangaraj, S. V., Shyamsundar, V., Krishnamurthy, A., Ramani, P., Ganesan, K., Muthuswami, M., Ramshankar, V. 2016. Molecular Portrait of Oral Tongue Squamous Cell Carcinoma Shown by Integrative Meta-Analysis of Expression Profiles with Validations. *PLOS ONE*, 11(6):e0156582.
- Venkatesan, A., Rajesh, P. 2003. Epidemiology of cleft lip and cleft palate in south Indian population. *Journal of Indian Association of Public Health Dentistry*, 3(3):6.
- Viveka, T. S., Shyamsundar, V., Krishnamurthy, A., Ramani, P., Ramshankar, V. 2016. p53 Expression Helps Identify High Risk Oral Tongue Premalignant Lesions and Correlates with Patterns of Invasive Tumour Front and Tumour Depth in Oral Tongue Squamous Cell Carcinoma Cases. *Asian Pacific Journal of Cancer Prevention*, 17(1):189-195.
- Yilmaz, H. N., Özbilen, E., Üstün, T. 2019. The prevalence of cleft lip and palate patients: A single-center experience for 17 years. *Turkish Journal of Orthodontics*, 32(3):139-144.