



Prevalence of Non-tobacco Associated Tongue Squamous Cell Carcinoma - Retrospective Study

Ushanthika T¹, Herald J Sherlin^{*2}, Sivakumar M³

¹Saveetha dental college and hospital, Saveetha Institute of Medical and Technical Sciences, Chennai-600077, Tamil Nadu, India

²Department of Oral pathology, Saveetha dental college and hospital, Saveetha Institute of Medical and Technical Sciences, Chennai-600077, Tamil Nadu, India

³Department of Oral and Maxillofacial surgery, Saveetha dental college and hospital, Saveetha Institute of Medical and Technical Sciences, Chennai-600077, Tamil Nadu, India

Article History:

Received on: 01 Sep 2020

Revised on: 01 Oct 2020

Accepted on: 06 Oct 2020

Keywords:

Tongue,
dental factors,
OSCC

ABSTRACT

OTSCC is the most occurring cancer diagnosed in the oral cavity worldwide. There has been a rise in the occurrence of carcinoma of the tongue, especially among non-alcohol and non-tobacco users. The aim of the study is to assess the prevalence of non tobacco tongue OSCC and to correlate with the dental factors. The retrospective analysis data was collected from the dental hospital management system records of Saveetha dental college in OSCC patients without any habits from June 2019 to March 2020. The Clinical details, history and dental factors were tabulated and analysed using statistical software SPSS. Fifteen cases of OTSCC were found to be not associated with any tobacco or alcohol habits. The most prevalent age was from 51 to 60 years and more common in males. The most common site was the lateral border of the tongue. 73% of the patients were not associated with any dental factor and the most common histopathological grade was WDSCC 66%. 60% of the patients had been diagnosed with stage III OTSCC. Within the limits of this study, there is a high prevalence of WDSCC in tongue OSCC in the lateral border of tongue in male between the age group of 51-60 years commonly in males. There was not much association seen with dental factors. The present study underlines the importance of in depth analysis of other etiological factors in OTSCC, thereby facilitating a better understanding of the biology and progression.



*Corresponding Author

Name: Herald J Sherlin

Phone:

Email: sherlin@saveetha.com

ISSN: 0975-7538

DOI: <https://doi.org/10.26452/ijrps.v11iSPL3.3376>

Production and Hosted by

IJRPS | <https://ijrps.com>

© 2020 | All rights reserved.

INTRODUCTION

Oral squamous cell carcinoma stands as the sixth most common cancer present in the world (Warakulasuriya, 2009). Oral Squamous Cell Carcinoma (OSCC) is a major health problem worldwide, especially in the developing countries (Jayaraj et al., 2015c). In India, oral cancer is one of the most prevalent cancers and continues to be a significant general health issue. Oral Tongue Squamous cell carcinoma (OTSCC), the most commonly affected oral malignant growth sub-site, is related with a poor therapeutic result and outcome and survival despite aggressive multi modality management (Viveka et al., 2016).

The age adjusted incidence rate (AAR) for carcinoma tongue has expanded from 3.6 to 5.7 per 100,000 people over the over 25 years (Thangaraj *et al.*, 2016). OTSCC has been accounted for to be among the main two most common subsites among the oral cavity cancers across numerous reports in India. The carcinoma of the tongue constitutes twenty percent to fifty percent of all instances of oral squamous cell carcinoma (OSCC) (Dantas *et al.*, 2003), with the anterior two thirds and the lateral borders usually being the most affected areas.

Regardless of the way that the consolidated impacts of tobacco and alcohol consumption may expand the risk of developing carcinoma, there are etiologies that play a significant role in the development of carcinoma in patients without a background of drinking and smoking. Despite the fact that it's not totally clarified, several factors have been known to cause human papilloma infection (HPV), diet and hereditary variables for this particular group (Sturgis *et al.*, 2004).

Also other factors like oral epithelial dysplasia it's not uncommon for a mild dysplasia to rapidly progress to an invasive carcinoma like OSCC (Jayaraj *et al.*, 2015a; Jangid *et al.*, 2015). Also, other factors like oral epithelial dysplasia it's not uncommon for a mild dysplasia to rapidly progress to an invasive carcinoma like OSCC. Latest researches have exhibited that in patients not presented to smoking and drinking the lesions are prone to be classified as well or moderately differentiated, while in people exposed to smoking and drinking, a lower level of cell differentiation has been observed (Kruse *et al.*, 2010). As indicated by an investigation done in an oncology department in Chennai greater part of the OTSCC (85%) in patients without any habits are seen in advanced stages (Stages III and IV). Moreover early tongue cancers (Stages I and II) establish about 45% of all OTSCC's (Krishnamurthy and Ramshankar, 2013).

In oral cancer the role of saliva is used as a diagnostic tool in detecting Oral Squamous Cell Carcinoma (Shree *et al.*, 2019). Investigation of salivary metabolomics may help in recognizing tumor-specific biomarkers for early diagnosis and forecast of tumor progression (Sridharan *et al.*, 2019). Photography stands as one of the best ways to gather and save evidence of extra oral and intra oral pictures which helps in instructing, treatment and development (Hannah *et al.*, 2018). Immunohistochemistry can be utilized for a better analysis and understanding (Sherlin *et al.*, 2015; Swathy *et al.*, 2015). A biopsy is done comparable to the histopathological changes in the oral mucosa among

oral cancer patients utilizing hematoxylin and eosin and to the expression pattern of cytokeratin might be valuable in foreseeing epithelial separation in oral squamous cell carcinoma and mirror image biopsy (Gupta and Ramani, 2016).

There are many studies going on Syringic acid (SA) for its hepatoprotective, anti-inflammatory, free radical scavenging, and antioxidant activities. It is also said to have anti-carcinogenic properties and several studies have been going on to use it in OSCC and hepatocellular carcinoma (Gheena and Ezhilarasan, 2019). The early diagnosis and analysis of OSCC can lead to better prognosis and help in the execution of successful clinical treatment (Sridharan *et al.*, 2017). However, surgery remains the best option for these patients unless proven otherwise (Jayaraj *et al.*, 2015b). Most of the epidemiological studies have majorly focused on oral cancer as a whole, but however there are very few studies that have explicitly looked into OTSCC. The aim of the study was to assess the prevalence of non tobacco tongue OSCC and to correlate with the dental factors.

MATERIALS AND METHODS

It is a single centred retrospective study in a private dental institution. We took patients who were clinically diagnosed as non-tobacco tongue OSCC who checked in from June 2019 to March 2020.

Inclusion criteria - histopathologically confirmed cases of squamous cell carcinoma of tongue not associated with any habits are taken.

Exclusion criteria - patients with tobacco habits and patients with carcinoma other than OSCC

Ethical clearance for this study was obtained from the institutional review board.

Data from 86000 patients visiting Saveetha dental college and Hospital were reviewed, and data was collected. The patients list was identified and the patients with non-tobacco tongue OSCC was taken and the case sheet was reviewed. It was cross-verified by another examiner and using histopathology reports. Internal validity measures taken were Clinical, HP criteria, Habits and Control of confounders. The records of all patient data, biopsy details, histopathology, dental factors were taken.

The data was entered in the excel sheet and was imported to SPSS and the analysis was done using SPSS software version 19 by IBM. The Chi-square test was performed to compare the proportions between the parameters and p-value level of significance set at 0.05.

RESULTS AND DISCUSSION

As a result of our study we found 15 patients associated with non tobacco tongue OSCC. Out of which 60% of the patients were from age group 51 to 60 years. Hence, the most prevalent was in the age group 51 to 60 years of age among non tobacco tongue OSCC patients in Table 1.

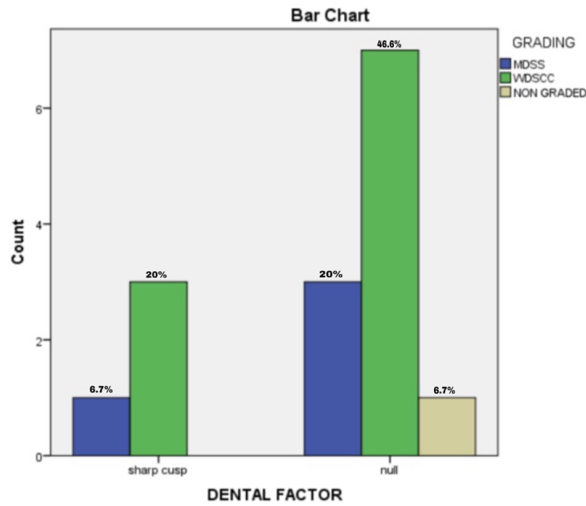


Figure 1: Bar chart representing the association between dental factors and grade of OSCC.

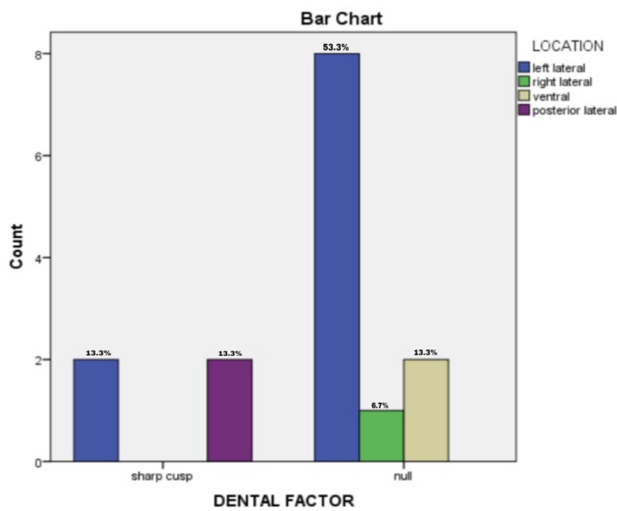


Figure 2: Bar chart representing the association between dental factors and site of Tongue SCC. X-axis denotes dental factors, y-axis represents frequency.

The present study findings coincides with the study findings by Arvind (Krishnamurthy and Ramshankar, 2013) where the mean age reported was 53.4 years and majority of patients were in the age group of 51-70 years. This is in agreement with many other Indian studies show that the peak-age frequency of occurrence of oral cancers (including OTSCCs) in India is in the fifth decade, at least a

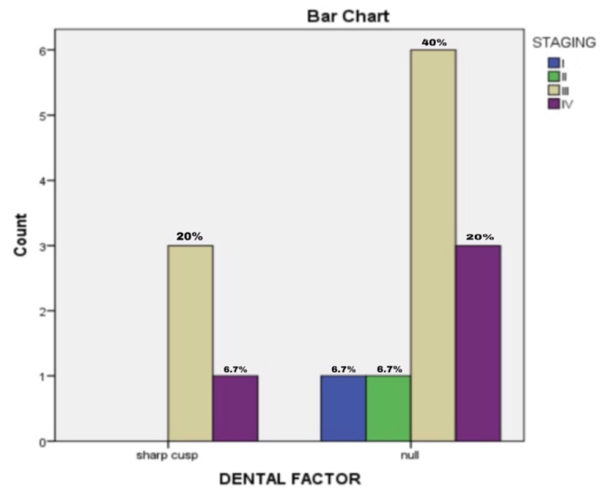


Figure 3: Bar chart representing the association between dental factors and staging of Tongue SCC.

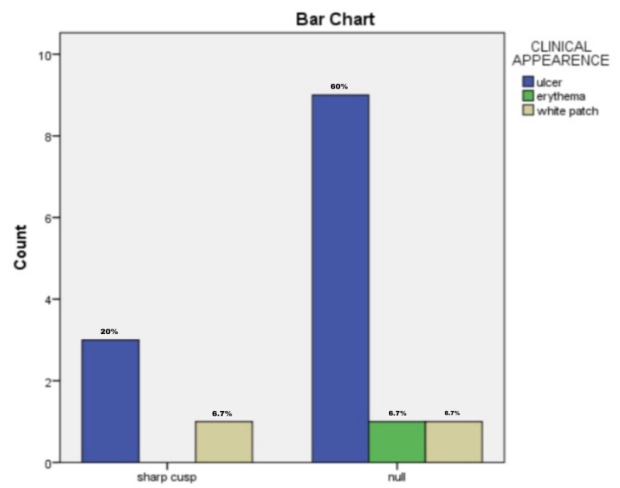


Figure 4: Bar chart representing the association between dental factors and clinical appearance of Tongue SCC.

Table 1: Frequency distribution of different age group in OTSCC patients

Age group	Frequency	Percentage
31 to 40 years	1	6.7
41 to 50 years	3	20.0
51 to 60 years	9	60.0
61 to 70 years	2	13.0
Total	15	100.0

Table 2: Frequency distribution of the gender in OTSCC patients

Gender	Frequency	Percentage
Male	11	72.3
Female	4	26.7
Total	15	100.0

Table 3: Frequency distribution of symptoms presented by OTSCC patients

Location	Frequency	Percentage
Left lateral Border	8	53.3
Right lateral Border	2	13.3
Ventral Border	5	33.3
Total	15	100.0

Table 4: Frequency distribution of the location of lesion presented by OTSCC patients

Location	Frequency	Percentage
Left lateral Border	10	66.7
Right lateral Border	1	6.7
Ventral Border	2	13.3
Posterior lateral Border	2	13.3
Total	15	100.0

Table 5: Frequency distribution of dental factors presented by OTSCC patients

Dental Factor	Frequency	Percentage
Sharp cusp	4	26.7
No dental factors	11	73.3
Total	15	100.0

Table 6: Frequency distribution of the clinical appearance of lesions presented by OTSCC patients.

Clinical appearance	Frequency	Percentage
Ulcer	12	80.0
Erythema	1	6.7
White patch	2	13.3
Total	15	100.0

Table 7: Frequency distribution of the staging in OTSCC patients

Staging	Frequency	Percentage
Stage I	1	6.7
Stage II	1	6.7
Stage III	9	60.0
Stage IV	4	26.7
Total	15	100.0

Table 8: Frequency distribution of histopathological grading in OTSCC patients

Grading	Frequency	Percentage
MDSCC	4	26.7
WDSCC	10	66.7
Not graded	1	6.7
Total	15	100.0

decade earlier than that described in the western literature (Gupta *et al.*, 2008; Iype *et al.*, 2001).

Among the 15 patients 73.3% of them were males and 26.7 % of them were females. The males predilection was higher in non tobacco tongue OSCC patients in Table 2. The males predilection was higher in non-tobacco tongue OSCC patients in this study which correlated with Krishnamurthy and Ramshankar (2013). Where the male to female ratio was 3:1. Though the collective effects of tobacco and alcohol consumption may increase the risk of developing carcinoma yet, few factors such as HPV, diet, and genetic factors also play an important role in the development of carcinoma in patients without a history of drinking and smoking (Dahlstrom *et al.*, 2008). HPV is the most common sexually transmitted infection. Many people are exposed to oral HPV in their life. About 10% of men and 3.6% of women have oral HPV, and oral HPV infection is more common with older age. Most people clear HPV within one to two years, but HPV infection persists in some people. The relationship between diet and nutrition to the risk of cancer development has been established by several epidemiological and laboratory studies (Jeng *et al.*, 2001) [Table 3].

The obtained results showed that most patients presented with pain, as shown in graph 3. The various locations seen among the 15 patients were 72% presented in the left and right lateral border of the tongue, 13.3 % of the patients presented in the ventral border of the tongue and 13.3 % posterior lateral border of the tongue. The most prevalent site was seen in the anterior lateral border of the tongue in Table 4. The present study findings correlated with Albuquerque *et al.* study (Albuquerque *et al.*, 2011) which states that the lateral borders of the tongue were the most frequent carcinoma locations in both habits and non-habit groups with 59.7% and 40.3% respectively. Falaki *et al.* (2011) analyzed 158 cases of OSCC and found that the most common site of involvement was the tongue (66%) and lateral border of the tongue.

Out of 15 patients 73.3 % of the patients were not associated with any dental factors only 26.6 %

of patients presented with Sharp cups in Table 5. In this study most patients were not associated with any dental factors. According to the study by Chaturvedi *et al.* (2017) there is not enough available evidence which appears to be significant enough to support sharp teeth to be a risk factor in causing oral cancer. Many times, during the examination of oral cancer patients, we come across a sharp tooth at corresponding location on the alveolar arch. However, over review of literature, we could not find any study which has separately looked at association between sharp tooth and oral cancer.

In the present study, we found that 80% of the patients presented with ulcerative lesions which correlated to other studies which found the same [Table 6]. According to Wahi *et al.* (1965) most tumors of the oral cavity ulcerate, this could be due to the friction of the mucous membrane during eating.

In grading of OTSCC 66.7 % were WDSCC and 26.7% were MDSCC. The most commonly seen grading was WDSCC in patients with non tobacco tongue OSCC in Table 8. Considering the histological grading of tongue OSCC most patients in the present study had well differentiated squamous cell carcinoma (66%) followed by MDSCC (27%). Which correlated to Selvamani *et al.* (2015) and Lawal *et al.* who found that well-differentiated OSCC accounted for 23 cases (44.2%), while moderately differentiated OSCC was seen in 29 cases (55.8%) and Agarwal *et al.* (2011) found 10 cases (55.5%) of well-differentiated OSCC and 4 cases (22.2%) of moderately differentiated OSCC in his analysis. The phenotype of non-habit associated OSCC is generally well to moderately differentiated carcinoma. Comparative analysis of the expression of p53 inhabit and non-habit associated with OSCC show a significant decrease in expression in the latter. This could explain why the non-habit associated OTSCC patients with well differentiated squamous cell carcinoma shows a good response to radiotherapy and thus an improved overall prognosis (Rapidis *et al.*, 1977).

The Staging of OTSCC observed in this study was stage III, which was found in 60% of the patients in Table 7. The most prevalent staging was stage III, which was 60% in this study which coincided with a similar finding by Karlo Mario Carvalho *et al* where most cases were seen was above stage III. Also relevant to the study by Arvind Krishnamurthy (Krishnamurthy and Ramshankar, 2013) majority of the oral cavity cancers (85%) in the cancer center was present in advanced stages (Stages III and IV), on the contrary early tongue cancers (Stages I and II) constitute nearly 45% of all OTSCCs. This shows

the lack of awareness and reluctance for early medical attention in the population. The current recommendations to screen for oral cancer at every routine check-up is not practical and has not produced the intended results (Sivaramakrishnan and Ramani, 2015). Selective opportunistic screening may be a more realistic and effective solution. Detection of oral and oropharyngeal SCCs during a non-symptom-driven examination has proved an association to lower stage at diagnosis, in the same way as patients with a regular primary care dentist are significantly more likely to be diagnosed at early stages

The obtained results were compared using Chi-square test. Age and diagnosis are compared and the p-value obtained was statistically significant ($p < 0.05$). Dental factor and age are compared and the p-value obtained was statistically significant ($p < 0.05$) [Figures 1, 2, 3 and 4].

Figure 1 X-axis denotes dental factors, y-axis represents frequency. Green colour represents Well differentiated squamous cell carcinoma, Blue colour represents Moderately differentiated squamous cell carcinoma, Beige colour represents Squamous cell carcinoma not graded. Well differentiated SCC was the most common grade (46.6%) among patients with no dental factors, but there was no significant relationship between dental factors and grade of the tumour. Pearson Chi-square $p = 0.808$

Figure 2 Blue denotes left lateral border of tongue, green denotes right lateral border of tongue, Beige ventral surface of the tongue, purple denotes posterolateral tongue. Left lateral border of the tongue was the most common site of involvement in patients with no associated dental factors. There was no significance between dental factors and the site of Tongue SCC. Pearson Chi-square $p = 0.078$

Figure 3 X-axis- denotes dental factors, Y-axis represents frequency. Blue denotes Stage I, Green denotes stage II, beige denotes Stage III, Purple denotes Stage IV. Most of the Tongue SCC patients were in Stage III and not associated with dental factors. There was no significance between dental factors and staging of Tongue SCC. Pearson Chi-square $p = 0.816$

Figure 4 X-axis- denotes dental factors, Y-axis represents frequency of clinical appearance. Blue denotes ulcerated appearance, Green denotes erythematous presentation, Beige represents leukoplakia or white patch. There was no significant association between dental factors and clinical appearance of Tongue SCC. Pearson Chi-square $p = 0.626$

The information obtained from the current study will help clinicians better understand the etiology

and biology of OTSCC and can also potentially aid the policy makers to channelise the resources better for effective public health interventions. Limitation the study was done in a short duration. It was a short cross-sectional study of a particular population and other etiological factors were not assessed. The future scope of the study is based on a larger population and assessment of more etiological factors can be done. A long term study incorporating advanced pathological methods can give a better outcome. This information will help clinicians better understand the etiology and biology of OTSCC.

CONCLUSION

The present study highlights the clinical and histopathological characteristics of OTSCC which are not associated with habits. The study also emphasizes the need for identification of the proper etiological factors, which plays a pivotal role in prevention. Early detection and prevention of this particular type of oral cancer help in the institution of proper treatment, thereby improving the quality and quantity of life of the patients.

Conflict of interest

The authors declare that they have no conflict of interest for this study.

Funding support

The authors declare that they have no funding support for this study.

REFERENCES

- Agarwal, A. K., Sethi, A., Sareen, D., Dhingra, S. 2011. Oral and Oropharyngeal Squamous Cell Carcinoma in Our Population: The Clinic-Pathological and Morphological Description of 153 Cases. *International Journal of Morphology*, 29(3):686–693.
- Albuquerque, R., López-López, J., Marí-Roig, A., Jané-Salas, E., Roselló-Llabrés, X., Santos, J. R. 2011. Oral tongue squamous cell carcinoma (OTSCC): alcohol and tobacco consumption versus non-consumption. A study in a Portuguese population. *Brazilian Dental Journal*, 22(6):517–521.
- Chaturvedi, P., Singhvi, H., Malik, A. 2017. The role of chronic mucosal trauma in oral cancer: A review of literature. *Indian Journal of Medical and Paediatric Oncology*, 38(1):44.
- Dahlstrom, K. R., Little, J. A., Zafereo, M. E., Lung, M., Wei, Q., Sturgis, E. M. 2008. Squamous cell carcinoma of the head and neck in never smoker–never drinkers: A descriptive epidemiologic study. *Head and Neck*, 30(1):75–84.
- Dantas, D. D. L., Ramos, C. C. F., Costa, A., De, L. L., Souza, L. B., De, Pinto, L. P. 2003. Clinical-pathological parameters in squamous cell carcinoma of the tongue. *Brazilian Dental Journal*, 14(1):22–25.
- Falaki, F., Dalirsani, Z., Pakfetrat, A., Falaki, A., Saghravanian, N., Nosratzahi, T., Pazouki, M. 2011. Clinical and histopathological analysis of oral Squamous cell carcinoma of young patients in Mashhad, Iran: A retrospective study and review of literature. *Medicina Oral Patología Oral y Cirugía Bucal*, 16(4):e473–e477.
- Gheena, S., Ezhilarasan, D. 2019. Syringic acid triggers reactive oxygen species–mediated cytotoxicity in HepG2 cells. *Human and Experimental Toxicology*, 38(6):694–702.
- Gupta, P. C., Murti, P. R., Bhonsle, R. B., Mehta, F. S., Pindborg, J. J. 2008. Effect of cessation of tobacco use on the incidence of oral mucosal lesions in a 10-yr follow-up study of 12 212 users. *Oral Diseases*, 1(1):54–58.
- Gupta, V., Ramani, P. 2016. Histologic and immunohistochemical evaluation of mirror image biopsies in oral squamous cell carcinoma. *Journal of Oral Biology and Craniofacial Research*, 6(3):194–197.
- Hannah, R., Ramani, P., Sherlin, H. J., Ranjith, G., Ramasubramanian, A., Jayaraj, G., Don, K. R., Archana, S. 2018. Awareness about the use, Ethics and Scope of Dental Photography among Undergraduate Dental Students Dentist Behind the lens. *Research Journal of Pharmacy and Technology*, 11(3):1012.
- Iype, E. M., Pandey, M., Mathew, A., Thomas, G., Sebastian, P., Nair, M. K. 2001. Squamous Cell Carcinoma of the Tongue Among Young Indian Adults. *Neoplasia*, 3(4):273–277.
- Jangid, K., Alexander, A., Jayakumar, N., Varghese, S., Ramani, P. 2015. Ankyloglossia with cleft lip: A rare case report. *Journal of Indian Society of Periodontology*, 19(6):690.
- Jayaraj, G., Ramani, P., Sherlin, H. J., Premkumar, P., Anuja, N. 2015a. Inter-observer agreement in grading oral epithelial dysplasia – A systematic review. *Journal of Oral and Maxillofacial Surgery, Medicine, and Pathology*, 27(1):112–116.
- Jayaraj, G., Sherlin, H., Ramani, P., Premkumar, P., Anuja, N. 2015b. Cytomegalovirus and Mucoepidermoid carcinoma: A possible causal relationship? A pilot study. *Journal of Oral and Maxillofacial Pathology*, 19(3):319.
- Jayaraj, G., Sherlin, H. J., Ramani, P., Premkumar, P., Natesan, A. 2015c. Stromal myofibroblasts in oral squamous cell carcinoma and potentially malig-

- nant disorders. *Indian Journal of Cancer*, 52(1):87.
- Jeng, J. H., Chang, M. C., Hahn, L. J. 2001. Role of areca nut in betel quid-associated chemical carcinogenesis: current awareness and future perspectives. *Oral Oncology*, 37(6):477-492.
- Krishnamurthy, A., Ramshankar, V. 2013. Early Stage Oral Tongue Cancer among Non-Tobacco Users - An Increasing Trend Observed in a South Indian Patient Population Presenting at a Single Centre. *Asian Pacific Journal of Cancer Prevention*, 14(9):5061-5065.
- Kruse, A. L., Bredell, M., Grätz, K. W. 2010. Oral squamous cell carcinoma in non-smoking and non-drinking patients. *Head and Neck Oncology*, 2(1).
- Rapidis, A. D., Langdon, J. D., Patel, M. F., Harvey, P. W. 1977. Stmp a new system for the clinico-pathological classification and identification of intra-oral carcinomata. *Cancer*, 39(1):204-209.
- Selvamani, M., Yamunadevi, A., Basandi, P. S., Madhushankari, G. S. 2015. Prevalence of oral squamous cell carcinoma of tongue in and around Davangere, Karnataka, India: A retrospective study over 13 years. *Journal of Pharmacy and Bioallied Sciences*, 7(6):491.
- Sherlin, H. J., Ramani, P., Premkumar, P., Kumar, A., Natesan, A. 2015. Expression of CD 68, CD 45 and human leukocyte antigen-DR in central and peripheral giant cell granuloma, giant cell tumor of long bones, and tuberculous granuloma: An immunohistochemical study. *Indian Journal of Dental Research*, 26(3):295.
- Shree, K. H., Ramani, P., Sherlin, H., Sukumaran, G., Jeyaraj, G., Don, K. R., Santhanam, A., Ramasubramanian, A., Sundar, R. 2019. Saliva as a Diagnostic Tool in Oral Squamous Cell Carcinoma - a Systematic Review with Meta Analysis. *Pathology and Oncology Research*, 25(2):447-453.
- Sivaramakrishnan, S. M., Ramani, P. 2015. Study on the Prevalence of Eruption Status of Third Molars in South Indian Population. *Biology and Medicine*, 07(04).
- Sridharan, G., Ramani, P., Patankar, S. 2017. Serum metabolomics in oral leukoplakia and oral squamous cell carcinoma. *Journal of Cancer Research and Therapeutics*, 13(3):556.
- Sridharan, G., Ramani, P., Patankar, S., Vijayaraghavan, R. 2019. Evaluation of salivary metabolomics in oral leukoplakia and oral squamous cell carcinoma. *Journal of Oral Pathology and Medicine*, 48(4):299-306.
- Sturgis, E. M., Wei, Q., Spitz, M. R. 2004. Descriptive epidemiology and risk factors for head and neck cancer. *Seminars in Oncology*, 31(6):726-733.
- Swathy, S., Gheena, S., Varsha, S. L. 2015. Prevalence of pulp stones in patients with history of cardiac diseases. *Research Journal of Pharmacy and Technology*, 8(12):1625.
- Thangaraj, S. V., Shyamsundar, V., Krishnamurthy, A., Ramani, P., Ganesan, K., Muthuswami, M., Ramshankar, V. 2016. Molecular Portrait of Oral Tongue Squamous Cell Carcinoma Shown by Integrative Meta-Analysis of Expression Profiles with Validations. *PLOS ONE*, 11(6):e0156582.
- Viveka, T. S., Shyamsundar, V., Krishnamurthy, A., Ramani, P., Ramshankar, V. 2016. p53 Expression Helps Identify High Risk Oral Tongue Premalignant Lesions and Correlates with Patterns of Invasive Tumour Front and Tumour Depth in Oral Tongue Squamous Cell Carcinoma Cases. *Asian Pacific Journal of Cancer Prevention*, 17(1):189-195.
- Wahi, P. N., Kehar, U., Lahiri, B. 1965. Factors influencing oral and oropharyngeal cancers in India. *British Journal of Cancer*, 19(4):642-660.
- Warnakulasuriya, S. 2009. Global epidemiology of oral and oropharyngeal cancer. *Oral Oncology*, 45(4-5):309-316.