



Prevalence of desquamative gingivitis in dermatological lesions - A retrospective institution based study

Santosh Bala¹, Herald J Sherlin^{*2}, Vivek Narayan³

¹Saveetha Dental college and Hospitals, Saveetha Institute of Medical and Technical Sciences Saveetha University, Chennai - 600 077, Tamil Nadu, India

²Department of Oral pathology, Saveetha Dental college and Hospitals, Saveetha Institute of Medical and Technical Sciences, Saveetha University, Chennai - 600 077, Tamil Nadu, India

³Department of Oral Medicine, Saveetha Dental college and Hospitals, Saveetha Institute of Medical and Technical Sciences, Saveetha University, Chennai - 600 077, Tamil Nadu, India

Article History:

Received on: 28 Aug 2020

Revised on: 29 Sep 2020

Accepted on: 01 Oct 2020

Keywords:

Desquamative gingiva,
Dermatological lesions,
Oral Lichen planus,
pemphigus

ABSTRACT

The oral cavity is considered to be the window to your body because oral manifestations accompany many systemic diseases. In many instances, oral involvement precedes the appearance of other symptoms or lesions at other locations. The aim of this study is to find the correlation of these formative gingiva along with dermatological lesions. Details of patients reported with dermatological lesions to the dental hospital with oral manifestations were obtained from a detailed patient record. The data collected is tabulated graphically via SPSS for statistical analysis. 24 patients were reported with various dermatological lesions. 70% of female predilection was observed, and maximum patients carried the lesion for about 12 months. Out of the 24 patients, 70% show the presence of desquamative gingiva clinically. Histopathological diagnosis shows that 75% of the dermatological lesions present in the oral cavity is lichen planus. According to the current study population, dermatological lesions are the common cause of desquamative gingiva. The prevalence of oral lichen planus was higher and commonly seen along with desquamative gingiva.



*Corresponding Author

Name: Herald J Sherlin

Phone:

Email: sherlin@saveetha.com

ISSN: 0975-7538

DOI: <https://doi.org/10.26452/ijrps.v11iSPL3.3374>

Production and Hosted by

IJRPS | <https://ijrps.com>

© 2020 | All rights reserved.

INTRODUCTION

The mouth or the oral cavity is always known to be a sentinel or early warning system, that is why it is often referred to as the mirror of health

and disease (Scully and Porter, 1997; Sridharan *et al.*, 2017). Most of the oral mucosa is derived embryologically from an invagination of the ectoderm (Squier and Brogden, 2010; Thangaraj *et al.*, 2016). Thus due to similar orifices, other disorders which are primarily associated with the skin are involved (Eisenberg and Krutchkoff, 1992; Gupta and Ramani, 2016; Jayaraj *et al.*, 2015b).

Lichen planus is a chronic mucocutaneous disorder of the stratified squamous epithelium that affects oral and genital mucous membranes (Boyd and Neldner, 1991; Sivaramakrishnan and Ramani, 2015; Shree *et al.*, 2019). Oral lichen planus is considered to be nothing but the mucosal counterpart of cutaneous lichen planus (Mollaoglu, 2000; Viveka *et al.*, 2016; Hannah *et al.*, 2018). Pemphigus Vulgaris is an autoimmune intraepithelial blis-

tering disease involving the skin and mucous membrane (Langan *et al.*, 2008; Jangid *et al.*, 2015). The condition is known to affect both sexes equally and is found to be more common in middle-aged and elderly patients (Becker and Gaspari, 1993; Jayaraj *et al.*, 2015a).

Most patients present with oral lesions as their first sign of pemphigus Vulgaris. The most common site of infection of these diseases is buccal mucosa, Palate then lingual and labial mucosa. The gingiva is not the site to be affected with pemphigus Vulgaris, but the most common oral manifestation preceding the lesion is desquamative gingivitis (Sridharan *et al.*, 2019; López-Jornet and Bermejo-Fenoll, 2005). In many pemphigus Vulgaris patients, oral lesions are very commonly seen and often followed by the development of skin lesions (López-Jornet and Bermejo-Fenoll, 2005; Gheena and Ezhilarasan, 2019).

The term desquamation is derived from the Latin word, which translates scraping fish flakes (Swathy *et al.*, 2015; Suresh, 2016; Sherlin *et al.*, 2015). In medical terms, the word defines loss of epithelium elements in small and large amounts. Desquamative gingiva is a clinical finding which progresses characteristic features like erosion, vesicular formation, atrophy, marginal and keratinised gingiva (Shklar, 1968; Jayaraj *et al.*, 2015c). There has been insufficient research done to try associating dermatological lesions with desquamative gingiva. The current study tries to find a correlation between dermatological lesions and desquamative gingiva to aid in an easier diagnosis and effective treatment plan. The aim of the present study is to find the prevalence of desquamative gingiva in dermatological lesions.

MATERIALS AND METHODS

The present study is a correlation type study the setting used for data collection was the hospital typesetting. The parameters used in the present study are age, gender, duration of presenting illness, previous history, clinical appearance, presence of desquamative gingiva, clinical diagnosis, histopathological diagnosis and treatment. Data was collected using reviewed patient records and analysed the data of 86,000 patients between June 2019 and March 2020. This record is a patient management software to store and maintain patient details and patient history right from their first visit to the last visit. All the cases report present in the software word cross-verified by the examiner and then uploaded. The data collected from the patient record was transferred to SPSS for further analysis. Chi-Square test was done to compare the proportion

between various parameters, and $p < 0.05$ were considered significant.

RESULTS AND DISCUSSION

A total of 24 patients with dermatological lesions were identified in the study. Among these 24 patients, 70% were females, 30% were males. The most commonly affected age group is from 50 to 60 years. The current study also showed that most of the patients, around 50%, showed a burning sensation in the mouth as their presenting illness. The most common presenting illness seen was burning sensation in patients diagnosed histopathologically as lichen planus. This was found to be statistically significant. Pearson's chi-square $p = 0.020$ (Table 1). The clinical diagnosis showed 41% lichen planus, and histological diagnosis showed 75% lichen planus. The X-axis represents the various clinical diagnosis, and Y-axis represents the count of the histopathological diagnosis. The green bar represents that histopathological diagnosis of lichen planus and the blue bar represents that histopathological diagnosis that was not performed. Most of the lesions diagnosed clinically as different dermatological and gingival lesions were diagnosed histopathologically as lichen planus and pemphigus Vulgaris had been diagnosed clinically and not histopathologically. This was found to be statistically significant. Pearson's chi-square $p < .001$ (Figure 1). The correlation between clinical diagnosis and desquamative gingiva showed 91% likelihood and the correlation between these ram showing correlation between Histopathological diagnosis and Clinical Diagnosis.

One such study shows that 72.9% of females are more frequent with oral manifestations and dermatological lesions which is similar to our result of 70% female predilection (Hasan *et al.*, 2012). The mean age group that's predominantly affected by oral lichen planus is 45 to 55 years. Previous studies show that the mean age of patients affected by oral lichen planus is 58 years.

Numerous diseases present as desquamative gingivitis, in the present study, lichen planus is the most common oral lesion 75%. The X-axis represents the various clinical diagnosis, and Y-axis represents the frequency of desquamative gingivitis. Blue bar represents the absence of desquamative gingiva, and the green bar represents the presence of desquamative gingiva. The incidence of desquamative gingiva in dermatological lesions like Oral Lichen planus and pemphigus Vulgaris was found to be remarkably high and statistically significant. Pearson's chi-square $p = 0.001$ (Figure 2). These findings are in

Table 1: Cross Tabulation showing the relationship between histopathological diagnosis and presenting illness

Histopathological Diagnosis	Asymptomatic	Burning Sensation	Pain	Pain and Burning sensation	Blisters/ulcers	White patches
No biopsy	0	0	2	0	4	0
Oral Lichen Planus	1	11	3	1	1	1

Table 2: Cross Tabulation depicting the relationship between Histopathological Diagnosis and Presence or absence of Desquamative Gingivitis

Histopathological Diagnosis	Desquamative Gingiva Absent	Desquamative Gingiva Present
No biopsy	0	6
Oral Lichen Planus	7	11

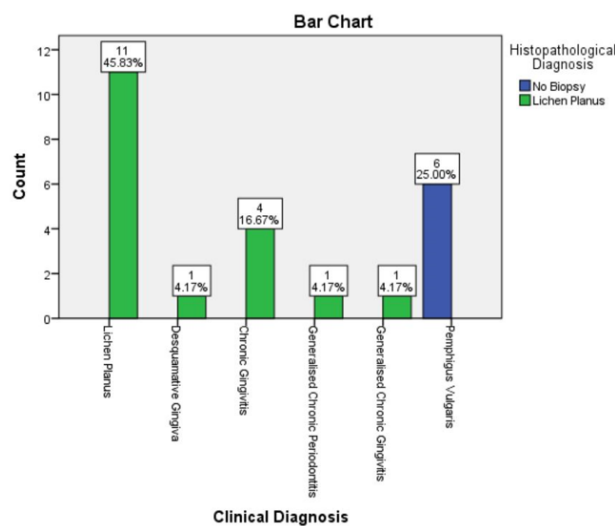


Figure 1: Bar diagram depicting the correlation between Histopathological Diagnosis and Clinical diagnosis of oral manifestations in dermatological lesions

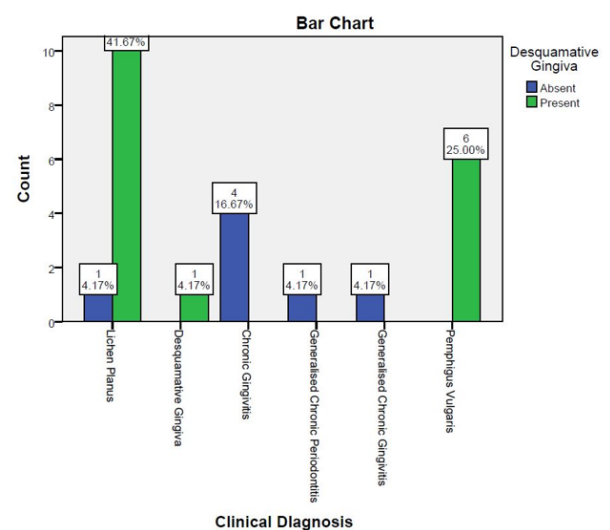


Figure 2: Bar chart depicting the correlation between Presence or absence of Desquamative Gingivitis and clinical diagnosis

contrast to those previously reported wherein pemphigus was the most common lesion associated with desquamative gingivitis. (Ahmed et al., 2006). This might be due to various reasons like the prevalence of Lichen planus compared to Pemphigus in the present population and other geographical and ethnic variations (Loue and Pike, 2007). The drawback in the present study was that histopathological was not carried out for 6 pemphigus Vulgaris patients who were evaluated only by clinical features. There was no significant association between Histopathological diagnosis and Desquamative gingivitis. Pearson’s chi-square $p = 0.070$ (Table 2). Histopathological diagnosis enables dental practitioners to procure a more efficient treatment planning as it is a more accurate approach.

Another study states that the prevalence of desquamative gingivitis is more commonly seen in mucous membrane pemphigoid, where the current study shows oral lichen planus (Scully and Muzio, 2008). The limitations to the following study might be due to the small sample size collected in a restricted population, and many other parameters are not taken into consideration such as genetic parameters, other organs affected and the MMP cannot be confirmed by immunofluorescence. However, the present study shows future scope with advanced histopathological procedures, further studies with larger populations. The knowledge obtained from the study aids dentists to understand better other oral conditions that are analogous to dermatological lesions. Histopathological diagnosis and clinical diagnosis are both equally important for arriving at

an accurate diagnosis and efficient treatment plan.

CONCLUSION

According to the current study population, dermatological lesions are the common cause of desquamative gingiva. The prevalence of oral lichen planus was higher and commonly seen along with desquamative gingiva.

Conflict of Interest

The authors declare that they have no conflict of interest for this study.

Funding Support

The authors declare that they have no funding support for this study.

REFERENCES

- Ahmed, A. R., Spigelman, Z., Cavacini, L. A., Posner, M. R. 2006. Treatment of Pemphigus Vulgaris with Rituximab and Intravenous Immune Globulin. *New England Journal of Medicine*, 355(17):1772-1779.
- Becker, B. A., Gaspari, A. A. 1993. Pemphigus Vulgaris and Vegetans. *Dermatologic Clinics*, 11(3):429-452.
- Boyd, A. S., Neldner, K. H. 1991. Lichen planus. *Journal of the American Academy of Dermatology*, 25(4):593-619.
- Eisenberg, E., Krutchkoff, D. J. 1992. Lichenoid lesions of oral mucosa. *Oral Surgery, Oral Medicine. Oral Pathology*, 73(6):699-704.
- Gheena, S., Ezhilarasan, D. 2019. Syringic acid triggers reactive oxygen species-mediated cytotoxicity in HepG2 cells. *Human and Experimental Toxicology*, 38(6):694-702.
- Gupta, V., Ramani, P. 2016. Histologic and immunohistochemical evaluation of mirror image biopsies in oral squamous cell carcinoma. *Journal of Oral Biology and Craniofacial Research*, 6(3):194-197.
- Hannah, R., Ramani, P., Sherlin, H. J., Ranjith, G., Ramasubramanian, A., Jayaraj, G., Don, K. R., Archana, S. 2018. Awareness about the use, Ethics and Scope of Dental Photography among Undergraduate Dental Students Dentist Behind the lens. *Research Journal of Pharmacy and Technology*, 11(3):1012-1016.
- Hasan, S., Kapoor, B., Siddiqui, A., Srivastava, H., Akhtar, Y., Fatima, S. 2012. Mucous membrane pemphigoid with exclusive gingival involvement: Report of a case and review of literature. *Journal of Orofacial Sciences*, 4(1):64-69.
- Jangid, K., Alexander, A., Jayakumar, N., Varghese, S., Ramani, P. 2015. Ankyloglossia with cleft lip: A rare case report. *Journal of Indian Society of Periodontology*, 19(6):690-693.
- Jayaraj, G., Ramani, P., Sherlin, H. J., Premkumar, P., Anuja, N. 2015a. Inter-observer agreement in grading oral epithelial dysplasia – A systematic review. *Journal of Oral and Maxillofacial Surgery, Medicine, and Pathology*, 27(1):112-116.
- Jayaraj, G., Sherlin, H., Ramani, P., Premkumar, P., Anuja, N. 2015b. Cytomegalovirus and Mucoepithelial carcinoma: A possible causal relationship? A pilot study. *Journal of Oral and Maxillofacial Pathology*, 19(3):319-324.
- Jayaraj, G., Sherlin, H. J., Ramani, P., Premkumar, P., Natesan, A. 2015c. Stromal myofibroblasts in oral squamous cell carcinoma and potentially malignant disorders. *Indian Journal of Cancer*, 52(1):87-92.
- Langan, S. M., Smeeth, L., Hubbard, R., Fleming, K. M., Smith, C. J. P., West, J. 2008. Bullous pemphigoid and pemphigus vulgaris—incidence and mortality in the UK: population based cohort study. *BMJ*, 337:a180.
- López-Jornet, P., Bermejo-Fenoll, A. 2005. Gingival lesions as a first symptom of pemphigus vulgaris in pregnancy. *British Dental Journal*, 199(2):91-92.
- Loue, S., Pike, E. C. 2007. Case Studies in Ethics and HIV Research. Springer Science & Business Media. ISBN: 9780387713625.
- Mollaoglu, N. 2000. Oral lichen planus: a review. *British Journal of Oral and Maxillofacial Surgery*, 38(4):370-377.
- Scully, C., Muzio, L. L. 2008. Oral mucosal diseases: Mucous membrane pemphigoid. *British Journal of Oral and Maxillofacial Surgery*, 46(5):358-366.
- Scully, C., Porter, S. R. 1997. The clinical spectrum of desquamative gingivitis. *Seminars in Cutaneous Medicine and Surgery*, 16(4):308-313.
- Sherlin, H., Ramani, P., Premkumar, P., Kumar, A., Natesan, A. 2015. Expression of CD 68, CD 45 and human leukocyte antigen-DR in central and peripheral giant cell granuloma, giant cell tumor of long bones, and tuberculous granuloma: An immunohistochemical study. *Indian Journal of Dental Research*, 26(3):295-303.
- Shklar, G. 1968. Erosive and bullous oral lesions of lichen planus: histologic studies. *Archives of Dermatology*, 97(4):411-416.
- Shree, K. H., Ramani, P., Sherlin, H., Sukumaran, G., Jeyaraj, G., Don, K. R., Santhanam, A., Ramasubra-

- manian, A., Sundar, R. 2019. Saliva as a Diagnostic Tool in Oral Squamous Cell Carcinoma – a Systematic Review with Meta Analysis. *Pathology and Oncology Research*, 25(2):447–453.
- Sivaramakrishnan, S. M., Ramani, P. 2015. Study on the Prevalence of Eruption Status of Third Molars in South Indian Population. *Biology and Medicine*, 07(04):1–4.
- Squier, C., Brogden, K. 2010. Human Oral Mucosa: Development, Structure and Function. John Wiley & Sons. ISBN: 9780470959732.
- Sridharan, G., Ramani, P., Patankar, S. 2017. Serum metabolomics in oral leukoplakia and oral squamous cell carcinoma. *Journal of Cancer Research and Therapeutics*, 13(3):556–561.
- Sridharan, G., Ramani, P., Patankar, S., Vijayaraghavan, R. 2019. Evaluation of salivary metabolomics in oral leukoplakia and oral squamous cell carcinoma. *Journal of Oral Pathology and Medicine*, 48(4):299–306.
- Suresh, S. S. 2016. Medical Management of Oral Lichen Planus: A Systematic Review. *Journal of Clinical and Diagnostic Research*, 10(02):10–15.
- Swathy, S., Gheena, S., Varsha, S. L. 2015. Prevalence of pulp stones in patients with history of cardiac diseases. *Research Journal of Pharmacy and Technology*, 8(12):1625–1628.
- Thangaraj, S. V., Shyamsundar, V., Krishnamurthy, A., Ramani, P., Ganesan, K., Muthuswami, M., Ramshankar, V. 2016. Molecular Portrait of Oral Tongue Squamous Cell Carcinoma Shown by Integrative Meta-Analysis of Expression Profiles with Validations. *PLOS ONE*, 11(6):1–25.
- Viveka, T. S., Shyamsundar, V., Krishnamurthy, A., Ramani, P., Ramshankar, V. 2016. p53 Expression Helps Identify High Risk Oral Tongue Premalignant Lesions and Correlates with Patterns of Invasive Tumour Front and Tumour Depth in Oral Tongue Squamous Cell Carcinoma Cases. *Asian Pacific Journal of Cancer Prevention*, 17(1):189–195.