



Oral mucosal lesions in children with and without cleft lip and palate: a case control study

Yashila Periyasamy¹, Vignesh Ravindran^{*2}, Subhashini V C³

¹Saveetha Dental College and Hospitals, Saveetha Institute of Medical and Technical Sciences, Saveetha University, Chennai-77, Tamil Nadu, India

²Department of Paedodontics, Saveetha Dental College and Hospitals, Saveetha Institute of Medical and Technical Sciences, Saveetha University, Chennai-77, Tamil Nadu, India

³Department of Public Health Dentistry, Saveetha Dental College and Hospitals, Saveetha Institute of Medical and Technical Sciences, Saveetha University, Chennai-77, Tamil Nadu, India

Article History:

Received on: 26 Jul 2020
Revised on: 11 Sep 2020
Accepted on: 22 Sep 2020

Keywords:

cleft lip and palate,
oral Mucosal Lesions,
soft tissues

ABSTRACT

Orofacial clefts are a major health problem affecting individuals worldwide. Affected children would be having functional and aesthetic problems, such as breastfeeding difficulties due to improper oral seal and nasal regurgitation. Hearing and speech difficulties are also associated with the aperture. Oral mucosal lesions are commonly missed due to higher concern over the cleft than the minority of these conditions. The purpose of the study was to assess the presence or absence of oral mucosal lesions in children with and without cleft lip and palate. A total of 89000 cases were reviewed between June 2019 to March 2020 for the incidence of oral mucosal lesions in individuals with and without cleft lip and palate only. The present study consists of 30 children divided into two groups: children with cleft lip and palate and children without cleft lip and palate. In both groups, the presence of oral mucosal lesions was noted. Absence of oral mucosal lesions in both children with cleft lip and palate and children without cleft lip and palate. In this study, there is no evidence regarding oral mucosal lesions in children with and without cleft lip and palate.



*Corresponding Author

Name: Vignesh Ravindran
Phone: +91 9789934476
Email: vigneshr.sdc@saveetha.com

ISSN: 0975-7538

DOI: <https://doi.org/10.26452/ijrps.v11iSPL3.3370>

Production and Hosted by

IJRPS | <https://ijrps.com>

© 2020 | All rights reserved.

ered in 1691 by Hendrik Van Roonhuyzez. Although the earliest evidence. Although the earliest evidence of it in antiquity was discovered in Egyptian mummies (Murray, 2002; Agbenorku, 2013). Due to the esthetic and functional defects, they lead a poor quality of life (Cooper, 2000; Jeevanandan, 2017). Cleft lip and palate is the second most common congenital birth defect in the world. The main aim of surgical correction of orofacial clefts is to help in feeding, guide facial growth, and improvise speech and language development (Burg, 2016; Govindaraju *et al.*, 2017c).

INTRODUCTION

Cleft lip /cleft palate is known as a congenital craniofacial anomaly with cleft lip being recorded in 1556 by Pierse Franco, and cleft lip and palate was discov-

Orofacial clefts are one of the common congenital craniofacial birth defects. They exhibit both ethnic and geographic variations (Mossey, 2009). Orofacial clefts are caused by various factors such as infection, toxicity, poor diet, hormonal imbalance and genetic

interference. Genes play a key role in the formation of clefts (Jugessur *et al.*, 2009). Incomplete fusion of these prominence during 4th to 12th week during intrauterine life leads to cleft lip, cleft palate or combination of both (Mossey, 2009; Szabo, 2012).

Based on the embryological characteristics, clefts can be involving the lip and alveolus, involving the lip and palate, palate alone and sometimes congenital insufficiency of the palate (Govindaraju *et al.*, 2017a; Ramakrishnan and Bhurki, 2018). Dental complications of orofacial clefts include anodontia, ectopic eruption, supernumerary teeth, microdontia, macrodontia, peg laterals, enamel hypoplasia, fused tooth, deep bite, anterior or posterior cross-bite, crowding and spacing of teeth (Sudhakar, 2009; Somasundaram, 2015).

Oral mucosal lesions are abnormal alteration in colour, surface aspect, loss of integrity or swelling on the oral mucosal surfaces. Oral mucosal lesions are benign and they require no active treatment and symptomatic relief is only required. It interferes with mastication, swallowing and speech. It also causes burning, irritation and pain during food consumption (Zainab and Salih, 2012; Jeevanandan and Govindaraju, 2018). The oral mucosal lesion could be due to viral, bacterial or fungal infections, local trauma or irritation and systemic diseases (Feng, 2015; Kaul, 2017). A study conducted (Chandroth, 2014; Govindaraju *et al.*, 2017b) concluded that 28.9% of children with cleft defects had some kind of oral mucosal lesion. He also concluded that oral candidiasis was the most common, followed by traumatic lesions and erythema multiforme (Neville, 2015; Ravikumar *et al.*, 2017). Traumatic oral soft tissue lesions due to habits that tend to cause severe injuries such as lip and cheek biting, orthodontic appliances, food burns, sharp edges of wires in space maintainers (Neville, 2015; Lakshmanan *et al.*, 2020). There is surprisingly little information on the prevalence of oral mucosal lesions and extraoral lesions among patients with cleft lip and palate in India. Thus the aim of the present study was to assess the presence of oral mucosal lesions in children with and without cleft lip and palate.

MATERIALS AND METHODS

This retrospective study was conducted under a hospital-based university setting. Ethical approval for this study was granted by the institute's ethical committee (ethical approval number: SDC/SIHEC/2020/DIASDATA/0619-0320). Consent to use treatment records for research purposes were obtained from patients/guardians at the time of patient entry into the university for dental needs.

The retrospective data were collected by obtaining and analysing the 89000 dental case records of the university from June 2019 to March 2020. We registered our research topic in a private dental institute in Chennai. Our project was evaluated and approved by the ethical committee of the private dental institute. The sample size that we have collected from the private dental institute was 30 (20 present -cleft lip and palate and ten absent – cleft lip and palate). The inclusion criteria were children with cleft lip and palate only, children between the age of 0 -17 years, complete photographs and written records regarding the complete intraoral examination of the patient. Age and gender-matched controls, i.e. children without cleft lip and palate were taken according to the relevant cases obtained from the inclusion criteria. The exclusion criteria were incomplete and censored dental records and the absence of photographic evidence of cleft lip and palate and clinical findings. The selected case and control group were examined by three people; one reviewer, one guide and one researcher. The patients' case sheets were reviewed thoroughly.

Cross-checking of data including digital entry and intraoral photographs was done by an additional reviewer and as a measure to minimise sampling bias, samples for the group were picked by simple random sampling. A digital entry of clinical examinations and intraoral photographs of selected subjects were assessed and this included the assessment of the oral mucosal lesion in children with cleft lip and palate as mentioned before by the examiner based on intraoral photographs and clinical examination data for each tooth. The examiner was trained to add data of malocclusion as present or absent for both case and control group by tabulation using excel software and even the type of malocclusion was noted. Data analysis was done using SPSS PC Version 23.0 (IBM;2016) software for statistics. The prevalence of malocclusion for both case and control group were compared by Mann Whitney Test.

RESULTS AND DISCUSSION

The final study population was 20 patients with ten patients in the case group (children with cleft lip and palate) and ten patients in the control group (children without cleft lip and palate)— Figure 1 shows that Notice the equal distribution of cases for both the case group and control group. In the case group, out of the ten patients, 5 (50%) were males and 5 (50%) were females. A similar distribution was done while selecting the control group— Figure 2 shows that Notice the equal distribution of

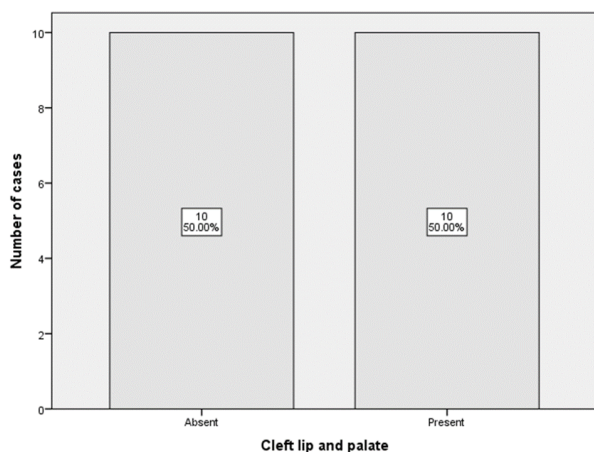


Figure 1: The graph bar shows case distribution in case group (children with cleft lip and palate) and control group (children without cleft lip and palate)

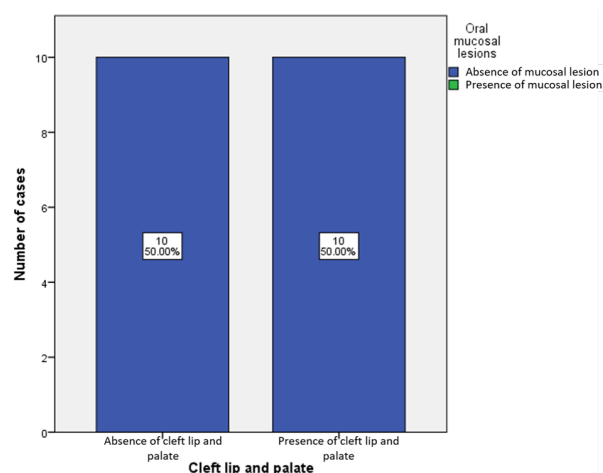


Figure 3: The graph bar depicts the presence or absence of oral mucosal lesion in children with cleft lip and palate (case group) and children without cleft lip and palate (control group)

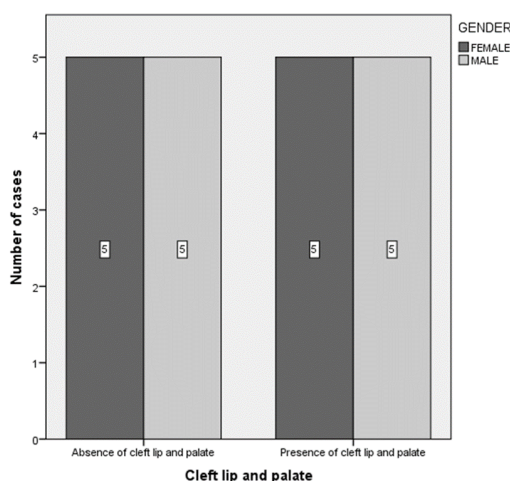


Figure 2: The graph bar shows gender distribution of cases in case group (children with cleft lip and palate) and control group (children without cleft lip and palate)

gender for both the case group and control group. There is an absence of oral mucosal lesion in all the cases in both groups (children with and without cleft lip and palate) Figure 3 shows that None of the cases in both the case group and control group had oral mucosal lesions. However, comparing these data with the Mann-Whitney U test was statistically significant (p-value=0.000), there were no cases in both the groups with the presence of oral mucosal lesions.

Oral mucosa acts as a protective barrier against trauma, pathogens and carcinogens (Subramanyam, 2018). Oral cavities can be considered as a gateway into the digestive system. Sometimes, oral lesions are the first indication of systemic disease (Majorana, 2010; Ali et al., 2013). Pinto et al. (2014)

divided paediatric soft tissue oral lesions into several categories: developmental lesions, white lesions, red and/ or white lesions; brown-black lesions; soft tissue nodules- inflammatory/ reactive lesions; ulcerations and benign tumours (Pinto et al., 2014; Govindaraju, 2017).

Bezerra et al. (Bezerra and Costa, 2001) found that childhood oral mucosal lesions among 104 patients ranging from 0 to 5 years children to be 2.3% by observing their dental records. According to this study, the most common oral mucosal lesions were Bohn nodules (37%) followed by candidiasis (25%) and benign migratory glossitis were the least common with 21%. Bessa et al. (Bessa et al., 2004) found that incidence of childhood mucosal lesions among 0 to 4-year-olds to be 24.9% and the most common lesions were geographic tongue (9.8%) followed by bite injuries (6.1%). The most common lesion was caused by *Candida albicans*.

According to Maxill (Morrill, 2005), the use of feeding bottle led to oral bacterial colonization. The bottle acts as a vector for the candida in the environment. Traumatic ulcers develop from physical, thermal or chemical injuries. Accidental biting during mastication or consumption of hot food may cause traumatic ulcerations (Panchal et al., 2019). Iatrogenic damages caused by dental treatments also cause traumatic ulceration (Anura, 2014; Gurunathan and Shanmugaavel, 2016). Frictional keratosis also called mastico buccasum are white patches caused due to traumatic tooth brushing (toothbrush keratosis) due to constant rubbing of the mucosa, frictional keratosis can occur (Shulman, 2005; Christabel, 2015).

Leukodema is a white lesion which is found on the buccal and/or the labial mucosa (Ali *et al.*, 2013; Packiri, 2017). It can be unilateral or bilateral and is associated with smoking and local irritation. Prevalence differs from 0.96% to 58% and highest prevalence noted in African populations (Pindborg, 1965; Martin, 1973).

In our study, we found that children with a palate as well as children without cleft palate both had an absence of oral mucosal lesions with the p-value >0.05 is not significant. There were a few contradicting studies by Chopra (2014), which found that children with clefts have a higher prevalence of anterior open-bite, increased overjet and presence of oral mucosal lesions (Chopra, 2014; Ünür *et al.*, 2015) stated that fissured tongue was the most frequent lesion followed by traumatic ulcer. The consensus of our study disagreed due to the smaller sample size as well as the geographic restrictions present while carrying out this study.

The advantages of the study were that this was a case-control study with age and gender-matched control to provide better results and high internal validity. The limitations found in the study are geographic restrictions as the patients are from around the same region. Besides, there was only a single ethnicity as a group of people who are from the same ethnicity group. The unicentric study, small sample sizes and indirect clinical observation are also some of the challenges faced while conducting our study. The future scope of this study could involve studies with a larger sample size for the case group, that is not confined to a particular geographic region.

CONCLUSION

Within the limitations of the study, oral mucosal lesions were not identified in children with and without cleft lip and palate. Despite the presence or absence of cleft, the dental practitioner should be vigilant in noticing such lesions and treat it accordingly at the earliest for the betterment of the patient.

Acknowledgement

The authors of this study acknowledge the institute, for their help towards collecting all the patient case records and other data in relevance to the current study.

Conflict Of Interest

The authors declare that there are no conflicts of interest for this study.

Funding Support

The authors declare that they have no funding support for this study.

REFERENCES

- Agbenorku, P. 2013. Orofacial Clefts: A World-wide Review of the Problem. *ISRN Plastic Surgery*, 2013:1-7.
- Ali, M., Joseph, B., Sundaram, D. 2013. Prevalence of oral mucosal lesions in patients of the Kuwait University Dental Center. *The Saudi Dental Journal*, 25(3):111-118.
- Anura, A. 2014. Traumatic oral mucosal lesions: a mini review and clinical update. *Oral health and dental management*, 13(2):254-259.
- Bessa, C. F. N., Santos, P. J. B., Aguiar, M. C. F., do Carmo, M. A. V. 2004. Prevalence of oral mucosal alterations in children from 0 to 12 years old. *Journal of Oral Pathology and Medicine*, 33(1):17-22.
- Bezerra, S., Costa, I. 2001. Oral conditions in children from birth to 5 years: the findings of a children's dental program. *Journal of Clinical Pediatric Dentistry*, 25(1):79-81.
- Burg, M. L. 2016. Epidemiology, Etiology, and Treatment of Isolated Cleft Palate. *Frontiers in physiology*, 7:67.
- Chandroth, S. V. 2014. Prevalence of oral mucosal lesions among fishermen of Kutch coast. *International maritime health*, 65(4):192-198.
- Chopra, A. 2014. Oral health in 4-6 years children with cleft lip/palate: a case control study. *North American journal of medical sciences*, 6(6):266-269.
- Christabel, S. L. 2015. Prevalence of Type of Frenal Attachment and Morphology of Frenum in Children, Chennai, Tamil Nadu. *World Journal of Dentistry*, 6(4):203-207.
- Cooper, M. E. 2000. Descriptive epidemiology of nonsyndromic cleft lip with or without cleft palate in Shanghai, China, from 1980 to 1989. *The Cleft palate-craniofacial journal*, 37(3):274-280.
- Feng, J. 2015. Prevalence and distribution of oral mucosal lesions: a cross-sectional study in Shanghai, China. *Journal of Oral Pathology & Medicine*, 44(7):490-494.
- Govindaraju, L. 2017. Effectiveness of Chewable Tooth Brush in Children-A Prospective Clinical Study. *Journal Of Clinical And Diagnostic Research*, 11(3):31-34.
- Govindaraju, L., Jeevanandan, G., Subramanian, E. 2017a. Clinical Evaluation of Quality of Obturation and Instrumentation Time using Two Modified Rotary File Systems with Manual Instrumentation in Primary Teeth. *Journal of clinical and diagnostic research*, 11(9):55-58.

- Govindaraju, L., Jeevanandan, G., Subramanian, E. M. G. 2017b. Comparison of quality of obturation and instrumentation time using hand files and two rotary file systems in primary molars: A single-blinded randomized controlled trial. *European Journal of Dentistry*, 11(03):376–379.
- Govindaraju, L., Jeevanandan, G., Subramanian, E. M. G. 2017c. Knowledge and practice of rotary instrumentation in primary teeth among indian dentists: A questionnaire survey. *Journal of International Oral Health*, 9(2):45.
- Gurunathan, D., Shanmugaavel, A. K. 2016. Dental neglect among children in Chennai. *Journal of Indian Society of Pedodontics and Preventive Dentistry*, 34(4):364.
- Jeevanandan, G. 2017. Kedo-S Paediatric Rotary Files for Root Canal Preparation in Primary Teeth – Case Report. *Journal of Clinical and Diagnostic Research*, 11(3):3–5.
- Jeevanandan, G., Govindaraju, L. 2018. Clinical comparison of Kedo-S paediatric rotary files vs manual instrumentation for root canal preparation in primary molars: a double blinded randomised clinical trial. *European Archives of Paediatric Dentistry*, 19(4):273–278.
- Jugessur, A., Farlie, P. G., Kilpatrick, N. 2009. The genetics of isolated orofacial clefts: from genotypes to subphenotypes. *Oral Diseases*, 15(7):437–453.
- Kaul, R. 2017. Cleft lip and cleft palate: Role of a pediatric dentist in its management. *International Journal of Pedodontic Rehabilitation*, 2(1):1. Medknow Publications and Media Pvt. Ltd.
- Lakshmanan, L., Mani, G., Jeevanandan, G., Ravindran, V., Ganapathi, S. E. M. 2020. Assessing the quality of root canal filling and instrumentation time using kedo-s files, reciprocating files and k-files. *Brazilian Dental Science*, 23(1).
- Majorana, A. 2010. Oral mucosal lesions in children from 0 to 12 years old: ten years' experience. *Oral surgery, oral medicine, oral pathology, oral radiology, and endodontics*, 110(1):13–21.
- Martin, J. L. 1973. Epidemiology of leukoedema in the Negro. *Journal of oral medicine*, 28(2):41–44.
- Morrill, J. F. 2005. Risk Factors for Mammary Candidosis Among Lactating Women. *Journal of Obstetric, Gynecologic and Neonatal Nursing*, 34(1):37–45.
- Mossey, P. A. 2009. Cleft lip and palate. *The Lancet*, 374(9703):1773–1785.
- Murray, J. C. 2002. Gene/environment causes of cleft lip and/or palate. *Clinical genetics*, 61(4):248–256.
- Neville, B. W. 2015. Oral and Maxillofacial Pathology. page 928. Elsevier Health Sciences.
- Packiri, S. 2017. Management of Paediatric Oral Ranaula: A Systematic Review. *Journal of Clinical and Diagnostic Research*, 11(9):6–9.
- Panchal, V., Jeevanandan, G., Subramanian, E. G. 2019. Comparison of instrumentation time and obturation quality between hand K-file, H-files, and rotary Kedo-S in root canal treatment of primary teeth: A randomized controlled trial. *Journal of Indian Society of Pedodontics and Preventive Dentistry*, 37(1):75.
- Pindborg, J. J. 1965. Frequency of oral leukoplakias and related conditions among 10,000 Bombayites. Preliminary report. *The Journal of the All India Dental Association*, 37(7):228–229.
- Pinto, A., Haberland, C. M., Baker, S. 2014. Pediatric Soft Tissue Oral Lesions. *Dental Clinics of North America*, 58(2):437–453.
- Ramakrishnan, M., Bhurki, M. 2018. Fluoride, Fluoridated Toothpaste Efficacy And Its Safety In Children - Review. *International Journal of Pharmaceutical Research*, 10(04):109–114.
- Ravikumar, D., Jeevanandan, G., Subramanian, E. M. G. 2017. Evaluation of knowledge among general dentists in treatment of traumatic injuries in primary teeth: A cross-sectional questionnaire study. *European Journal of Dentistry*, 11(02):232–237.
- Shulman, J. D. 2005. Prevalence of oral mucosal lesions in children and youths in the USA. *International Journal of Paediatric Dentistry*, 15:89–97.
- Somasundaram, S. 2015. Fluoride Content of Bottled Drinking Water in Chennai, Tamilnadu. *Journal of clinical and diagnostic research*, 9(10):32–36.
- Subramanyam, D. 2018. Comparative evaluation of salivary malondialdehyde levels as a marker of lipid peroxidation in early childhood caries. *European journal of dentistry*, 12(1):67–70.
- Sudhakar, U. 2009. Periodontal status of cleft lip and palate patients - A case series. *Journal of Indian Association of Public Health Dentistry*, 7(13):99.
- Szabo, G. T. 2012. Comparative salivary proteomics of cleft palate patients. *The Cleft palate-craniofacial journal: official publication of the American Cleft Palate-Craniofacial Association*, 49(5):519–523.
- Ünür, M., Kayhan, K. B., Altop, M. S., Metin, Z. B., Keskin, Y. 2015. The Prevalence Of Oral Mucosal Lesions In Children: A Single Center Study. *Journal of Istanbul University Faculty of Dentistry*,

49(3):29.

Zainab, J., Salih, B. A. 2012. Oral health status and treatment needs among 3-12 years old children with cleft lip and/or palate in Iraq. *Journal of baghdad college of dentistry*, 24(4):145-151. Baghdad University.