



## Dental caries experience in patients with and without anterior crossbite: A case-control study

Kuzhalvaimozhi P<sup>1</sup>, Vignesh Ravindran<sup>\*2, 3</sup>, Subhashini V C<sup>3</sup>

<sup>1</sup>Saveetha Dental college and hospitals, Saveetha Institute of Medical and Technical Sciences, Saveetha University, Chennai-600 077, Tamil Nadu, India

<sup>2</sup>Department of Pediatric and Preventive Dentistry, Saveetha Dental college and hospitals, Saveetha Institute of Medical and Technical Sciences, Saveetha University, Chennai-600 077, Tamil Nadu, India

<sup>3</sup>Department of Public Health Dentistry, Saveetha Dental college and hospitals, Saveetha Institute of Medical and Technical Sciences, Saveetha University, Chennai-600 077, Tamil Nadu, India

### Article History:

Received on: 24 Jul 2020  
Revised on: 30 Aug 2020  
Accepted on: 21 Sep 2020

### Keywords:

Anterior crossbite,  
dental caries,  
oral hygiene measures

### ABSTRACT

Anterior crossbite is a type of malocclusion involving anteroposterior alignment, which results from an abnormal axial inclination of the anterior maxillary teeth. Dental caries is a chronic disease affecting patients and adults. Due to improper oral hygiene management in individuals with a crossbite, the incidence of caries could be higher. Hence a study was conducted to assess the dental caries status in patients with anterior crossbite and also compare with patients without anterior crossbite. The present study consisted of 56 patients divided into two groups: patients with anterior crossbite and patients without anterior crossbite. 89000 Case sheets were reviewed from the dental treatment records for DMFT index in patients with and without anterior crossbite from June 2019 to March 2020. In both groups, parameters such as Decayed- Missing - Filled (DMFT) score was recorded. Data were subjected to the Mann Whitney U test in SPSS software. Results showed higher DMFT score was seen in patients without anterior crossbite. Mean DMFT Index for case group (patients with anterior crossbite) is 2.04, and Mean DMFT Index for the control group (patients without anterior crossbite) is 2.93. The difference was not statistically significant (P-value - 0.072). Within the limitations of the study, dental caries status in patients with anterior crossbite is good compared with patients without anterior crossbite.



### \*Corresponding Author

Name: Vignesh Ravindran  
Phone: +91 9789934476  
Email: vigneshr.sdc@saveetha.com

ISSN: 0975-7538

DOI: <https://doi.org/10.26452/ijrps.v11iSPL3.3365>

Production and Hosted by

IJRPS | <https://ijrps.com>

© 2020 | All rights reserved.

### INTRODUCTION

Moyer defined anterior tooth crossbite as a dental malocclusion resulting from the abnormal axial inclination of anterior maxillary teeth. Anterior crossbite is highly prevalent during the mixed dentition period. Minor malocclusion is one of the major concerns for the orthodontist or pedodontist to help the developing dental structures of a child along with the growth of orofacial structures. Anterior crossbite can be dental or skeletal. Anterior dental crossbite could be due to palatal malposition of maxillary incisors due to its lingual eruption path. Other etiologies would include trauma to primary maxillary incisor causing lingual displacement of

the permanent tooth buds, crowding in the anterior region, supernumerary teeth like mesiodens, an over-retained deciduous root or tooth, delayed exfoliation of primary teeth and sometimes the presence of odontomas.

Habits and crossbite should be diagnosed, and if it is not self-correcting, they should be treated as fast as possible to achieve a normal occlusal relationship. The first notice of a crossbite is the best time to treat it. Anterior crossbite requires an immediate and effective treatment to prevent the mobility of anterior teeth and fracture and also prevent periodontal and temporomandibular disturbances (Valentine and Howitt, 1970). Dental caries is a multifactorial infectious microbial disease of the teeth which results in localised destruction and destruction of the calcified tissues which often results in cavitation. It is a dental public health problem which interferes with normal food intake, speech, self-esteem, and routine activities affecting the overall health status of the children. WHO reported a higher percentage of schoolchildren experienced dental caries and was most prevalent in Asian and American countries.

Depending upon the etiology of anterior crossbite; skeletal or dental, stage of dentition - mixed or permanent dentition, a variety of treatment approaches can be used to prevent, intercept or correct it. Treatment options would include tongue blade therapy, inclined plane, removable appliance with finger spring, maxillary 2 × 4 appliance, bonded - resin composite slopes, fixed orthodontic mechanotherapy or orthognathic surgical procedures. There are many advantages for 2 × 4 appliance. It includes ease of application, prevents malocclusion in an early stage, there is a minimal application of force when compared with conventional orthodontic treatment and minimal root resorption. It cannot be used for the correction of skeletal crossbite and requires patient cooperation (Becker et al., 2002). Anterior crossbite patients have difficulty in maintaining oral hygiene which tends to accumulate more plaque in that area subjecting to dental caries. So the aim of the current study was to assess the dental caries status in patients with anterior crossbite and to compare with patients without anterior crossbite and to create awareness about oral hygiene instructions among the patients.

## MATERIALS AND METHODS

This is a retrospective study. This study was carried out in a hospital-based university setting. This study was evaluated and ethically approved by an institutional ethical review committee ethical approval number:(SDC/SIHEC/2020/DIASDATA/0619-

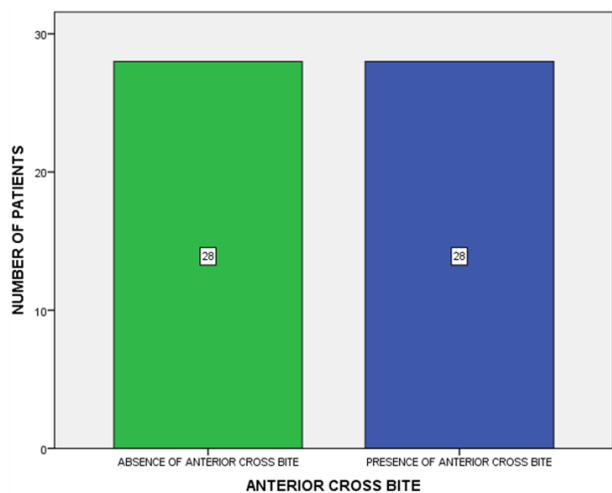
0320)". Retrospective data collected from 86,000 case records from June 2019 to March 2020. Informed consent was obtained from the parents or guardian before starting the treatment. Inclusion criteria were Patients with an anterior crossbite, patients aged from 11 to 30 years and patients without anterior crossbite (age, gender-matched control). Exclusion criteria were patients below 10 years of age, and above 30 years of age, incomplete available data and improper photographs.

Total cases acquired for this study was 56 patients which include 28 anterior crossbite patients and 28 age, gender-matched controls (patients without anterior crossbite). DMFT scores were collected for the patients with and without anterior crossbite. DMFT index describes the experience of dental caries in an individual. They were obtained by collecting the number of decayed, missing and filled teeth. The total sum of three figures forms the DMFT value. Selected case and control group were examined by three people; one reviewer, one guide and one researcher. Patient's case sheets were reviewed thoroughly. Cross-checking of data including digital entry and intraoral photographs was done by an additional reviewer, and as a measure to minimise sampling bias, samples for the group were picked by a simple random sampling method. A digital entry of clinical examination and intraoral photographs were assessed. Then, the DMFT score was entered into Microsoft Excel and then transferred into SPSS (Statistical Package For the Social Sciences) software for statistical results. A correlation test (Mann-Whitney U test) was done between the patients with anterior crossbite and patients without anterior crossbite. The difference was considered statistically significant when the p-value was less than 0.05.

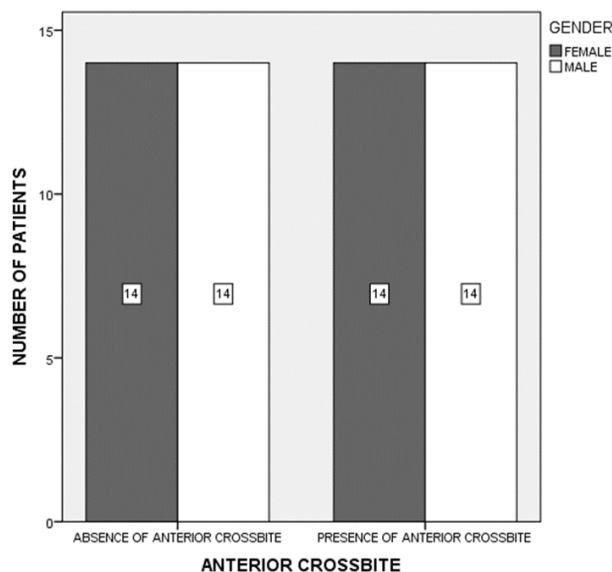
## RESULTS AND DISCUSSION

The final study sample size included a total of 56 patients with 28 patients with anterior crossbite (case group) and 28 patients without anterior crossbite (control group) [Figure 1]. In this study, the patients in the control group were age and gender-based as similar to the case group—[Figure 2]. The mean DMFT score of patients in the control group (without anterior crossbite) was 2.93. The mean DMFT score of patients in the case group (with anterior crossbite) was 2.04. The experience of dental caries was slightly higher in patients without anterior crossbite when compared to patients with an anterior crossbite, which was not statistically significant. (p = 0.072) (Case group (green) had slightly higher mean DMFT value (2.93) when com-

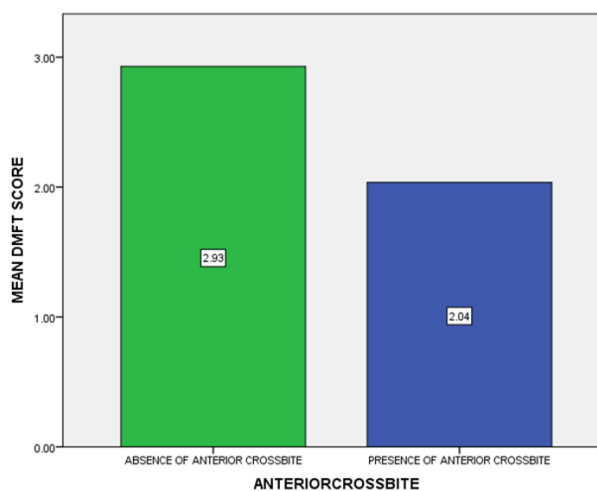
pared to control group (2.04) (blue) [Figure 3]. The Mean DMFT score of female patients without anterior crossbite was 3.14 and male patients without anterior crossbite were 2.71. Females with anterior crossbite had higher caries experience compared to males with or without anterior crossbite, which was not statistically significant. (p=0.094) (The Mean DMFT score of patients without anterior crossbite was higher in females (3.14) when compared to males (2.71)) [Figure 4].



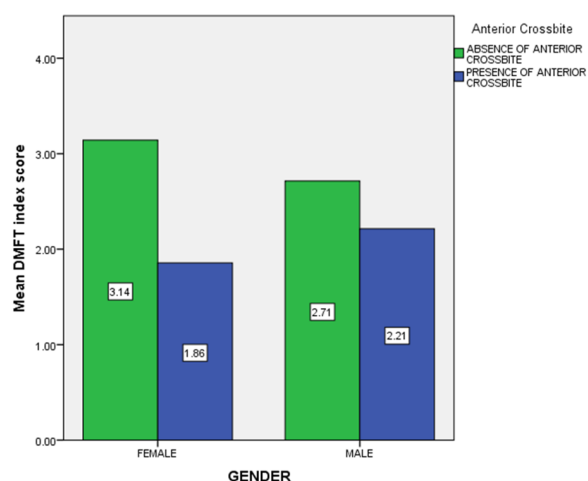
**Figure 1: The distribution of patients in the case (patients with anterior crossbite) and control (patients without anterior crossbite) group. There was an equal distribution of cases in both groups.**



**Figure 2: The gender-based distribution of cases in the case group (patients with anterior crossbite) and control group (patients without anterior crossbite). Notice the equal distribution of patients in both groups**



**Figure 3: Mean DMFT score for the case group and control group.**



**Figure 4: The comparison of the DMFT index score against the gender of patients in both groups.**

was a pandemic disease affecting all the population irrespective of gender, age, and socioeconomic status. Dental caries is more alarming in developing countries due to poor knowledge about the caries prevalence and its preventive measures. The progression of dental caries is influenced by microorganisms, diet, environmental and socioeconomic factors. Previous experience of dental caries, salivary and plaque concentration of S.mutans and lactobacilli, saliva's buffering capacity are a few indicators of caries risk. Loss of balance between the protective and the risk factors could result in selective growth of S.mutans and lactobacilli, which are the main culprits associated with dental caries. Studies done clinically have shown that dental caries is commonly associated with higher proportions of acidogenic and aciduric bacteria that are capable of demineralizing enamel (Becker et al., 2002). These

bacteria rapidly metabolize dietary sugars to acid. This creates a low pH environment, which helps the survival of these species. The other species of oral microflora are sensitive to low pH and cannot survive in it. Among the acidogenic and aciduric microflora, *S. mutans* has been strongly implicated with dental caries. The persistent pH drop in plaque after exposure to fermentable carbohydrates can be due to metabolic activity of increased number or acidogenic and aciduric bacteria on the tooth surface. These are particularly efficient carbohydrate fermenters such as *S. mutans* or *S. sobrinus*.

Several investigations have shown the association of *S. mutans* colonization levels with the incidence rate of dental caries. Sanchez - Perez et al. verified such association using the microbial level in the dental biofilm with active caries. Matee et al. also found a significant relationship but also concluded that the presence of cariogenic bacteria does not mean high caries activity due to its higher numbers in cariogenic children too. Anterior crossbite is the lingual positioning of the maxillary anterior in relation to the mandibular anterior. The ideal time for the correction would be between 8 to 11 years because root formation is completed and the presence of active phase of the eruption. Space loss for the eruption of maxillary incisors is the most common cause of anterior dental crossbite.

In a young child, the best method is a removable appliance (Hawley's appliance) with finger springs (Prakash and Durgesh, 2011). Treatment by means of Hawley's appliance with finger spring helps in the maintenance of good oral hygiene. The success of therapy completely depends on patients' cooperation. Tongue blade therapy is indicated in case of erupting crossbite. However, the success of therapy depends on patients' cooperation and it has one disadvantage. Amount and direction of force applied cannot be controlled. The Catalan's appliance is a fixed appliance which uses resin slopes for anterior crossbite correction. Advantages of this appliance include a rapid and easy alternative method and disadvantage include difficulty in speech and mastication (Lee, 1978; Ulu-soy and Bodrumlu, 2013). For the removable appliance, there should be 4mm thickness of acrylic. An increased and unnecessary amount of bite opening may cause alteration of the vertical relationship and also decreases the patient's compliance. Duration of treatment for removable appliances varies from 6 to 12 weeks.

Good attitude of parents reflects good oral health in children and vice versa (Gurunathan and Shanmugaavel, 2016). Preservation of primary teeth

in the dental arch is important to guide the eruption of the permanent teeth in the optimal position. Grossly decayed primary teeth which are extracted before exfoliation causes space in the dental arch which causes malocclusion if space maintainer was not given (Ravikumar et al., 2017; Panchal et al., 2019). Bacteria play a vital role in the initiation and progression of dental caries which eventually causes pulpal and periapical disease (Jeevanandan, 2017). Saliva plays an important role in maintaining the oral health of an individual (Subramanyam et al., 2018; Govindaraju et al., 2017a; Lakshmanan, 2020). Untreated dental caries leads to pulpitis which is treated by means of root canal procedure - pulpectomy (Govindaraju et al., 2017b,c; Jeevanandan and Govindaraju, 2018). Fluoride and proper oral hygiene methods use has been recommended to prevent dental caries (Ramakrishnan and Bhurki, 2018; Somasundaram, 2015; Govindaraju and Gurunathan, 2017). Thus, intensive oral hygiene measures have to be taken along with orthodontic treatment for anterior crossbite patients (Packiri et al., 2017; Christabel, 2015).

Advantages of this study were that this was a case-control study with age and gender-matched controls to provide the best results with high internal validity, reasonable data. Limitations of the present study were that this was a unicentric study with geographic limitations, limited sample size and had lower external validity. The dietary factors, feeding and oral hygiene factors were not taken into consideration while interpreting the results. Future scope for this study includes a larger sample size which is not confined to a particular geographic area and to assess the dental caries index by clinically examining the anterior crossbite patients.

## CONCLUSION

Within the limitations of the present study, dental caries experience in patients with anterior crossbite was better when compared to patients without anterior crossbite. However, proper oral hygiene measures should be reinforced in patients despite the presence or absence of anterior crossbite to reduce dental morbidity.

## ACKNOWLEDGEMENT

The authors of this study acknowledge the institute, for their help towards collecting all the patient case records and other data in relevance to the current study.

## Conflict of Interest

The authors declare that there are no conflicts of

interest for this study.

### Funding Support

The authors declare that they have no funding support for this study.

### REFERENCES

- Becker, M. R., *et al.* 2002. Molecular analysis of bacterial species associated with childhood caries. *Journal of clinical microbiology*, 40(3):1001–1009.
- Christabel, S. L. 2015. Prevalence of Type of Frenal Attachment and Morphology of Frenum in Children, Chennai, Tamil Nadu. *World Journal of Dentistry*, 6(4):203–207.
- Govindaraju, L., Gurunathan, D. 2017. Effectiveness of Chewable Tooth Brush in Children-A Prospective Clinical Study. *Journal of Clinical and Diagnostic Research*, 11(3):31–34.
- Govindaraju, L., Jeevanandan, G., Subramanian, E. 2017a. Clinical Evaluation of Quality of Obturation and Instrumentation Time using Two Modified Rotary File Systems with Manual Instrumentation in Primary Teeth. *Journal of clinical and diagnostic research*, 11(9):55–58.
- Govindaraju, L., Jeevanandan, G., Subramanian, E. M. G. 2017b. Comparison of quality of obturation and instrumentation time using hand files and two rotary file systems in primary molars: A single-blinded randomized controlled trial. *European Journal of Dentistry*, 11(3):376–379.
- Govindaraju, L., Jeevanandan, G., Subramanian, E. M. G. 2017c. Knowledge and practice of rotary instrumentation in primary teeth among Indian dentists: A questionnaire survey. *Journal of International Oral Health*, 9(2):45. Medknow Publications and Media Pvt. Ltd.
- Gurunathan, D., Shanmugaavel, A. K. 2016. Dental neglect among children in Chennai. *Journal of Indian Society of Pedodontics and Preventive Dentistry*, 34(4):364–369.
- Jeevanandan, G. 2017. Kedo-S Paediatric Rotary Files for Root Canal Preparation in Primary Teeth – Case Report. *Journal of Clinical and Diagnostic Research*, 11(3):3–5.
- Jeevanandan, G., Govindaraju, L. 2018. Clinical comparison of Kedo-S paediatric rotary files vs manual instrumentation for root canal preparation in primary molars: a double blinded randomised clinical trial. *European Archives of Paediatric Dentistry*, 19(4):273–278.
- Lakshmanan, L. 2020. Assessing the quality of obturation and instrumentation time using Kedo-S files, Reciprocating files and Hand K-files. *Brazilian Dental Science*, 23(1):1–7.
- Lee, B. D. 1978. Correction of crossbite. *Dental clinics of North America*, 22(4):647–668.
- Packiri, S., Gurunathan, D., Selvarasu, K. 2017. Management of Paediatric Oral Ranula: A Systematic Review. *Journal of Clinical and Diagnostic Research*, 11(9):6–9.
- Panchal, V., Jeevanandan, G., Subramanian, E. M. G. 2019. Comparison of instrumentation time and obturation quality between hand K-file, H-files, and rotary Kedo-S in root canal treatment of primary teeth: A randomized controlled trial. *Journal of Indian Society of Pedodontics and Preventive Dentistry*, 37(1):75–79.
- Prakash, P., Durgesh, B. H. 2011. Anterior Crossbite Correction in Early Mixed Dentition Period Using Catlan's Appliance: A Case Report. *ISRN Dentistry*, 2011:1–5.
- Ramakrishnan, M., Bhurki, M. 2018. Fluoride, Fluoridated Toothpaste Efficacy And Its Safety In Children - Review. *International Journal of Pharmaceutical Research*, 9(3):109–114.
- Ravikumar, D., Jeevanandan, G., Subramanian, E. M. G. 2017. Evaluation of knowledge among general dentists in treatment of traumatic injuries in primary teeth: A cross-sectional questionnaire study. *European Journal of Dentistry*, 11(2):232–237.
- Somasundaram, S. 2015. Fluoride Content of Bottled Drinking Water in Chennai, Tamilnadu. *Journal of Clinical and Diagnostic Research*, 9(10):32–34.
- Subramanyam, D., *et al.* 2018. Comparative evaluation of salivary malondialdehyde levels as a marker of lipid peroxidation in early childhood caries. *European Journal of dentistry*, 12(1):67–70.
- Ulusoy, A. T., Bodrumlu, E. H. 2013. Management of anterior dental crossbite with removable appliances. *Contemporary Clinical Dentistry*, 4(2):223–226.
- Valentine, F., Howitt, J. W. 1970. Implications of early anterior crossbite correction. *ASDC journal of dentistry for children*, 37(5):420–427.