



## Aflibercept or ranibizumab for the treatment of diabetic macular edema; A retrospective study

Khlood M. Aldossary<sup>\*1</sup>, Anfal Alruzuq<sup>2</sup>, Ghady Almohanna<sup>2</sup>, Hessa Almusallam<sup>2</sup>, Sara Alamri<sup>2</sup>, Fatima Alshehri<sup>2</sup>, Arwa Alzahrani<sup>2</sup>, Attiqa Chaudhary<sup>3</sup>

<sup>1</sup>Pharmacy Practice, Pharmacy College, Princess Nourah Bint Abdulrahman University, Riyadh - 11671, Saudi Arabia

<sup>2</sup>Pharmacy College, Princess Nourah bint Abdulrahman University, Riyadh - 11671, Saudi Arabia

<sup>3</sup>Ophthalmology Department Security Forces Hospital, Riyadh - 11671, Saudi Arabia

### Article History:

Received on: 06.03.2019

Revised on: 13.06.2019

Accepted on: 17.06.2019

### Keywords:

Diabetic macular edema,  
Efficacy,  
Aflibercept,  
Ranibizumab

### ABSTRACT

Diabetic macular edema (DME) is a significant cause of diabetic retinopathy and a major cause of vision loss. In this study, we aimed to evaluate and compare the efficacy of two injectable drugs; intravitreal Aflibercept and intravitreal Ranibizumab for the treatment of DME of the eyes. A retrospective chart review was conducted for patients diagnosed with DME from March 2014 to January 2019 who received either intravitreal Aflibercept or intravitreal Ranibizumab injection. A total of 57 eyes were included, of which 19 eyes were treated with intravitreal Ranibizumab injection, and 38 eyes were treated with intravitreal Aflibercept injection; all eyes were examined for 3 months. Two outcomes were assessed in this study, namely; visual acuity (VA) and central macular thickness (CMT). The mean age in the Ranibizumab group was  $61.1 \pm 9.5$  vs  $64.3 \pm 10.2$  in the Aflibercept group with no significant difference ( $p$ -value=0.25). The ratio of improvement in visual acuity (VA) in the Ranibizumab group was 68.4% vs 44.7% in the Aflibercept group; ( $p$ -value=0.038) which demonstrates the superiority of Ranibizumab over Aflibercept concerning visual acuity result. However, there is no statistically significant difference between the ratio of improvement in central macular thickness (CMT) results in both groups; ( $p$ -value=1.00). In fact, the ratio of improvement in CMT in both groups was the same 78.9% for both the groups. However, Ranibizumab is superior in improving visual acuity compared to Aflibercept. Further comparative effectiveness trials between Aflibercept and Ranibizumab are still warranted.



### \*Corresponding Author

Name: Khlood M. Aldossary

Phone:

Email: [Kmalossary@pnu.edu.sa](mailto:Kmalossary@pnu.edu.sa)

ISSN: 0975-7538

DOI: <https://doi.org/10.26452/ijrps.v10i4.1586>

Production and Hosted by

IJRPS | <https://ijrps.com>

© 2019 | All rights reserved.

### INTRODUCTION

Diabetic Macular Edema is the most significant vascular complication among diabetic patients that could lead to blindness if it remains untreated. Ophthalmic problems such as corneal abnormalities, glaucoma, iris neovascularization, cataracts, and neuropathies are generally very common among diabetic patients (Cohen *et al.*, 2016). However, the condition of DME is of much concern as if untreated. It can cause vision loss among diabetic patients (Cohen *et al.*, 2016; Ciulla *et al.*, 2003).

DME occurs as the advantage stage of diabetic

retinopathy that is characterized by abnormal growth of blood vessels within retina for compensating the oxygen demand of ischemic retina. If remain untreated or progressive, it may lead to DME, which further involves retinal thickening in the macular area (Ciulla *et al.*, 2003). Hypothesis and literature proposed that expanded penetrability of retinal veins permit exudation and gathering of extracellular liquid in the retinal layers which further breakdown the blood-retinal layer because of expanded vascular porousness and which further prompts pathogenesis and development of Macular Edema (Dugel *et al.*, 2016; Shah and Heier, 2016).

The treatment strategies of DME have evolved in the recent times and with the advancement in techniques and with further clarification of pathophysiology intravitreal injections of vascular endothelial growth factor (VEGF) antibodies are becoming preferable for the treatment worldwide (Călugăru and Călugăru, 2016).

Aflibercept, bevacizumab, and ranibizumab are anti-VEGF agents who are reported to be effective for the treatment however only aflibercept and ranibizumab have been approved by Food and Drug Administration (FDA) for the treatment of DME (Nguyen *et al.*, 2012, 2010). The mode of action of these 2 drugs is different; however, they both act on VEGF and improve visual acuity. However, ranibizumab binds to all the isoforms of human VEGF-A while aflibercept binds to all isoforms of VEGF-A, VEGF-B, and placental growth factor (Ophthalmology, 2007; Ishibashi *et al.*, 2015; Korobelnik *et al.*, 2014; Mitchell *et al.*, 2011).

In the recent times, various clinical trials and observational studies approved the efficacy of these injectable drugs, for instance, Sameh Mosaad Fouda et al. in 2017 reported that in patients with moderate vision loss there was no difference in the efficacy of intravitreal aflibercept and ranibizumab in the treatment of diabetic macular edema (DME) (Fouda and Bahgat, 2017). Few studies (Rhoades *et al.*, 2017; Oshitari *et al.*, 2016) have reported efficacy of one drug more than the other for instance Norihiro Shimizu et al. in 2017 reported that for best-corrected visual acuity and for reducing central macular thickness (CMT) in eyes with DME intravitreal aflibercept as more effective compared to ranibizumab (Oshitari *et al.*, 2016). Likewise, Wykoff CC et al. in 2014 conducted a clinical trial, reported superiority of aflibercept by stating that 2.0 mg treatment with aflibercept maintained mean visual acuity improvements in recalcitrant exudative age-related macular degeneration patients (Wykoff *et al.*, 2014).

By keeping into the consideration of the differences in the efficacy of aflibercept and ranibizumab, we aimed to compare the effectiveness of aflibercept and ranibizumab for the treatment of DME in eyes among diabetic patients.

## MATERIALS AND METHODS

### Study setting and study design

A retrospective chart review was conducted for patients diagnosed with DME to compare the efficacy of intravitreal aflibercept and ranibizumab. The data were collected from the Security Forces Hospital and King Faisal Specialist Hospital & Research Center in the ophthalmology clinics, Riyadh, Saudi Arabia.

### Population and Study Sample

Diabetic patients reported with DME from March 2014 to January 2019 who received either intravitreal Aflibercept or intravitreal Ranibizumab injection were recruited for this study. A total of 57 eyes were included, 19 eyes were treated with intravitreal ranibizumab injection of 0.5 mg/0.1 mL (Group A) and 38 eyes treated with intravitreal aflibercept injection of 2 mg/0.05 mL (Group B). Visual acuity (VA) and central macular thickness (CMT) were reported for each eye at 3 months.

### Ophthalmic examination

All patients got a complete ophthalmic examination, including measurement of BCVA, slit-lamp examination, and dilated fundus examination. Heidelberg Spectralis-OCT (Heidelberg Engineering, Heidelberg, Germany) was performed for all eyes for macular examination. Macular thickness map with follow-up software used to detect and measure the changes in central macular thickness (CMT).

### Procedure for intravitreal injection

All the patients received either aflibercept (Eylea) or ranibizumab (Lucentis) at baseline and every month for 3 months as three intravitreal injections are needed as a loading dose. In case of persistent macular edema or worsening of the visual acuity or the CMT patients were reinjected with the Anti-VEGF agent. Before giving the intravitreal injection, both groups A and B received topical anesthesia (0.4% Benoxinate eye drops). The anti-VEGF agent was injected by using 27 gauge needle into the vitreous cavity. Patients were evaluated for vision performance at the end of the procedure. All patients were monitored every month for 3 months, and BCVA and CMT were reported at baseline and at follow up visits.

### Inclusion and Exclusion criteria

We included only those patients who have type I and II diabetes. Patients having clinically diagnosed and OCT (optical coherence tomography) diagnosed DME. Best-corrected visual acuity (BCVA) was ranged from 0.1 to 0.25, and having central edema of 1 mm. We only included those patients who had to follow up of at least 3 months. We excluded all the eyes with vascular retinal disorders other than diabetic retinopathy (e.g., choroidal neovascularization). We also excluded those who have received intravitreal injection previously and have a history of intraocular surgery. We also excluded patients with proliferative diabetic retinopathy and having edema of more than 1 mm (Figure 1).

### Ethics and Human Subjects Issues

All participants included in the study have provided oral and written consent. Name and any identification of patients were kept in privacy, and all the findings are reported without indicating the identity of any individual. Data were collected after taking ethical approval from the respective committee.

### Statistical analysis

We used SPSS version 20 for data analysis. Data were cleaned and checked for missing values before data analysis. Frequency and percentages are reported for categorical variables like gender and mean and standard deviation for continuous variable. Chi-square test was used to test the difference in improvement rate between the two drugs. Findings are present in tabular and graphical form. Paired t-test was used to test the difference between pre and post values for each drug. Any test was considered significant for p-value equal and less than 0.05.

## RESULTS AND DISCUSSION

Table 1 demonstrated baseline characteristics of the study population. The mean age in Group A was  $61.1 \pm 9.5$  while it was  $64.3 \pm 10.2$  in Group B, with no significant difference (p-value = 0.25). The two groups had nearly the same distribution of characteristics concerning age, gender, injected eye, medication and DME duration.

Table 2 demonstrated an improvement in visual acuity among the two groups. Our results demonstrated that group A receiving Ranibizumab has a significantly higher number of improved cases compared to group B, that is 68.4% compared to 44.7% respectively. Also, the ratio of worsened eyes was only 5.3% in Ranibizumab group while it was 36.8% in the Aflibercept group. However, no difference was found between the ratio of improvement in CMT results in both groups at p-value=1.00. (Table 2)

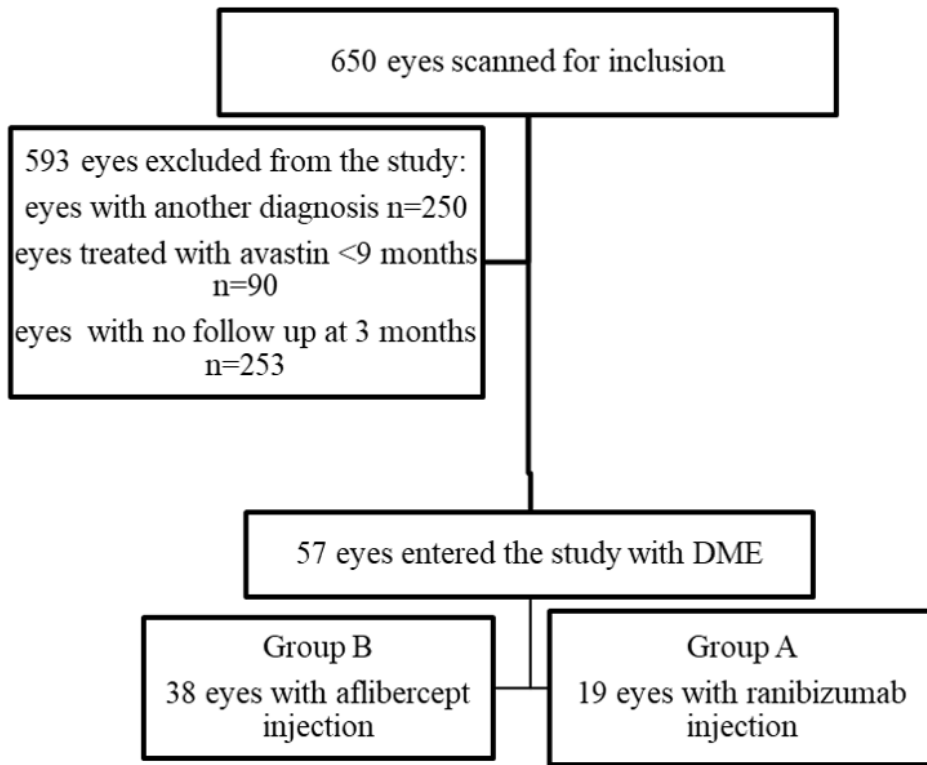
Table 3 demonstrated that for both groups, there was a significant decrease in CMT values post-treatment with p-value 0.009 and 0.001 for Group A and B respectively while only the Group A showed a significant increase in VA values post-treatment (pre: 0.26 vs post: 0.41, p-value: 0.001).

The present study aimed to evaluate and compare the two drugs, intravitreal Aflibercept and Ranibizumab in the treatment of diabetic macular edema (DME) in the eyes. This study reported the superiority of Ranibizumab over Aflibercept concerning VA improvement as the improvement in VA was significantly higher in the group treated by Ranibizumab compared to the group treated by Aflibercept. As for improvement in CMT, both groups showed the same performance with no major difference between the two groups and improvement in the eyes was same for both groups. This result are in line with the findings of the study conducted by Sameh Mosaad Fouda et al (Fouda and Bahgat, 2017) who found same effect between the two drugs concerning CMT improvement however that study also reported no difference between the two drugs concerning VA improvement which is in contrast to the findings of our study.

The superiority of Ranibizumab over Aflibercept concerning VA improvement concluded by the present study is different from some studies which concluded the superiority of Aflibercept over Ranibizumab such as (Wykoff et al., 2014; Oshitari et al., 2016; Rhoades et al., 2017) The differences could be because of type of study design, sample size and baseline characteristics of the participants.

A study conducted by Wells et al. reported the differences in the drug efficacy could be because of the difference in baseline visual acuity however we took all the participants with visual acuity between 0.25 - 1 for which most of the studies have shown improvement post-treatment from Aflibercept compared to other Anti-VEGF agents. (Heier et al., 2016; Network et al., 2015). In contrary to the findings of the aforementioned studies, our study found Ranibizumab superior in improving visual acuity compared to Aflibercept.

The findings of this study should be concluded by keeping in mind the following limitations; 1: small sample size because of this, we cannot generalize the findings of our study. Secondly, both the groups were having a different number of participants as the nature of the study design was retrospective. We could only include available data. Although many clinical trials have been done in recent years showing the efficacy of one drug over the other while keeping in consideration the findings of current



**Figure 1: Flow**

**Table 1: Baseline characteristics of study population (n=57)**

Baseline characteristics		Group A (n=19)		Group B (n=38)	
		n	%	n	%
Age	40-49	2	10.5	3	7.9
	50-59	7	36.8	9	23.7
	60-69	6	31.6	12	31.6
	70-80	4	21.1	14	36.8
Gender	Male	13	68.4	23	60.5
	Female	6	31.6	15	39.5
Injected eye	Right eye	9	47.4	21	55.3
	Left eye	10	52.6	17	44.7
Medication	Oral hypoglycemic agent (OHA)	4	21.1	12	31.6
	Insulin	8	42.1	14	36.8
	Combination therapy (OHA+ Insulin)	7	36.8	12	31.6
DME duration	<10 years	1	5.3	3	7.9
	>10 years	18	94.7	35	92.1

**Table 2: Improvement in visual acuity and CMT among both groups**

Improvement in	Group A (n=19)		Group B (n=38)		p-value
	n	%	n	%	
Worsen	1	5.3	14	36.8	0.038*
Not improved	5	26.3	7	18.4	
Improved	13	68.4	17	44.7	
Improvement in CMT result					
Worsen	4	21.1	8	21.1	1.00
Improved	15	78.9	30	78.9	

**Table 3: Pre and post Changes in VA and CMT among both groups**

Changes in VA and CMT	Group A (n=19)		Group B (n=38)	
	Mean	SD	Mean	SD
Pre CMT	422.00	168.70	418.05	108.74
Post CMT	334.21	129.25	339.82	100.26
p-value	0.009*		0.001*	
Pre VA	0.26	0.18	0.55	0.29
Post VA	0.41	0.20	0.56	0.28
p-value	0.001*		0.84	

studies we would suggest further trials with large sample size and reasonable follow up period should be conducted for comparing the effectiveness of various Anti-VEGF agents.

**CONCLUSION**

Through this study, we concluded that both the drugs are beneficial for improving visual acuity (VA) and for reducing central macular thickness (CMT) in eyes with DME. However, Ranibizumab is superior in improving visual acuity compared to Aflibercept. Further clinical trials between Aflibercept and Ranibizumab are still warranted.

**ACKNOWLEDGEMENT**

Aljawhara Abdulaziz Altaweel, MD, Consultant Ophthalmology, Ophthalmology Department

Security Forces Hospital, Riyadh, KSA

Email: dr.johara@hotmail.com

This research was funded by the Deanship of Scientific Research at Princess Nourah bint Abdulrahman University through the Fast-track Research Funding Program.

**REFERENCES**

Călugăru, D., Călugăru, M. 2016. Conversion to Aflibercept After Prior Anti-VEGF Therapy for Persistent Diabetic Macular Edema. *American Journal*

*of Ophthalmology*, 168:290–291.  
 Ciulla, T. A., Amador, A. G., Zinman, B. 2003. Diabetic Retinopathy and Diabetic Macular Edema: Pathophysiology, screening, and novel therapies. *Diabetes Care*, 26(9):2653–2664.  
 Cohen, S. R., Gardner, T. W., Zinman, B. 2016. Diabetic Retinopathy and Diabetic Macular Edema. *Retinal Pharmacotherapeutics*, 55:137–146.  
 Dugel, P., Hillenkamp, J., Sivaprasad, S., Vögeler, J., Mousseau, M. C., Wenzel, A., Massin, P. 2016. Baseline visual acuity strongly predicts visual acuity gain in patients with diabetic macular edema following anti-vascular endothelial growth factor treatment across trials. *Clinical Ophthalmology*, 1103.  
 Fouda, S. M., Bahgat, A. M. 2017. Intravitreal aflibercept versus intravitreal ranibizumab for the treatment of diabetic macular edema. *Clinical Ophthalmology*, 11:567–571.  
 Heier, J. S., Bressler, N. M., Avery, R. L., Bakri, S. J., Boyer, D. S., Brown, D. M. 2016. Comparison of Aflibercept, Bevacizumab, and Ranibizumab for Treatment of Diabetic Macular Edema. *JAMA Ophthalmology*, 134(1):95–99.  
 Ishibashi, T., Li, X., Koh, A., Lai, T. Y. Y., Lee, F. L., Lee, W. K., Yau, C. L. 2015. The REVEAL Study: Ranibizumab Monotherapy or Combined with Laser versus Laser Monotherapy in Asian Patients with Diabetic Macular Edema. *Ophthalmology*, 122(7):1402–1415.

- Korobelnik, J. F., Do, D. V., Schmidt-Erfurth, U., Boyer, D. S., Holz, F. G., Heier, J. S., Brown, D. M. 2014. Intravitreal Aflibercept for Diabetic Macular Edema. *Ophthalmology*, 121(11):2247–2254.
- Mitchell, P., Bandello, F., Schmidt-Erfurth, U., Lang, G. E., Massin, P., Schlingemann, R. O., Weichselberger, A. 2011. The RESTORE Study: Ranibizumab Monotherapy or Combined with Laser versus Laser Monotherapy for Diabetic Macular Edema. *Ophthalmology*, 118(4):615–625.
- Network, W. A. J., Glassman, A. R., Ayala, A. R., Jampol, L. M., Aiello, L. P., Beck, R. W. 2015. Aflibercept, bevacizumab, or ranibizumab for diabetic macular edema. *The New England Journal of Medicine*, 372(13):1193–1203.
- Nguyen, Q. D., Brown, D. M., Marcus, D. M., Boyer, D. S., Patel, S., Feiner, L., Ehrlich, J. S. 2012. Ranibizumab for Diabetic Macular Edema. *Ophthalmology*, 119(4):789–801.
- Nguyen, Q. D., Shah, S. M., Khwaja, A. A., Channa, R., Hatf, E., Do, D. V., Campochiaro, P. A. 2010. Two-Year Outcomes of the Ranibizumab for Edema of the macula in Diabetes (READ-2) Study. *Ophthalmology*, 117(11):2146–2151.
- Ophthalmology 2007. A Phase II Randomized Clinical Trial of Intravitreal Bevacizumab for Diabetic Macular Edema. 114:1860–1867.
- Oshitari, T., Shimizu, N., Tatsumi, T., Takatsuna, Y., Arai, M., Sato, E., Yamamoto, S. 2016. Comparison of efficacy of intravitreal ranibizumab and aflibercept in eyes with diabetic macular edema. *Acta Ophthalmologica*, 94:10–1111.
- Rhoades, W., Dickson, D., Nguyen, Q., Do, D. 2017. Management of macular edema due to central retinal vein occlusion – The role of aflibercept. *Taiwan Journal of Ophthalmology*, 7(2):70.
- Shah, C., Heier, J. 2016. Aflibercept for Diabetic Macular Edema in Eyes Previously Treated With Ranibizumab and/or Bevacizumab May Further Improve Macular Thickness. *Ophthalmic Surg Lasers Imaging Retina*. 47:836–839.
- Wykoff, C. C., Brown, D. M., Maldonado, M. E., Croft, D. E. 2014. Aflibercept treatment for patients with exudative age-related macular degeneration who were incomplete responders to multiple ranibizumab injections (TURF trial). *British Journal of Ophthalmology*, 98(7):951–955.