



# INTERNATIONAL JOURNAL OF RESEARCH IN PHARMACEUTICAL SCIENCES

Published by JK Welfare &amp; Pharmascope Foundation

Journal Home Page: <https://ijrps.com>

## Correlation of age and gender with the site of occurrence of oral squamous cell carcinoma

Casilda Sushanthi L, Hannah R\*, Pratibha Ramani, Gheena S, Abilasha Ramasubramaniam

Department of Oral Pathology, Saveetha Dental College and Hospital, Saveetha Institute of Medical and Technical Sciences, Saveetha University, Chennai-600077, Tamil Nadu, India



### Article History:

Received on: 21 Jun 2020

Revised on: 20 Jul 2020

Accepted on: 26 Jul 2020

### Keywords:

Oral squamous cell carcinoma, age, gender, site of the lesion

### ABSTRACT

Oral squamous cell carcinoma (OSCC) is the most occurring cancer of the oral cavity showing changes based on-site, sex, age and habits of the population. The purpose of the study is to correlate the occurrence of oral squamous cell carcinoma at specific anatomical sites with age and gender. The present study is a retrospective study, including data from June 2019 to April 2020. Data of 50 OSCC patients including age, gender, site of the lesion, the onset of symptoms, treatment done, were collected, tabulated and then statistically analyzed. Results revealed that buccal mucosa was the most common site of occurrence in males (61.50%): Correlation of gender with the location of oscc was statistically not significant with a p-value higher than 0.05. Regarding the association of age with a site of oscc occurrence, buccal mucosa was the common site of involvement in individuals below 50 years of age (54.50%), followed by tongue 23.50% and 21% in above 50 years of age. Correlation of age with the site of oscc occurrence was statistically insignificant ( $p > 0.05$ ). Within the limits of the study, it can be concluded that the site of occurrence of OSCC is more governed by habits involved than age and gender itself. But an investigation involving a larger population would give a more comprehensive outcome.

### \*Corresponding Author

Name: Hannah R

Phone:

Email: [hannahr.sdc@saveetha.com](mailto:hannahr.sdc@saveetha.com)

ISSN: 0975-7538

DOI: <https://doi.org/10.26452/ijrps.v11iSPL3.2893>

Production and Hosted by

IJRPS | <https://ijrps.com>

© 2020 | All rights reserved.

### INTRODUCTION

Oral squamous cell carcinoma (OSCC) is the most occurring malignancy of the oral cavity, showing geographical changes with respect to the sex site, age and habits of the population. Oral cancer is an important factor of mortality and morbidity world-

wide which has an incidence rate that varies globally by geographic location. OSCC is a significant health concern globally mainly in developing countries (Jayaraj *et al.*, 2015a). Squamous cell carcinoma in India has a high incidence rate of 30-40% and has a high mortality rate (Jayaraj, 2015). Oral cancer presents as a growth or sore in the mouth that does not disappear. Oral cancer which includes cancers of the lips, tongues, floor of the mouth, buccal mucosa, hard and soft palate, sinuses and pharynx, can be life-threatening if not diagnosed and treated early. While OSCC may arise *de novo*, most of the malignancy is contributed by the presence of clinically visible changes of oral mucosa which have a potential for malignant transformation (Sridharan *et al.*, 2017).

The high incidence of OSCC is also associated with increased tobacco usage (Shree, 2019). Tobacco is the leading risk factor for early death globally. Nearly sixty toxic chemicals present in tobacco can

enter the body system and play a role in OSCC development (Jiang, 2019). Ankyloglossia has an association with congenital disorders like Van der Woude syndrome. Still, it has no significant role in OSCC development (Jangid, 2015) OSCC also has a high incidence for lymph node metastasis, because of rich lymphatic communications. This influences the survival rate of OSCC patients with lymph node metastasis by decreasing the survival rate (Fan, 2011). OSCC with lymph node involvement has high recurrence rates (Suresh, 2019).

Recent studies on molecular genetics provide evidence that most of all head and neck squamous cell carcinomas start within a field of pre-neoplastic cells (Gupta and Ramani, 2016). Subtypes of OSCC have been known to have a maximum propensity for regional spread (Viveka, 2016). Salivary metabolomics has a significant role in identifying tumour specific biomarkers which provide insight regarding early tumour detection and progression (Sridharan, 2019). The purpose of the study is to correlate the occurrence of oral squamous cell carcinoma at specific anatomical sites with age and gender.

## MATERIALS AND METHODS

This retrospective study covers the period from June 2019 -march 2020. n=50 cases of clinically confirmed cases of OSCC were selected. Ethical approval was given by the scientific review board of Saveetha Dental College and Hospitals, Chennai. Patient details including age, gender, lesion site, clinical diagnosis and treatment done were collected from DIAS (Data Integration and Analysis System). The number of people involved in the study was one guide, one researcher and one reviewer.

Dependent variables were age and gender of the patients and lesion site. Independent variables were habits, symptom onset, treatment done and follow up. Inclusion criteria were clinically confirmed cases of OSCC. Patients with no follow-up history were excluded from the study. Data verification of the patients was done by photographic verification retrieved from DIAS. All the data were entered and tabulated using Microsoft Excel 2016. Karl Pearson's chi-square test was done to identify the Correlation of age and gender with the site of OSCC occurrence using SPSS version 23 by IBM. P-value  $\leq$  0.05 was considered to be statistically significant.

## RESULTS AND DISCUSSION

The study revealed that the most significant number of oscc develops in the fourth to fifth decade of

life Figure 1, with standard prediction in males than females. Chi square analysis showing nosignificance between age and site of occurrence of SCC (p value = .177) Figure 2.

Chi square analysis showing no significance between gender and site of occurrence of SCC.(pvalue= .590) Overall, the study result revealed that the common site for oscc occurrence was the buccal mucosa (40%) followed by the tongue (22%), retromolar region (16%), lower jaw (12%) and alveolus (10%) Figure 3. Karl Pearson's correlation coefficient was calculated to find the degree of association between gender to the site of the lesion, age to the site of a lesion which was found to be statistically not significant (p>0.05).

The study result showed that occurrence of buccal mucosa in individuals above 50 years of age was common. Most patients in this study were in their 4th and 5th decades of life, which follows literature by (Shiboski *et al.*, 2007). (Patel, 2011), showed a high incidence of OSCC among white female, young individuals in the age group of 18-44 years, indicating that there may be an increase in the emergence of head and neck cancers in young individuals due to tobacco usage. Considering all the oral anatomical sites, buccal mucosa was the most frequent site (40%), which is in accordance with the literature by (Salian, 2016). (Tandon, 2017), also states that the most common oscc site cases buccal in both men (59.5%) and women (40.4%) which is in accordance with our study. The frequency of OSCC lesions in this site has greater relevance to tobacco habit. 45.45% of females in our study were below 50 years of age, with no exposure to tobacco. Hence, genetic and hereditary assessment in patients with no association with tobacco should be done to get a conclusive result (Chandra, 2013). The clinical data of the patients were verified by photographs obtained from DIAS, which emphasizes the role of dental photography (Hannah, 2018).

Followed by buccal mucosa, the tongue is the next common site to be affected (22%) in the age group above 50 years. Previous studies stated that the lateral border of the tongue is the most common site of OSCC among Europe and The United States population (Warnakulasuriya, 2009). Another study conducted by (Pires, 2013), also shows that the border of the tongue is the most affected anatomical site in the oral cavity. Oral tongue squamous cell carcinoma (OTSCC), a subtype of cancer is associated with poor therapeutic outcome and survival rates. OTSCC occurs due to extracellular matrix degradation and epithelial to mesenchyme transition (Thangaraj, 2016). In our study, it is found

that buccal mucosa was the predominant site in men (40%) and also in age groups above 50 years age (22%). This variation in the site of oscc occurrence in age and gender groups could be contributed by lifestyle and cultural differences of different ethnic groups and also the biological mechanism of oscc development.

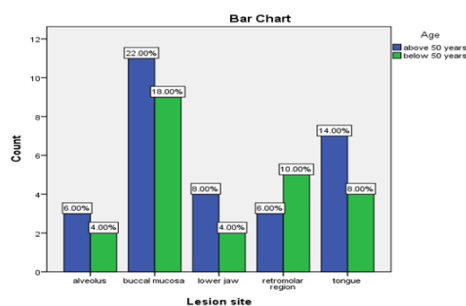
The striking feature in this study is that 60% of patients had no habits of tobacco usage. This finding is in accordance with the literature which states that in their study of 458 tongue cancer cases, 86.4% were never alcohol users and 49.3% of never tobacco users had the best survival outcomes which are not relevant to the earlier finding of cancer five decades ago (Krishnamurthy and Ramshankar, 2013; Sivaramkrishnan and Ramani, 2015). Multi-nucleated giant cells form the main part of numerous bone, and soft tissue tumours were identified by using biomarkers like CD68, CD45 (Kumar, 2015) and use of biomarkers like these in OSCC might help in early detection of the disease progression. Reactive oxygen species have a significant role in the mitochondrial membrane damage-causing apoptosis (Gheena and Ezhilarasan, 2019). Viruses have long been described as one of the etiological factors for carcinogenesis, and there is growing evidence for the role played by human papillomavirus in OSCC (Jayaraj et al., 2015b). However, large scale study has to be done to substantiate the findings in our study (Swathy et al., 2015).

The epidemiological studies in oral cancer mostly are institutionally based, and sometimes gathering of patient information can be biased. The present study is online-based and has the same limitation. Lack of knowledge in retrospective studies is common. The study presents another limitation with the sample size of 50 OSCC cases. Unavailable data were not considered in the analysis of association and might have affected some of the findings. It is necessary to understand the importance of correct data collection along with records sent with the specimens, avoiding the loss of data to minimize this problem.

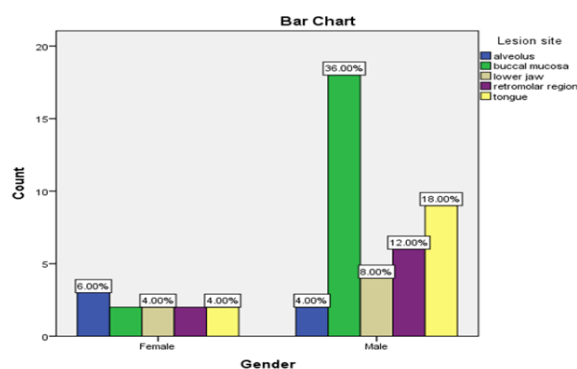
**CONCLUSION**

Within the limits of the study, we can conclude that buccal mucosa was the most common site of occurrence for oral squamous cell carcinoma among males and those greater than 50 years of age. Among the females, alveolus was found to be the most common site. Free screening camps, counselling of poor, uneducated people might help in early detection of oral squamous cell carcinoma. To get more promising results, the study must be conducted with an

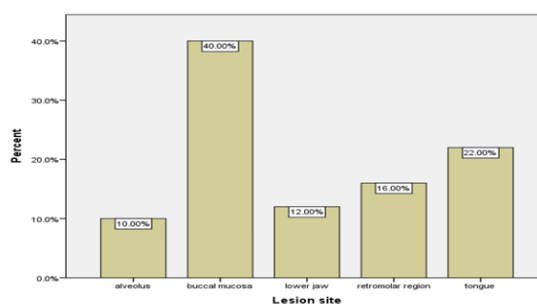
**GRAPHS**



**Figure 1: Correlation of Age with site of OSCC occurrence**



**Figure 2: Correlation of gender with site of OSCC occurrence**



**Figure 3: Percentage distribution of various sites of OSCC occurrence, X Axis: lesion site, y Axis:Percentage**

expanded sample size.

**Funding Support**

The authors declare that they have no funding support for this study.

**Conflict of Interest**

The authors declare that they have no conflict of interest for this study.

## REFERENCES

- Chandra, A. 2013. Oral squamous cell carcinomas in age distinct population: a comparison of p53 immunoexpression. *Journal of cancer research and therapeutics*, 9(4):587-591.
- Fan, S. 2011. A review of clinical and histological parameters associated with contralateral neck metastases in oral squamous cell carcinoma. *International journal of oral science*, 3(4):180-191.
- Gheena, S., Ezhilarasan, D. 2019. Syringic acid triggers reactive oxygen species-mediated cytotoxicity in HepG2 cells. *Human & Experimental Toxicology*, 38(6):694-702.
- Gupta, V., Ramani, P. 2016. Histologic and immunohistochemical evaluation of mirror image biopsies in oral squamous cell carcinoma. *Journal of Oral Biology and Craniofacial Research*, 6(3):194-197.
- Hannah, R. 2018. Awareness about the use, Ethics and Scope of Dental Photography among Undergraduate Dental Students Dentist Behind the lens. *Research Journal of Pharmacy and Technology*, 11(3):1012-1016.
- Jangid, K. 2015. Ankyloglossia with cleft lip: A rare case report. *Journal of Indian Society of Periodontology*, 19(6):690-693.
- Jayaraj, G. 2015. Stromal myofibroblasts in oral squamous cell carcinoma and potentially malignant disorders. *Indian journal of cancer*, 52(1):87-92.
- Jayaraj, G., Ramani, P., Sherlin, H. J., Premkumar, P., Anuja, N. 2015a. Inter-observer agreement in grading oral epithelial dysplasia - A systematic review. *Journal of Oral and Maxillofacial Surgery, Medicine, and Pathology*, 27(1):112-116.
- Jayaraj, G., Sherlin, H., Ramani, P., Premkumar, P., Anuja, N. 2015b. Cytomegalovirus and Mucoepithelioid carcinoma: A possible causal relationship? A pilot study. *Journal of Oral and Maxillofacial Pathology*, 19(3):319-324.
- Jiang, X. 2019. Tobacco and oral squamous cell carcinoma: A review of carcinogenic pathways. *Tobacco induced diseases*, 17:29-29.
- Krishnamurthy, A., Ramshankar, V. 2013. Early Stage Oral Tongue Cancer among Non-Tobacco Users - An Increasing Trend Observed in a South Indian Patient Population Presenting at a Single Centre. *Asian Pacific Journal of Cancer Prevention*, 14(9):5061-5065.
- Kumar, A. 2015. Expression of CD 68, CD 45 and human leukocyte antigen-DR in central and peripheral giant cell granuloma, giant cell tumor of long bones, and tuberculous granuloma: An immunohistochemical study. *Indian journal of dental research: official publication of Indian Society for Dental Research*, 26(3):295-303.
- Patel, S. C. 2011. Increasing incidence of oral tongue squamous cell carcinoma in young white women, age 18 to 44 years. *Journal of clinical oncology: official journal of the American Society of Clinical Oncology*, 29(11):1488-1494.
- Pires, F. R. 2013. Oral squamous cell carcinoma: clinicopathological features from 346 cases from a single oral pathology service during an 8-year period. *Journal of applied oral science: revista FOB*, 21(5):460-467.
- Salian, V. 2016. Etiological Trends in Oral Squamous Cell Carcinoma: A Retrospective Institutional Study. *Cancer Translational Medicine*, 2(2):33-33.
- Shiboski, C. H., Schmidt, B. L., Jordan, R. C. K. 2007. Racial disparity in stage at diagnosis and survival among adults with oral cancer in the US. *Community Dentistry and Oral Epidemiology*, 35(3):233-240.
- Shree, K. H. 2019. Saliva as a Diagnostic Tool in Oral Squamous Cell Carcinoma - a Systematic Review with Meta Analysis. *Pathology & Oncology Research*, pages 447-453.
- Sivaramakrishnan, S. M., Ramani, P. 2015. Study on the Prevalence of Eruption Status of Third Molars in South Indian Population. *Biology and Medicine*, 07(04):1-1.
- Sridharan, G. 2019. official publication of the International Association of Oral Pathologists and the American Academy of Oral Pathology. *Journal of oral pathology & medicine*, 48:299-306.
- Sridharan, G., Ramani, P., Patankar, S. 2017. Serum metabolomics in oral leukoplakia and oral squamous cell carcinoma. *Journal of Cancer Research and Therapeutics*, 0(0):0-0.
- Suresh, G. M. 2019. Prognostic Indicators of Oral Squamous Cell Carcinoma. *Annals of maxillofacial surgery*, 9(2):364-370.
- Swathy, S., Gheena, S., Varsha, S. L. 2015. Prevalence of pulp stones in patients with history of cardiac diseases. *Research Journal of Pharmacy and Technology*, 8(12):1625-1628.
- Tandon, P. 2017. The prevalence of squamous cell carcinoma in different sites of oral cavity at our Rural Health Care Centre in Loni, Maharashtra - a retrospective 10-year study. *Contemporary oncology*, 21(2):178-183.
- Thangaraj, S. V. 2016. Molecular Portrait of Oral Tongue Squamous Cell Carcinoma Shown by Inte-

grative Meta-Analysis of Expression Profiles with Validations. *PloS one*, 11(6):156582–156582.

Viveka, T. S. 2016. p53 Expression Helps Identify High Risk Oral Tongue Pre- malignant Lesions and Correlates with Patterns of Invasive Tumour Front and Tumour Depth in Oral Tongue Squamous Cell Carcinoma Cases. *Asian Pacific journal of cancer prevention*, 17(1):189–195.

Warnakulasuriya, S. 2009. Global epidemiology of oral and oropharyngeal cancer. *Oral Oncology*, 45(4-5):309–316.