



## Comparative evaluation of Skeletal, Dental, and Soft Tissue Changes in Class II Division 1 Malocclusion Cases Treated with Twin Block and innovative Clear Block Appliance- a Prospective Interventional Study

Ankita Agrawal<sup>1</sup>, Narendra Sharma<sup>1</sup>, Ranjit Kamble<sup>1</sup>, Sunita Shrivastav<sup>1</sup>, Shriya Prakash Murarka<sup>\*2</sup>, Akanksha Kumar<sup>3</sup>

<sup>1</sup>Department of Orthodontics and Dentofacial Orthopaedics, Sharad Pawar Dental College and Hospital, Datta Meghe Institute of Medical Science (DMIMS), (DU), Sawangi (Meghe), Wardha, Maharashtra, India

<sup>2</sup>Department of Orthodontics, Sharad Pawar Dental College and Hospital, Datta Meghe Institute of Medical Science (DMIMS), (DU), Sawangi (Meghe), Wardha, Maharashtra, India

<sup>3</sup>Department of Orthodontics and Dentofacial Orthopaedics, Swargiya Dadasaheb Kalmegh Smruti Dental College, Wanadongri, Nagpur, Maharashtra, India



### Article History:

Received on: 01 Jan 2021  
Revised on: 02 Feb 2021  
Accepted on: 03 Feb 2021

### Keywords:

Twin Block Appliance,  
Clear Block Appliance,  
Cephalogram,  
Retrusion,  
Proclination,  
Extrusion,  
Merrifield's Z angle

### ABSTRACT

The present study was undertaken to evaluate and compare the skeletal, dental, and soft tissue changes in skeletal Class II division 1 cases treated with Twin Block and Clear Block appliances using a cephalogram. A total of 40 patients of age between 12-14 years were randomly divided into two equal groups. Group 1: treated with Twin Block appliance and Group 2: treated with Clear Block appliance. The pre-treatment lateral cephalogram was taken and skeletal, dental, and soft tissue parameters were evaluated and the appliance was delivered. After 8 months, another lateral cephalogram of all the cases was taken and analyzed. The pre and post-treatment values were compared between the two groups. The pre-treatment cases were almost comparable in skeletal, dental, and soft tissue features in both groups. There was a significant change in mandibular growth by SNB angle. The retrusion and extrusion of maxillary incisors as well as a proclination and extrusion of mandibular incisors were seen in group 1 while no change was observed in group 2. Treatment with Clear Block appliances has shown significant and favorable Skeletal, Dental and Soft tissue changes which are similar to already proven by the Twin Block appliance. Clear Block provides an esthetic and less bulky option for growth modification with similar results as compared to conventional Twin Block with the additional benefit of preventing lower incisor proclination.

### \*Corresponding Author

Name: Shriya Prakash Murarka  
Phone: 7588788565  
Email: [shriya.m13@gmail.com](mailto:shriya.m13@gmail.com)

ISSN: 0975-7538

DOI: <https://doi.org/10.26452/ijrps.v12i2.4666>

Production and Hosted by

IJRPS | [www.ijrps.com](http://www.ijrps.com)

© 2021 | All rights reserved.

### INTRODUCTION

In the clinical practice of an orthodontist Class II Division 1 malocclusion has been seen to occur more frequently amongst all other problems. Class II condition is the result of various skeletal and dental factors taken together. Nevertheless, it is seen that retrusion of the lower jaw is most commonly seen in physiognomies. In literature, numerous management techniques are discussed to treat Class II malocclusion. There has been growing wakefulness regarding deficiency of the lower jaw as the

leading causative factor for Class II malocclusion. Hence, this structural etiology has led to the amplified acceptance of mandibular advancement appliances or functional appliances (Kumar *et al.*, 2018).

The objective of the treatment that is been done with the functional appliance is to encourage and redirect the growth into an advantageous direction. Numerous functional appliances are mentioned in the existing literature that discusses the treatment of Class II division 1 malocclusion. The main dissimilarities in the changes brought about by different orthopedic appliances are mostly associated with the method of fabrication, construction bites, and duration of wear. The twin-block (TB) appliance is considered the most accepted appliance to correct Class II malocclusion (Firouz *et al.*, 1992). However it has certain shortcomings. To overcome the shortcomings of conventional myofunctional appliances, an innovative Clear Block appliance was developed in the Department of Orthodontics and Dentofacial Orthopedics, S.P.D.C, Sawangi (M), Wardha. Kamble *et al.* (2017) described the fabrication and utility of appliances and suggested that the result should be tested on a large sample (Figure 1).

Hence, the present study was commenced to examine whether the skeletal, dental, and soft tissue changes that occur in response to the use of the Clear Block appliance is comparable to skeletal, dental, and soft tissue response of the Twin Block appliance, which was already proven through systemic reviews and meta-analysis. Such a study will not only help clinicians to choose the appropriate modality of treatment for their patients but also provide a platform for future prospective investigations in similar areas of innovation.

## MATERIALS AND METHODS

After obtaining Institutional Ethical Committee Approval and written informed consent from all the patients. A total of 40 patients were selected for the study. Inclusion criteria for patients were- 1) Cases with skeletal Class II malocclusion with a normal maxilla and retrognathic mandible, 2) with class II molar relation, 3) Overjet equal to or greater than 4mm, 4) Patient in early permanent dentition period within the age group of 12 to 14 years, 5) positive VTO on clinical evaluation, 6) CVMI status – Stage 3 (translation) by Hassel and Farman vertebral index. Patients with class I and class III malocclusion, class II division 2, and class II subdivision malocclusion, with craniofacial syndromes or systemic disease, neurological disorders, severe crowding, and proclination in the dental arches, no history of any orthodontic treatment

were excluded from the study.

A detailed history and clinical examination of all the cases were done to determine the skeletal jaw discrepancy. The lateral cephalograms were obtained, traced, and analyzed manually to assess the skeletal jaw relationship. Patients were differentiated clinically and radiographically into skeletal Class II division 1 malocclusion with the functionally retruded mandible. The selected cases were randomly divided into two equal groups based on their mode of intervention. Intervention in group 1 was done using Twin Block appliance removable myofunctional appliance and in group 2 interventions were done using Clear Block appliance.

The pre-treatment lateral cephalogram of selected cases was obtained on Planmeca Proline cc (Finland) cephalostat with the patient's FH plane parallel to the floor before initiating Orthodontic treatment (Figure 2 Colour Plate no.1). While taking the cephalogram the patients were asked to keep their teeth in maximum intercuspation. Patients were instructed not to swallow or move their head or tongue. A maxillary and mandibular impression of the cases was made and poured in dental stone and bite registration was done according to the standard protocol used for Twin Block therapy. After appliance delivery, patients were monitored for regular wear of the appliance. During the active phase of treatment, the patient was instructed to wear the appliance 24 hours a day, except during brushing. Patients were advised to keep their lips together to form an oral seal when the appliance was being worn. After 8 months of appliance wear i.e. Twin Block (Figure 2 Colour plate no.2) and Clear Block appliance (Figure 2 Colour plate no.3), lateral cephalogram of all the cases undergoing treatment were taken to compare the skeletal, dental, and soft tissue effects thoroughly. For the evaluation of method error, 20 pre-treatment and 20 post-treatment selected cephalograms for every group were retraced and remeasured by the same operator with a one-month interval from the first tracings.

## Statistical Analysis

Statistical analyses were done by using descriptive and inferential statistics using Student's unpaired t-test and Student's paired t-test. The software used in the analysis was SPSS 11.5 and  $p < 0.05$  was considered as the level of significance ( $p < 0.05$ ). The student's unpaired t-test was used for inter-group comparisons of various parameters. Paired t-test was used to compare the parameters within groups.

## OBSERVATIONS AND RESULTS

The pre-treatment observations were evaluated in both groups for skeletal, dental, and soft tissue changes. From this observation, it can be said that the pre-treatment cases were almost comparable in the skeletal, dental, and soft tissue features in both groups, (Graph 1).

Also, post-treatment observations were evaluated in both groups for skeletal, dental, and soft tissue changes as shown in Graph 2.

The comparison of pre-treatment and post-treatment cephalometric findings of the Twin Block appliance (Group 1) and Clear Block appliance (Group 2) were shown in Table 1.

### I) Skeletal changes are seen with Twin Block and Clear Block appliance

#### I-1) Effect of Myofunctional appliance on Maxillary Parameters

The pre-treatment SNA angle was  $81.95^\circ$  and the post-treatment SNA angle was  $81.85^\circ$  in the Twin Block group. In the Clear Block group, the pre-treatment SNA angle was  $82^\circ$ , and the post-treatment SNA angle was  $81.90^\circ$  after 8 months duration of appliance wear. There was a decrease in the maxillary parameter in both groups but the difference was not statistically significant.

#### I-2) Effect of Myofunctional appliance on Mandibular Parameters

The pre-treatment SNB angle was  $76.60^\circ$  and the post-treatment SNB angle was  $79.30^\circ$  in the Twin Block group. In the Clear block group, the pre-treatment SNB angle was  $76.75^\circ$  and the post-treatment SNB angle was  $79.40^\circ$  after 8 months duration of appliance wear. In both the groups, there was a significant change observed in mandibular growth.

#### I-3) Effect of Myofunctional appliance on Maxillomandibular relationship

The pre-treatment ANB angle was  $5.35^\circ$  and post-treatment ANB angle was  $2.55^\circ$  in Twin Block group. In the Clear Block group, the pre-treatment ANB angle was  $5.40^\circ$  and post-treatment ANB angle was  $2.50^\circ$  after 8 months duration of appliance wear. We found a significant change in maxillomandibular relation in both groups.

### II) Dental changes seen with Twin Block and Clear Block appliance

#### II-1) Effect of Myofunctional appliance on Maxillary incisors

Retrusion and extrusion of maxillary incisors were seen in the Twin block group as evident by the

pre-treatment and post-treatment values. The pre-treatment U1 to NA was  $30.55^\circ$  and post-treatment was  $29.70^\circ$ . The post-treatment U1 to NA angle was reduced by  $0.85^\circ$ . Pre-treatment U1 to SN was  $108^\circ$  and post-treatment was  $107^\circ$ . The post-treatment U1 to SN angle was reduced by  $1^\circ$ . The pre-treatment U1-PP was 25.95 mm and post-treatment was 26.65 mm. The post-treatment U1-PP was increased by 0.70 mm. The pre-treatment U1 to A-Pog was 8.80 mm and post-treatment U1 to A-Pog was 7.90 mm. The post-treatment U1 to A-pog was reduced by 0.90 mm. The pre-treatment U1 to NA (linear) was 6.85 mm and post-treatment U1 to NA (linear) was 6.00 mm. The post-treatment U1 to NA (linear) was reduced by 0.85 mm. While no change was observed in the maxillary incisor position in the Clear Block group as evident by the pre-treatment and post-treatment values.

#### II-2) Effect of Myofunctional appliance on Mandibular incisors position

Proclination and extrusion of mandibular incisors were seen in the Twin block group as evident by the pre-treatment and post-treatment values. In group 1 the pre-treatment L1 to NB angle was  $29.55^\circ$  and the post-treatment L1 to NB angle was  $32.30^\circ$ . The post-treatment L1 to NB angle was increased by  $2.75^\circ$ . The pre-treatment value of IMPA was  $96.45^\circ$  and the post-treatment IMPA was  $100.25^\circ$ . The post-treatment value of the IMPA angle was increased by  $3.8^\circ$ . The pre-treatment value of L1 to MP was 34.05 mm and the post-treatment value was 35.05 mm. The post-treatment value of L1 to MP was increased by 1 mm. The pre-treatment value of L1 to A-Pog was 3.85 mm and the post-treatment value of L1 to A-Pog was 5.60 mm. The post-treatment value of L1 to A-pog was increased by 1.75 mm. The pre-treatment value of L1 to NB (linear) was 6.00 mm and the post-treatment value of L1 to NB (linear) was 7.22 mm. The post-treatment L1 to NB (linear) was increased by 1.22 mm. While no change was observed in the mandibular incisor position in the Clear Block group as evident by the pre-treatment and post-treatment values.

### III) Soft tissue changes are seen with Twin Block and Clear Block appliance

#### III-1) Effect of myofunctional appliance on Soft tissue Facial profile

In group 1, the pre-treatment Facial convexity angle was  $18.85^\circ$ , and the post-treatment facial convexity angle was  $16.35^\circ$ . The value of pre-treatment Merrifield's Z angle was  $74.70^\circ$  and post-treatment Merrifield's Z angle was  $77.65^\circ$ . In group 2, the pre-treatment facial convexity angle was  $21.30^\circ$  and the



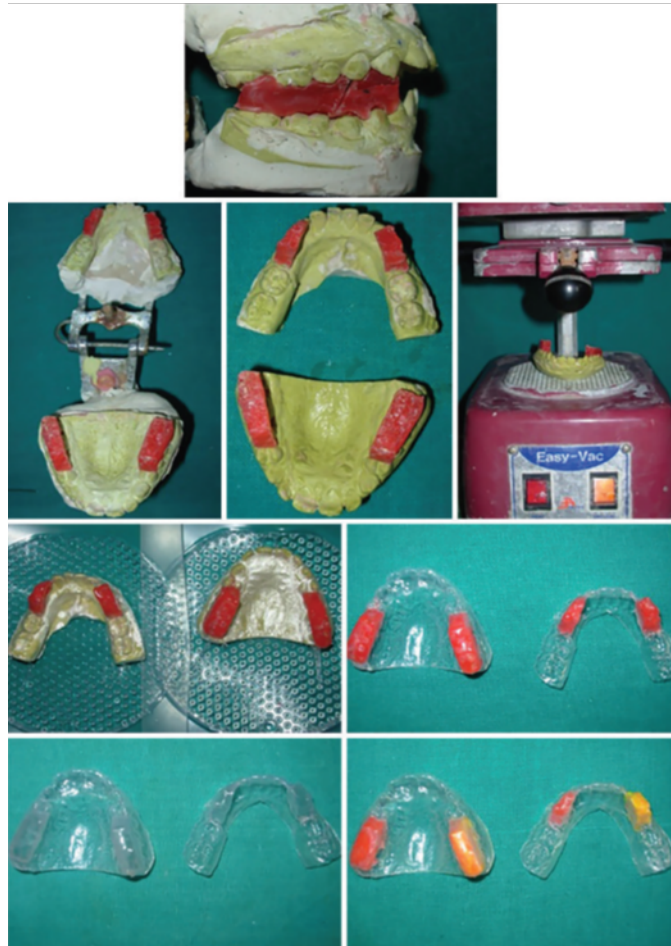

Figure 1: Clear block appliance steps in fabrication

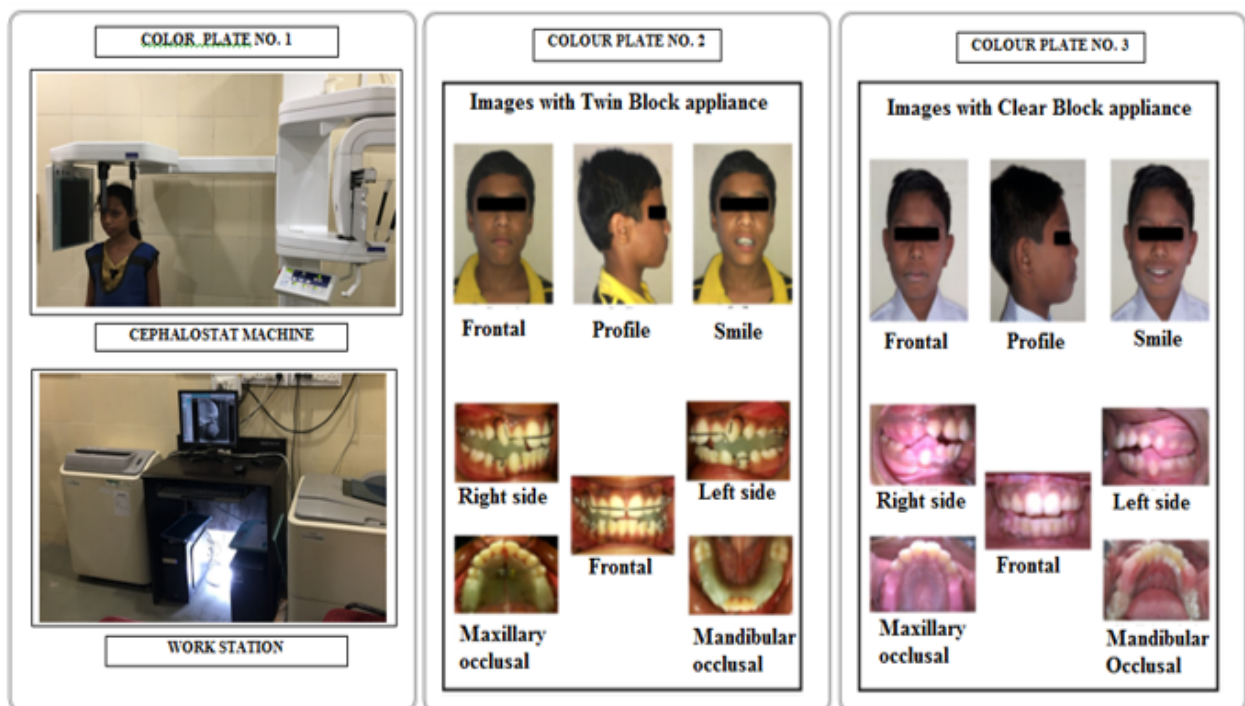
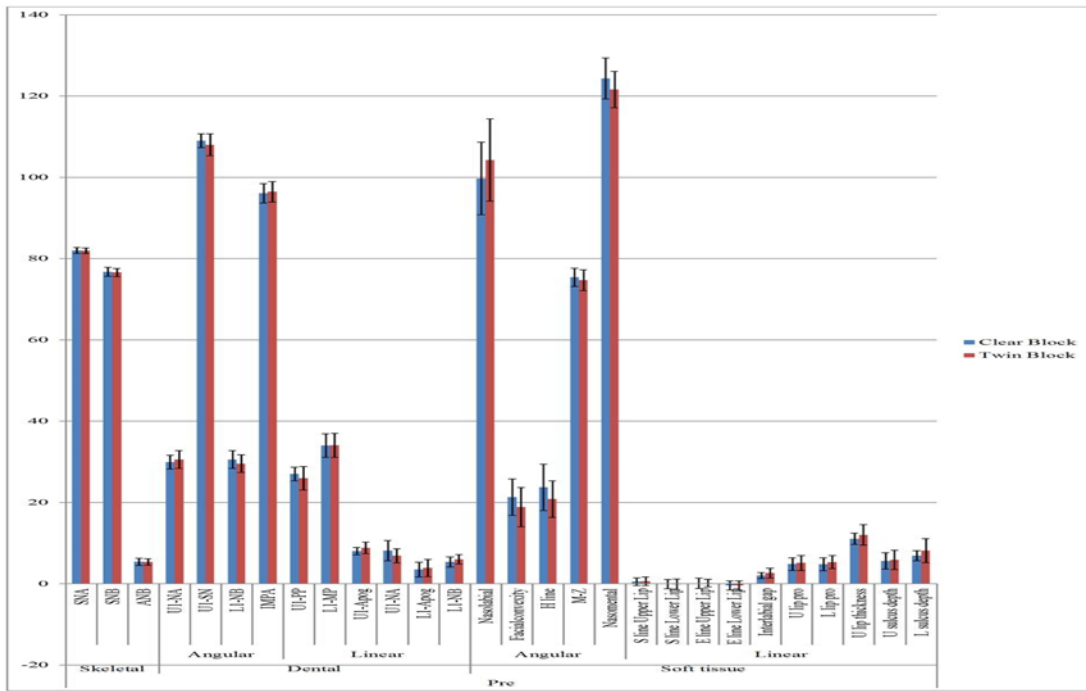
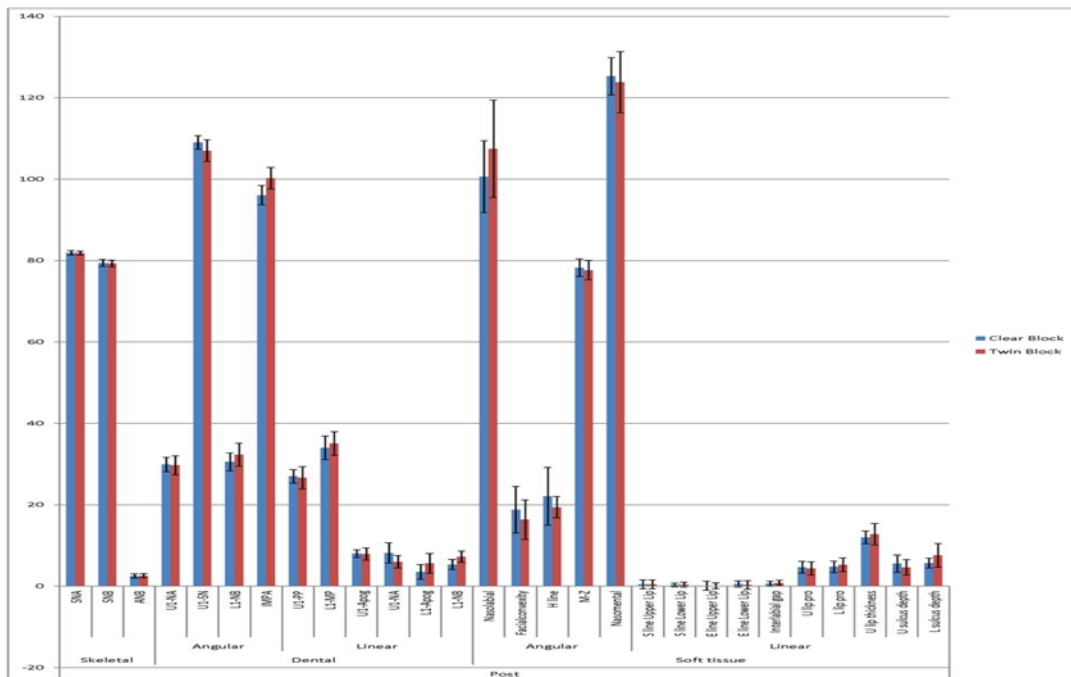


Figure 2: Material and methods used in this study



Graph 1: Comparison of pre-treatment cephalometric findings of Twin Block appliance (Group 1) and Clear Block appliance (Group 2)



Graph 2: Comparison of post-treatment cephalometric findings of Twin Block appliance (Group 1) and Clear Block appliance (Group 2)

**Table 1: Comparison of pre-treatment and post treatment cephalometric findings of Twin Block appliance (Group 1) and Clear Block appliance (Group 2)**

Variables		Group 1			Group 2		
Skeletal variables	To	T1	P value	To	T1	P-value	
	Mean $\pm$ SD	Mean $\pm$ SD		Mean $\pm$ SD	Mean $\pm$ SD		
SNA	81.95 $\pm$ 68	81.85 $\pm$ 0.48	0.330	82.00 $\pm$ 0.72	81.90 $\pm$ 0.55	0.330	
SNB	76.60 $\pm$ 0.99	79.30 $\pm$ 0.80	0.000	76.75 $\pm$ 1.11	79.40 $\pm$ 0.88	0.000	
ANB	5.35 $\pm$ 0.81	2.55 $\pm$ 0.51	0.000	5.40 $\pm$ 0.88	2.5 $\pm$ 0.51	0.000	
Dent- al	Angular						
	U1-NA	30.55 $\pm$ 2.18	29.70 $\pm$ 2.31	0.000	29.90 $\pm$ 1.71	29.90 $\pm$ 1.77	1.000
	U1-SN	108 $\pm$ 2.67	107 $\pm$ 2.67	0.000	109.00 $\pm$ 1.68	109.00 $\pm$ 1.68	-
	L1-NB	29.55 $\pm$ 2.18	32.30 $\pm$ 2.81	0.000	30.55 $\pm$ 2.18	30.55 $\pm$ 2.18	-
	IMPA	94.45 $\pm$ 2.52	100.25 $\pm$ 2.63	0.000	96.05 $\pm$ 2.37	96.05 $\pm$ 2.37	
	Linear						
	U1-PP	25.95 $\pm$ 2.87	26.65 $\pm$ 2.73	0.009	27.00 $\pm$ 1.65	27.00 $\pm$ 1.65	
	L1-MP	34.05 $\pm$ 2.92	35.05 $\pm$ 2.89	0.000	34.00 $\pm$ 2.88	34.00 $\pm$ 2.88	
	U1-Apog	8.80 $\pm$ 1.43	7.90 $\pm$ 1.48	0.000	8.00 $\pm$ 0.91	8.00 $\pm$ 0.91	
	U1-NA	6.85 $\pm$ 1.72	6.00 $\pm$ 1.54	0.000	8.15 $\pm$ 2.49	8.15 $\pm$ 2.49	
	L1-Apog	3.85 $\pm$ 2.10	5.60 $\pm$ 2.43	0.000	3.500 $\pm$ 1.82	3.500 $\pm$ 1.82	
	L1-NB	6.00 $\pm$ 1.16	7.22 $\pm$ 1.39	0.000	5.35 $\pm$ 1.22	5.35 $\pm$ 1.22	
Soft Tiss- ue	Angular						
	Nasolabial	104.25 $\pm$ 10.12	107.45 $\pm$ 11.95	0.262	99.70 $\pm$ 8.93	100.60 $\pm$ 8.83	0.160
	Facial con- vexity	18.85 $\pm$ 4.81	16.35 $\pm$ 4.82	0.002	21.30 $\pm$ 4.47	18.80 $\pm$ 5.71	0.016
	H line	20.82 $\pm$ 4.50	19.40 $\pm$ 2.62	0.165	23.70 $\pm$ 5.67	22.10 $\pm$ 7.08	0.109
	M-Z	74.70 $\pm$ 2.55	77.65 $\pm$ 2.36	0.000	75.40 $\pm$ 2.23	78.25 $\pm$ 2.17	0.000
	Nasomental	121.60 $\pm$ 4.47	123.80 $\pm$ 7.52	0.090	124.30 $\pm$ 5.04	125.30 $\pm$ 4.58	0.027
	Linear						
	S line Upper Lip	0.60 $\pm$ 1.04	0.45 $\pm$ 1.09	0.083	0.50 $\pm$ 0.94	0.45 $\pm$ 1.09	0.438
	S line Lower Lip	- 0.15 $\pm$ 1.30	0.40 $\pm$ 0.59	0.118	-0.101.119	0.30 $\pm$ 0.47	-1.506
	E line upper lip	0.15 $\pm$ 0.93	0.10 $\pm$ 0.71	0.871	0.10 $\pm$ 1.25	0.10 $\pm$ 1.11	0.000
	E line lower lip	- 0.45 $\pm$ 1.14	0.30 $\pm$ 1.03	-2.263	-0.45 $\pm$ 1.14	0.55 $\pm$ 0.75	-5.627
	Interlabial Gap	2.60 $\pm$ 1.20	0.80 $\pm$ 0.63	0.000	2.00 $\pm$ 0.76	0.60 $\pm$ 0.61	8.718
	U Lip pro	5.10 $\pm$ 1.815	4.35 $\pm$ 1.59	0.117	4.82 $\pm$ 1.55	4.65 $\pm$ 1.46	2.333
	L lip pro	5.30 $\pm$ 1.61	5.27 $\pm$ 1.68	0.841	4.77 $\pm$ 1.56	4.75 $\pm$ 1.40	0.203
	U lip thick- ness	12.00 $\pm$ 2.51	12.77 $\pm$ 2.62	0.077	11.05 $\pm$ 1.39	12.00 $\pm$ 1.58	-5.248
	U sulcus depth	5.85 $\pm$ 2.36	4.62 $\pm$ 1.91	0.002	5.60 $\pm$ 2.01	5.52 $\pm$ 2.13	0.547
	L sulcus depth	8.12 $\pm$ 2.95	7.57 $\pm$ 2.91	0.248	6.90 $\pm$ 1.25	5.67 $\pm$ 1.19	9.561

post-treatment facial convexity angle was  $18.80^\circ$ . The pre-treatment Merrifield's Z angle was  $75.40^\circ$  and post-treatment Merrifield's Z angle was  $78.25^\circ$ . In group 1, the pre-treatment Nasomental angle was  $121.60^\circ$  and the post-treatment Nasomental angle was  $123.80^\circ$ , which was statistically not significant. In group 2, the pre-treatment Nasomental angle was  $124.30^\circ$  and the post-treatment Nasomental angle was  $125.30^\circ$ . There was an increase in nasomental angle by  $1^\circ$  which was statistically significant. Thus, there was a significant change observed in a facial profile in both the groups as evident by the pre-treatment and post-treatment parameters like facial convexity and Merrifield's Z angle.

## DISCUSSION

Class II malocclusion can present in many different combinations of skeletal and dental derangements. This invariably has a negative influence on the soft tissue profile of the patient. Nevertheless, the most common problem with these patients is the sagittal retrusion of the lower jaw (Jena and Duggal, 2010). Gilmore mentioned that the small mandible accompanied with retrusion lead to the Class II, Division 1 malocclusion. Consequently, ideally, the treatment progress of such patients should be aimed towards functional appliance therapy (Gilmore, 1950).

As the Twin Block appliance is well known myofunctional appliance in the correction of Class II division 1 malocclusion. Their limitations are also well established. To know whether the newly designed innovation gives effective skeletal, dental, and soft tissue results along with overcoming the limitation of conventional Twin Block appliances, a present study was planned. A total of 40 cases were selected and categorized as group 1 (Twin Block appliance) and group 2 (Clear Block appliance) based on their mode of intervention. In both, groups, the cases selected were in the active phase of pre-pubertal spurt.

### Skeletal changes seen with Twin Block and Clear Block appliance

There was a decrease in the maxillary parameter in both the groups but the difference was not statistically significant as evident by the pre-treatment and post-treatment SNA angle. While there was an increase in SNB angle observed in both groups, which was statistically significant. This indicates an increase in mandibular growth and effective mandibular length in both groups. A significant favorable improvement in ANB angle was observed in both Twin Block and Clear Block groups. These improved values suggest that both groups induced supplementary lengthening and repositioning of the

mandible by stimulating increased growth at the condylar cartilage and mandibular retrognathia as well as facial profile. These findings were in concordance with other studies (Toth and McNamara, 1999; Dauravu, 2014).

### Dental changes seen with Twin Block and Clear Block appliance

In group 1, there was a reduction in post-treatment U1 to NA angle by  $0.85^\circ$  and U1 to SN angle by  $1^\circ$  suggest that the maxillary incisors tipped palatally i.e. shows retrusion. While post-treatment U1-PP was increased by 0.70 mm suggested that the upper incisor was extruded in treatment with Twin Block appliance. The post-treatment U1 to A-pog was reduced by 0.90 mm and U1 to NA (linear) was reduced by 0.85 mm suggested that the maxillary incisors retracted concerning the A-pog line and NA line respectively. This retroclination and retraction effect may be due to the distal driving force transferred by the mandible or due to the force transferred by the lip through the labial bow.

However, there was no change in maxillary incisor position in the Clear Block group as evident by the pre-treatment and post-treatment values. In group 2, pre-treatment and post-treatment U1-NA angle, U1 to SN angle, U1-PP, U1 to A-Pog, and U1 to NA value was the same as indicated by statistically non-significant results. This suggests that upper incisors were not palatally tipped as well as not extruded during treatment with the Clear Block appliance. It can be concluded that stability of maxillary incisor was more in group 2 than in group 1 and this effect in group 2 may be due to incisor covering with the thermoplastic plate. A similar type of results was reported in previous studies (Tümer and Gültan, 1999; Brunharo et al., 2011).

In group 1, the post-treatment L1 to NB angle increased by  $2.75^\circ$  which suggests the proclination of lower incisors. Similarly, the post-treatment value of IMPA angle was increased by  $3.8^\circ$  indicates that mandibular incisors were tipped labially with Twin Block appliance. The post-treatment value of L1 to MP was increased by 1 mm suggested that lower incisors were extruded by Twin Block appliance therapy. The post-treatment value of L1 to A-pog was increased by 1.75 mm suggest that the mandibular incisors are proclined labially. The post-treatment L1 to NB (linear) was increased by 1.22 mm which suggests the proclination of mandibular incisors. In group 2, pre-treatment and post-treatment L1 to NB angle, IMPA angle, L1 to MP, L1 to A-Pog, and L1 to NB (linear) were the same and found no change in mandibular incisor position indicating that the mandibular incisors neither tipped

labially nor extruded. The finding of the current study is in accordance with the other studies (Parkin *et al.*, 2001; Lee *et al.*, 2007).

### Soft tissue changes seen with Twin Block and Clear Block appliance

In both the groups, there was a decrease in facial convexity angle value and an increase in M-Z angle value which was statistically significant suggestive of improvement in facial profile in both groups. In group 1, there was an increase in nasomental angle but the difference was not statistically significant whereas, in group 2, an increase was observed in nasomental angle by 1° which was statistically significant and suggestive of improvement in facial profile in the Clear Block group. These results are comparable with previous studies (Khoja *et al.*, 2016; Akin *et al.*, 2014). In the present study, we observed improvement in facial profile, increased lower lip length, and increased lower lip prominence with the Twin Block appliance. Similar results were observed by the above authors (Murarka *et al.*, 2020; John *et al.*, 2019) for the group receiving the treatment with Twin Block appliance.

There are some limitations of the study, which include- 1) The sample size is to be large to prove stronger evidence, 2) There is a lack of evidence about the long-term results of the Clear Block appliance.

### CONCLUSION

Treatment with Clear Block appliance in skeletal Class II division 1 malocclusion with retrognathic mandible has shown significant and favorable Skeletal, Dental, and Soft tissue changes which are similar to already proven Skeletal, Dental, and Soft tissue effects of the Twin Block appliance. However, further clinical research is warranted to gather additional information regarding the role of the Clear Block appliance in mandibular growth and soft tissue changes in Class II division 1 malocclusion with different growth patterns. The present study suggested that the continued research in this area, with modifications to study design, will provide valuable information about the correction of Class II division 1 malocclusion.

### ACKNOWLEDGMENT

Mr. Tejas Anjankar, provided writing assistance, language editing, and proofreading. Dr. Babar conducted the data analysis and created the tables and figures. Mr. Sekar Natrajan, Mr. Rohan Agrawal, And Mr. Sanket Tibdiwal provided technical assistance in manuscript framing.

### Funding Support

The authors declare that they have no funding support for this study.

### Conflict of Interest

The authors declare that they have no conflict of interest for this study.

### REFERENCES

- Akin, M., Polat, O., Ileri, Z., Basciftci, F. A. 2014. Effects of the Activator and Twin Block on Facial Soft Tissue Thickness in Class II Division 1 Patients. *Turkish Journal of Orthodontics*, 27(3):128-135.
- Brunharo, I. H. V. P., Quintão, C. A., Almeida, M. A. D. O., Motta, A., Barreto, S. Y. N. 2011. Dentoskeletal changes in Class II malocclusion patients after treatment with the Twin Block functional appliance. *Dental Press Journal of Orthodontics*, 16(5):1-8.
- Dauravu, L. M. 2014. The Assessment of Sagittal Changes with Twin Block Appliance in Patients with Decelerating Growth Phase. *Journal of Clinical and Diagnostic Research*, 8(12):81-84.
- Firouz, M., Zernik, J., Nanda, R. 1992. Dental and orthopedic effects of high-pull headgear in treatment of Class II, Division 1 malocclusion. *American Journal of Orthodontics and Dentofacial Orthopedics*, 102(3):197-205.
- Gilmore, W. A. 1950. Morphology of the adult mandible in Class II, Division 1 malocclusion and in excellent occlusion. *The Angle Orthodontist*, 20(3):137-146.
- Jena, A. K., Duggal, R. 2010. Treatment Effects of Twin-Block and Mandibular Protraction Appliance-IV in the Correction of Class II Malocclusion. *The Angle Orthodontist*, 80(3):485-491.
- John, Z. A. S., Shrivastav, S., Gurudatta, N. S., Murarka, S. 2019. An Innovative Approach to Manage Tooth Size - Arch Length Discrepancy. *Journal of Evolution of Medical and Dental Sciences*, 8(50):3819-3821.
- Kamble, R., Sharma, N. S., Shrivastav, S., Sharma, P. 2017. A Tailored Approach for Growth Modification: An Innovative Approach. *World Journal of Dentistry*, 8(4):334-342.
- Khoja, A., Fida, M., Shaikh, A. 2016. Cephalometric evaluation of the effects of the Twin Block appliance in subjects with Class II, Division 1 malocclusion amongst different cervical vertebral maturation stages. *Dental Press Journal of Orthodontics*, 21(3):73-84.



- Kumar, A., Sharma, N., Shrivastav, S., Kamble, R., Bhandari, N. 2018. Assessment of Changes in Tongue Position in Class II Division 1 Patients Treated with Functional Appliances-An in-vivo Study. *Int J Cur Res Rev*, 10(8):10.
- Lee, R., Kyi, C., Mack, G. 2007. A controlled clinical trial of the effects of the Twin Block and Dynamax appliances on the hard and soft tissues. *The European Journal of Orthodontics*, 29(3):272-282.
- Murarka, S. P., Shrivastav, S., Kamble, R., Bidwai, P. S., Gosavi, S., Merchant, Z. 2020. Aesthetic management of missing anterior teeth in Binder Syndrome-A Case report. *Medical Science*, 24(105):3370-3375.
- Parkin, N. A., McKeown, H. F., Sandler, P. J. 2001. Comparison of 2 modifications of the twin-block appliance in matched class II samples. *American Journal of Orthodontics and Dentofacial Orthopedics*, 119(6):572-577.
- Toth, L. R., McNamara, J. A. 1999. Treatment effects produced by the Twin-block appliance and the FR-2 appliance of Fränkel compared with an untreated Class II sample. *American Journal of Orthodontics and Dentofacial Orthopedics*, 116(6):597-609.
- Tümer, N., Gültan, A. S. 1999. Comparison of the effects of monoblock and twin-block appliances on the skeletal and dentoalveolar structures. *American Journal of Orthodontics and Dentofacial Orthopedics*, 116(4):460-468.