



Efficacy of hyaluronic acid gel in management of post-operative complications after removal of third molar - A Systematic review

Divya Sanjeevi Ramakrishnan*, Sudarssan Subramaniam Gouthaman, Janani Kandamani, Senthilnathan Periasamy

Department of Oral and Maxillofacial Surgery, Saveetha Dental College, Saveetha University, Chennai, Tamil Nadu, India

Article History:

Received on: 25 May 2020

Revised on: 16 Jun 2020

Accepted on: 16 Jul 2020

Keywords:

Complications of third molar removal,
Healing of extraction socket,
Hyaluronic acid gel,
Third molar removal

ABSTRACT

The surgical removal of third molar is the commonly performed procedure in oral and maxillofacial surgery. It takes several days to recover from the complications following removal of the third molar. The common postoperative complications are pain, swelling, trismus, alveolar osteitis after third molar removal. The aim of this systematic review was to thoroughly analyse the existing literature to evaluate the effect of intra socket versus extra socket application of hyaluronic acid gel in management of postoperative complications after third molar removal. The objective of this systematic review is to assess the efficacy of intra socket versus extra socket application of hyaluronic acid gel compared to placebo or no treatment in management of post-operative complications after removal of third molar. The data bases of PubMed, Cochrane and google scholar were searched for the related topics along with a complimentary manual search of all oral surgery journals till October 2018. The data collection form was based on analysis of included studies for their quality assessment and publication bias. The primary outcome measure was post-operative pain and the secondary outcome measures were post-operative swelling & post-operative mouth opening. Three articles were selected based on the inclusion criteria. The included studies were randomized controlled trials. The clinical evidence from this review shows hyaluronic acid gel application is found to be beneficial in reducing pain, swelling & trismus after surgical removal of third molar. After contemplating its pivotal role in various anti-inflammatory diseases, it is prudent to consider as an alternative in managing postoperative sequelae of third molar removal.



*Corresponding Author

Name: Divya Sanjeevi Ramakrishnan

Phone: +91 8870497174

Email: divyaramakrishnan55@gmail.com

ISSN: 0975-7538

DOI: <https://doi.org/10.26452/ijrps.v11i4.3289>

Production and Hosted by

IJRPS | www.ijrps.com

© 2020 | All rights reserved.

INTRODUCTION

The mandibular third molar is the commonest tooth impacted in the oral cavity. The frequent cause for failure of eruption in the alveolar arch is due to lack of space as a pattern of evolution. Complications are inevitably associated with such surgical removal of third molars. The frequency and severity of the complications associated with surgical procedures are influenced by various factors that are related to the procedure, patient, and surgeon (Göktay *et al.*, 2011). Following the days after third molar surgery, pain, facial swelling, alveolar osteitis (Blum, 2002) and restriction of mouth opening, reduced qual-

ity of life were the notable changes (Berge, 1997). Variable amount of oedema or swelling is expected after any surgical procedures, (Filho, 2008) leading to trismus or reduced mouth opening (Hupp et al., 2018). The maximum size of the swelling is seen at 1–2 days after procedure, begins to subside on the third or fourth day and resolves by the end of the first week. Postoperative trismus, swelling, and pain levels (Trindade et al., 2011), varies with the age, gender, operating time and surgical difficulty of the impacted teeth (Lago-Méndez et al., 2007). Various agents have been investigated to prevent or reduce these postoperative sequelae (Ham-mad et al., 2011). Management of such postoperative inflammation and associated symptoms requires adequate anti-inflammatory and antibiotic therapy (Ren and Malmstrom, 2007).

Hyaluronan or hyaluronic acid (HA) is a biomaterial that has been shown to accelerate the wound healing. Karl Meyer and John Palmer in 1934 discovered HA by segregating from vitreous body of a cow. Beginning in 1960s, HA-based compounds were constituted for skin lesions, 1980s for cataract corrective surgeries. By 1980s advanced toward joint injections, finally in 1990s, hyaluronic acid emerged in aesthetic field where at present it is highly recognized. The name hyaluronic acid is derived from Greek word denoting “glass & sugar”.

Hyaluronic acid is distinguished for its cellular metabolism and other biological processes of tissue repair. It is found in many tissues with its highest concentrations in connective tissues including the synovial fluid in human and all tissue and body fluids of vertebrates. It has been described to play an crucial roles in wound healing by inducing early granulation tissue formation by promoting re-epithelialization and also angiogenesis during the healing phase (Mendes et al., 2008). Thus, HA has been used to prevent or reduce postoperative inflammation and associated symptoms (Koray et al., 2014). The effects such as non-immunogenic and non-toxicity allows it to be used in many fields, such as ophthalmology, dermatology, and rheumatology. HA is available in gel or liquid forms to be applied topically in the oral cavity (Prestwich, 2011; Fatini et al., 1968). Transforming growth factor (TGF) β -1, basic fibroblast growth factor (b-FGF), platelet-derived growth factor (PDGF), and epidermal growth factor (EGF) all stimulate hyaluronic acid production by fibroblasts. Furthermore, their effects appear to be synergistic and not related to mitosis and, by extension, proliferation (Mesa, 2002). It would, therefore, appear that at least some of the effects of these growth factors upon cell proliferation and migration are mediated through

the hyaluronic acid pathway (Greco et al., 1998). The circumstance is even though not clear, there would have all the profits by exogenous utilization of hyaluronic acid on extracellular matrix remodeling (Mast et al., 1993).

MATERIALS AND METHODS

The Data Bases of PubMed Advanced, Cochrane and Google scholar were searched until October 2018 using controlled vocabulary and free text terms. This electronic search includes text articles only in English language, human species and to include all the randomized control studies that are relevant for the inclusion criteria of this systematic review.

Inclusion criteria

Randomized controlled trials

Clinical trials

Patients undergoing surgical removal of impacted upper & lower third molar.

Hyaluronic acid Gel is used for the management of postoperative complications after third molar surgery.

Placebo

Post-operative pain, Post-operative swelling, Post-operative mouth opening is evaluated following third molar surgery

Exclusion criteria

The following studies were excluded,

Other than gel forms of hyaluronic acid are excluded.

Studies with combination of hyaluronic acid with other drugs are excluded.

Case reports / Case series

Pilot studies

Review articles

Animal studies

In vitro studies

Studies not meeting inclusion criteria were excluded.

Search Methodology

Electronic search was carried out using the keywords in the Search engines- PubMed, Cochrane and Google Scholar which yielded a total of 19 articles. Hand search yielded two articles which were the same as those obtained in PubMed. Based on predetermined inclusion and exclusion criteria, the titles of the studies identified from the

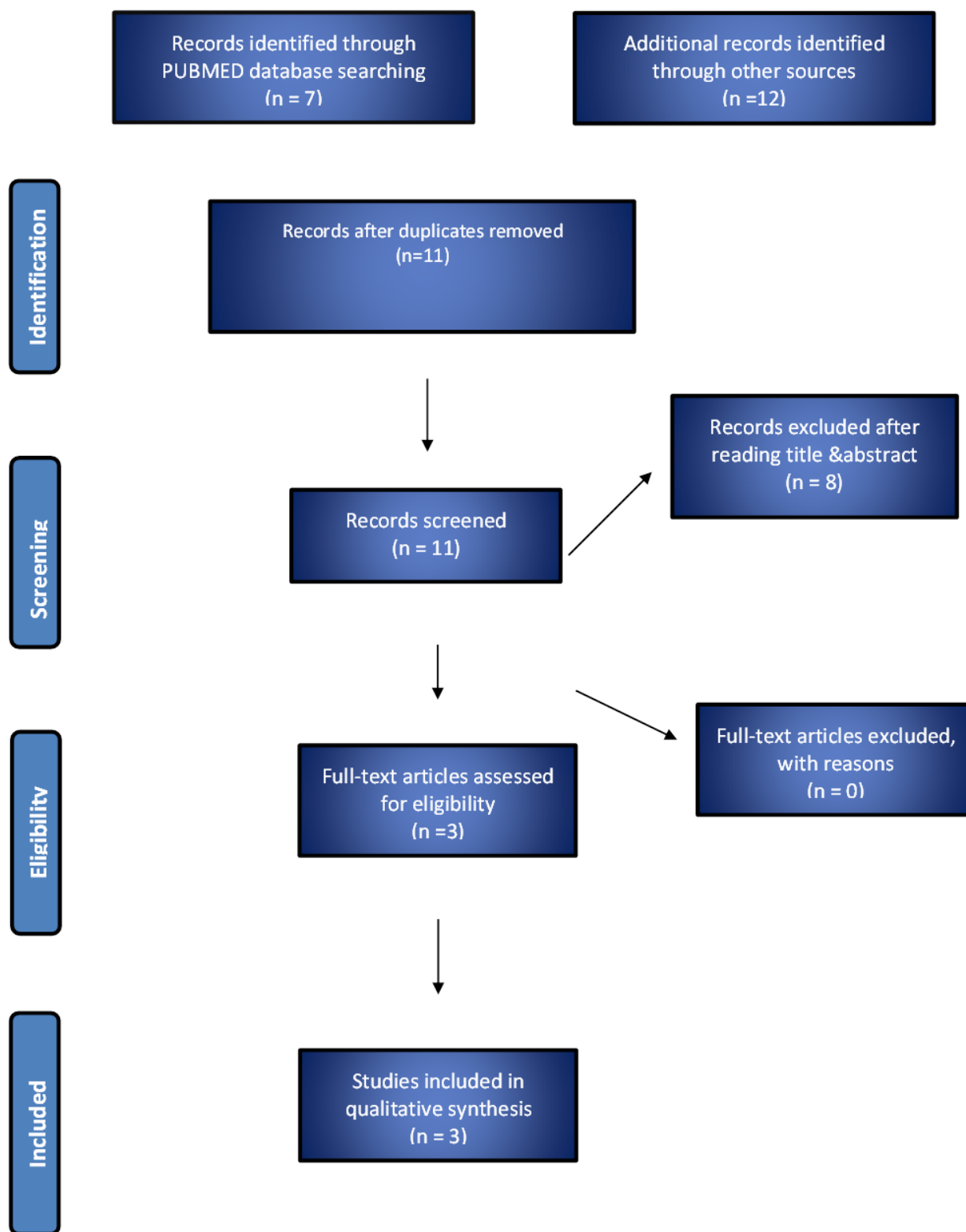


Figure 1: Search Flow Chart According to PRISMA guidelines

Table 1: Risk of Bias -Major and Minor Criteria

| S.No | Author & Year | Randiomi- Sation | Allocation Conceal- ment | Assessor Blind- ing | Dropouts Describe | Sample Justi- fied | Baseline Com- pari- sion | I/E crtite- ria | Method Error |
|------|---------------------------------------|------------------|--------------------------|---------------------|-------------------|--------------------|--------------------------|-----------------|--------------|
| 1. | Bayoumi et al. (2018) | yes | no | yes | none | no | yes | yes | no |
| 2 | Gocmen et al. (2017) | yes | no | no | none | yes | yes | yes | No |
| 3 | Gocmen et al. (2015) | yes | no | yes | none | no | yes | yes | no |

Table 2: General Characteristics of The Included Studies

| S.No | Author & year | Title of the article | Study design | Sample size | Mean Age & gender | Control group | Intervention group |
|------|---------------------------------------|---|------------------------------|-------------|---|---------------|--|
| 1. | Bayoumi et al. (2018) | The Effect of Cross-Linked Hyaluronic Acid in Surgical Extraction of Impacted Mandibular Third Molars | Randomised split mouth study | N=14 | 25.25 ± 3.1 Years (males =7, females=7) | placebo | Intra Socket Application of hyaluronic acid gel. |
| 2. | Gocmen et al. (2017) | Effects of hyaluronic acid on bleeding following third molar extraction | Randomised cross over study | N=40 | 18-35 years | placebo | Extra Socket applica- tion (edge of the socket). |
| 3. | Gocmen et al. (2015) | The antioxidant and anti-inflammatory efficiency of hyaluronic acid after third molar extraction | Randomised cross over study | N=40 | 26.6 ± 6.3 year | placebo | Extra Socket applica- tion (edge of the socket). |

Table 3: General Characteristics of The Included Studies

| S.No | Author & year | Dosage of hyaluronic acid gel | Outcomes measured at | Variables of interest |
|------|------------------------------|---|--|--|
| 1. | Bayoumi <i>et al.</i> (2018) | 0.33 ml cross-linked HA gel (HyaDENT BG [®] , 20 mg HA/ml) | 2nd, 4th, 7th day | Pain by VAS Score, Swelling measured by orotragal and Mentotragal distances. Mouth opening was recorded by measuring Interincisal distance |
| 2. | Gocmen <i>et al.</i> (2017) | A 0.2 ml HA gel (0.8% [w/v]; Gengigel, Ricerfarma, Italy) following tooth removal (n=20). | POD hour, 3rd day, 7th day | 1st Pain by VAS Score, Swelling measured by orotragal and Mentotragal distances. Mouth opening was recorded by measuring Interincisal distance |
| 3. | Gocmen <i>et al.</i> (2015) | 0.8% [w/v]; Gengigel, Ricerfarma, Italy) following tooth removal | Immediately after extraction, POD 7th day. | Pain by VAS Score, Mouth opening was recorded by measuring Interincisal distance. |

Table 4: Outcome Measures Assessed in The Included Studies

| S.No | Author Name | Outcomes Measured | Other Outcomes | Pain | Maximum Incisal Opening | Facial Swelling |
|------|------------------------------|--|---|-----------|---|--|
| 1. | Bayoumi <i>et al.</i> (2018) | Cross-Linked Hyaluronic Acid in Surgical Extraction of Impacted Mandibular Third Molars | Not specified | VAS score | Difference between interincisal distance before and after surgery | Swelling measured by orotragal and mentotragal distances |
| 2. | Gocmen <i>et al.</i> (2017) | Effects of hyaluronic acid on bleeding following third molar extraction | Bleeding time | VAS score | Difference between interincisal distance before and after surgery | Swelling measured by orotragal and mentotragal distances |
| 3. | Gocmen <i>et al.</i> (2015) | The antioxidant and anti-inflammatory efficiency of hyaluronic acid after third molar extraction | LPO levels were determined by Ledwozyw's method & GSH measurements were performed | VAS score | Difference between interincisal distance before and after surgery | Not measured |

search were assessed independently by two review authors (Dr.Divya S.R, Dr.Senthilnathan periasamy). Conflicts concerning inclusion of the studies were resolved by discussion. Eleven studies were identified from the search after excluding duplications. Eight articles were excluded after reading titles and abstracts. Full text articles were retrieved for three relevant studies (Figure 1). The reference list of the full text articles were reviewed for identifying additional studies. Quality assessment criteria evaluated for the studies by two review authors in accordance with PRISMA guidelines. The risk of bias for each study was independently assessed by the review authors and conflicts concerning risk of bias were sorted by discussion.

Quality of Evidence

Out of three articles included in this review, all three articles shows as level 2 evidence (Bayoumi *et al.*, 2018; Gocmen *et al.*, 2015, 2017). Type of randomization & allocation concealment method were not mentioned in all three articles Gocmen *et al.* (2015, 2017); Bayoumi *et al.* (2018). Assessor blinding was done in Bayoumi *et al.* (2018) & Gocmen *et al.* (2015) study. Sample size justification was given in Gocmen *et al.* (2017) study. There was no method error in all studies. The risk of bias is moderate for two studies, Bayoumi *et al.* (2018); Gocmen *et al.* (2015), and high for Gocmen *et al.* (2017).

RESULTS AND DISCUSSION

There were 2 randomized controlled trials & 1 clinical trial is included in this systematic review. The data extraction is done for all 3 studies (Tables 2 and 3). The various outcome measures assessed in the included studies were categorised in Table 4.

According to Amr bayoumi (Bayoumi *et al.*, 2018), a total of fourteen patients were included in this study. The mean age of the participants was 25.25 ± 3.1years (range: 22-32 years).

Once after the surgical removal of third molar, 0.33 ml cross-linked HA gel was set into study socket and plain Gelfoam in the control socket. Finally closure of flap using 3-0 Vicryl sutures. All the outcome variables were measured on post-operative second, fourth and seventh day. The mean MMO was significantly increased all through the study period and most distinct difference is seen at 7th postoperative day for HA group (P<0.001).the facial swelling for the HA group on the 7th postoperative day was significantly less (P<0.05).The mean pain VAS scores declined gradually in both groups, whereas it is significant on postoperative day seven for HA group.

According to Gocmen et al (Gocmen *et al.*, 2017),

total of forty patients was included and mean patient age was 24.8 years (18-35 years). 0.8% HA was applied on the edge of the extraction socket for the HA group and no intervention for control group. The pain score by VAS, and MIO, swelling measured at POD 1st hr, 3rd, 7th day. MIO and VAS were not statistically significant between groups at 1st hour, 3rd day and 7th day. However 3rd day outcomes of facial swelling was increased for HA group.

According Gocmen et al (Gocmen *et al.*, 2015), with total of 40 patients included and mean age was 26.6 ± 6.3 years. Applications of 0.8% HA gel at the edge socket area for study group and no intervention for control group. The outcome variables were evaluated at POD 1st, 7th day. No statistically significant differences for VAS and MIO scores between the groups at postoperative 7th day. However mean VAS scores for both groups after 1 week was significantly reduced (p <0.05).

Following extraction, formation of the blood clot is a fundamental step for socket repair. The formation of fibrin network provides a stable matrix as a base for lymphocytes, macrophages and neutrophils migration, characterizing the acute inflammatory response. Thin collagen fibrils formed by fibroblasts join to newly formed capillaries to form the granulation tissue (Yugoshi *et al.*, 2002). Bone resorption in bone crests in the beginning, while bone deposition is seen at the base of the socket. Mesenchymal cells originated from remnant periodontal ligament and medullar bone differentiate into osteoblastic cells that secrete bone matrix, observed after a week (Kanyama *et al.*, 2003). Socket healing events result in a thick bony trabecular network containing small medullary spaces at 21 days (Devlin and Sloan, 2002). Sequelae after removal of third molars such as nerve injury, pain, swelling, trismus & dry socket can cause an effect on quality of life. Routine management of such complications include anti-inflammatory drugs, steroids, and analgesics. However prescription of such drugs has its own adverse effects. To promote soft and hard tissue healing, the topical application of antibiotics such as tetracycline and minocycline, or chlorhexidine, platelet-rich fibrin (Yelamali and Saikrishna, 2015) platelet-rich plasma (Dutta *et al.*, 2015) and hyaluronic acid (Koray *et al.*, 2014) have been used after third molar surgery.

Hyaluronic acid based gels have been used for healing of bone defects, with bone morphogenetic protein 2 (BMP-2), bone matrix, hydroxyapatite (Itoh, 2001) demineralized or bone graft (Bakoš *et al.*, 1999).

Others demonstrated that topical HA promoted

healing (Marigliò *et al.*, 2009) and reduced patient discomfort when used as an adjuvant treatment for gingivitis and chronic periodontitis, or postoperatively, following dental implant/sinus elevation procedures Ballini *et al.* (2009). Topical HA also seems to have been effective in treating oral ulcers (Sandy-Hodgetts *et al.*, 2015).

One study Bayoumi *et al.* (2015) showed that there were no difference between study and control groups when a non-cross linked HA used in the socket and it dissolved within 12 hours.

No statistically significant difference between the groups after mandibular third molar extraction with topical application of sodium hyaluronate gel and an amino acid is seen (Guazzo, 2018). Study conducted by Yilmaz et al (Yilmaz, 2017) showed that local administration of HA into the extraction socket may alleviate the pain.

However Afat et al (Afat *et al.*, 2018) proved that postoperative oedema can be minimized after third molar surgery when L-PRF combined with HA as L-PRF ensures that certain amount of HA is remained in the socket for a longer duration. When HA is used for dry socket, it acts as stabiliser for matrix formed during healing phase and stimulates migration and proliferation of fibroblasts.

CONCLUSIONS

Within the limitations of this systematic review, it provides a basis for the routine administration of hyaluronic acid gel to reduce the intensity of post-surgical sequelae such as pain, swelling and trismus. Intra socket application of cross linked hyaluronic acid gel is an effective alternative in reducing post-operative pain, dry socket & trismus whereas the extra socket application of hyaluronic acid gel is not as efficient. The number of good quality randomized controlled trials included in this review is very limited & the dosage and type of hyaluronic acid gel is used in the articles of this review are also inconsistent. The method of application of hyaluronic acid gel such as either intra socket or extra socket as well as use of cross linked HA, should be taken into consideration & comparison of these would prove the reliable method. Use of hyaluronic acid gel in regard to other post-operative parameters such as, bleeding, anti-inflammatory, antioxidant effect should be evaluated at larger sample size & various forms of hyaluronic acid at different dosage should also be considered.

Conflict of Interest

The authors declare that they have no conflict of interest for this study.

Funding Support

The authors declare that they have no funding support for this study.

REFERENCES

- Afat, İ. M., Akdoğan, E. T., Gönül, O. 2018. Effects of Leukocyte- and Platelet-Rich Fibrin Alone and Combined With Hyaluronic Acid on Pain, Edema, and Trismus After Surgical Extraction of Impacted Mandibular Third Molars. *Journal of Oral and Maxillofacial Surgery*, 76(5):926–932.
- Bakoš, D., Soldán, M., Hernández-Fuentes, I. 1999. Hydroxyapatite–collagen–hyaluronic acid composite. *Biomaterials*, 20(2):191–195.
- Ballini, A., Cantore, S., Capodiferro, S., Grassi, F. R. 2009. Esterified Hyaluronic Acid and Autologous Bone in the Surgical Correction of the Infra-Bone Defects. *International Journal of Medical Sciences*, 6(2):65–71.
- Bayoumi, A., Nadershah, M., Albandar, A., Alsulaimani, B., Sankour, I., Gadi, L., Osama, O., Tayeb, R., Quqandi, R., Dabroom, W., Merdad, Y. 2018. The Effect of Cross-Linked Hyaluronic Acid in Surgical Extraction of Impacted Mandibular Third Molars. *International Journal of Dentistry and Oral Health*, 4(2).
- Bayoumi, A. M., Jan, A., Amoudi, W. A., Shakir, M. 2015. The Effects of Using Hyaluronic Acid on the Extraction Sockets. *Int J Dent Oral Health*, 2(1).
- Berge, T. I. 1997. Inability to work after surgical removal of mandibular third molars. *Acta Odontologica Scandinavica*, 55(1):64–69.
- Blum, I. R. 2002. Contemporary views on dry socket (alveolar osteitis): a clinical appraisal of standardization, aetiopathogenesis and management: a critical review. *International Journal of Oral and Maxillofacial Surgery*, 31(3):309–317.
- Devlin, H., Sloan, P. 2002. Early bone healing events in the human extraction socket. *International Journal of Oral and Maxillofacial Surgery*, 31(6):641–645.
- Dutta, S. R., Singh, P., Passi, D., Patter, P. 2015. Mandibular Third Molar Extraction Wound Healing With and Without Platelet Rich Plasma: A Comparative Prospective Study. *Journal of Maxillofacial and Oral Surgery*, 14(3):808–815.
- Fatini, G., Gallenga, G., Veltroni, A. 1968. Treatment of burns with hyaluronic acid. *Ospedali d'Italia-chirurgia*, 19(3):283–287.
- Filho, J. R. L. 2008. Clinical comparative study of the effectiveness of two dosages of dexamethasone to control postoperative swelling, trismus

- and pain after the surgical extraction of mandibular impacted third molars. *Cephalalgia: an international journal of headache*, 13(2):129–161.
- Gocmen, G., Aktop, S., Tüzüner, B., Goker, B., Yarat, A. 2017. Effects of hyaluronic acid on bleeding following third molar extraction. *Journal of Applied Oral Science*, 25(2):211–216.
- Gocmen, G., Gonul, O., Oktay, N. S., Yarat, A., Goker, K. 2015. The antioxidant and anti-inflammatory efficiency of hyaluronic acid after third molar extraction. *Journal of Cranio-Maxillofacial Surgery*, 43(7):1033–1037.
- Göktay, Ö., Satılmış, T., Garip, H., Gönül, O., Göker, K. 2011. A Comparison of the Effects of Midazolam/Fentanyl and Midazolam/Tramadol for Conscious Intravenous Sedation During Third Molar Extraction. *Journal of Oral and Maxillofacial Surgery*, 69(6):1594–1599.
- Greco, R. M., Iocono, J. A., Ehrlich, H. P. 1998. Hyaluronic acid stimulates human fibroblast proliferation within a collagen matrix. *Journal of Cellular Physiology*, 177(3):465–473.
- Guazzo, R. 2018. Effect on wound healing of a topical gel containing amino acid and sodium hyaluronate applied to the alveolar socket after mandibular third molar extraction: A double-blind randomized controlled trial. *Quintessence international*, (10):49.
- Hammad, H. M., Hammad, M. M., Abdelhadi, I. N., Khalifeh, M. S. 2011. Effects of topically applied agents on intra-oral wound healing in a rat model: a clinical and histomorphometric study. *International Journal of Dental Hygiene*, 9(1):9–16.
- Hupp, J. R., Tucker, M. R., Ellis, E. 2018. Contemporary Oral and Maxillofacial Surgery E-Book.
- Itoh, S. 2001. Enhancement of bone ingrowth in a titanium fiber mesh implant by rhBMP-2 and hyaluronic acid. *Journal of Materials Science: Materials in Medicine*, 12(7):575–581.
- Kanyama, M., Kuboki, T., Akiyama, K., Nawachi, K., Miyauchi, F. M., Yatani, H., Kubota, S., Nakanishi, T., Takigawa, M. 2003. Connective tissue growth factor expressed in rat alveolar bone regeneration sites after tooth extraction. *Archives of Oral Biology*, 48(10):723–730.
- Koray, M., Ofluoglu, D., Onal, E. A., Ozugul, M., Ersev, H., Yaltirik, M., Tanyeri, H. 2014. Efficacy of hyaluronic acid spray on swelling, pain, and trismus after surgical extraction of impacted mandibular third molars. *International Journal of Oral and Maxillofacial Surgery*, 43(11):1399–1403.
- Lago-Méndez, L., Diniz-Freitas, M., Senra-Rivera, C., Gude-Sampedro, F., Rey, J. M. G., García-García, A. 2007. Relationships Between Surgical Difficulty and Postoperative Pain in Lower Third Molar Extractions. *Journal of Oral and Maxillofacial Surgery*, 65(5):979–983.
- Mariggiò, M. A., Cassano, A., Vinella, A., Vincenti, A., Fumarulo, R., Muzio, L. L., Maiorano, E., Ribatti, D., Favia, G. 2009. Enhancement of Fibroblast Proliferation, Collagen Biosynthesis and Production of Growth Factors as a Result of Combining Sodium Hyaluronate and Aminoacids. *International Journal of Immunopathology and Pharmacology*, 22(2):485–492.
- Mast, B. A., Diegelmann, R. F., Krummel, T. M., Cohen, I. K. 1993. Hyaluronic Acid Modulates Proliferation, Collagen and Protein Synthesis of Cultured Fetal Fibroblasts. *Matrix*, 13(6):441–446.
- Mendes, R. M., Silva, G. A., Lima, M. F., Calliari, M. V., Almeida, A. P., Alves, J. B., Ferreira, A. J. 2008. Sodium hyaluronate accelerates the healing process in tooth sockets of rats. *Archives of Oral Biology*, 53(12):1155–1162.
- Mesa, F. L. 2002. Antiproliferative effect of topic hyaluronic acid gel. Study in gingival biopsies of patients with periodontal disease. *Histology and histopathology*, 17(3):747–753.
- Prestwich, G. D. 2011. Hyaluronic acid-based clinical biomaterials derived for cell and molecule delivery in regenerative medicine. *Journal of Controlled Release*, 155(2):193–199.
- Ren, Y-F, Malmstrom, H. S. 2007. Effectiveness of Antibiotic Prophylaxis in Third Molar Surgery: A Meta-Analysis of Randomized Controlled Clinical Trials. *Journal of Oral and Maxillofacial Surgery*, 65(10):1909–1921.
- Sandy-Hodgetts, K., Carville, K., Leslie, G. D. 2015. Determining risk factors for surgical wound dehiscence: a literature review. *International Wound Journal*, 12(3):265–275.
- Trindade, P. A. K., Giglio, F. P. M., Colombini-Ishikiriana, B. L., Calvo, A. M., Modena, K. C. S., Ribeiro, D. A., Dionísio, T. J., Brozoski, D. T., Lauris, J. R. P., Faria, F. A. C., Santos, C. F. 2011. Comparison of oral versus sublingual piroxicam during postoperative pain management after lower third molar extraction. *International Journal of Oral and Maxillofacial Surgery*, 40(3):292–297.
- Yelamali, T., Saikrishna, D. 2015. Role of Platelet Rich Fibrin and Platelet Rich Plasma in Wound Healing of Extracted Third Molar Sockets: A Comparative Study. *Journal of Maxillofacial and Oral Surgery*, 14(2):410–416.
- Yilmaz, N. 2017. The efficacy of hyaluronic acid in postextraction sockets of impacted third molars:

A pilot study. *Nigerian journal of clinical practice*, 20(12):1626-1631.

Yugoshi, L. I., Sala, M. A., Brentegani, L. G., Carvalho, T. L. L. 2002. Histometric study of socket healing after tooth extraction in rats treated with diclofenac. *Brazilian Dental Journal*, 13(2):92-96.