



Morphometric Analysis of Frontal Sinus Dimensions Using Digital Radiographs

Pinki Rai*, Amit Kumar Saxena, Namita Mehrotra, Prachi Saffar Aneja

Department of Anatomy, SGT University Gurgaon-Badli Road Chandu, Budhera, Gurugram-122505, Haryana, India

Article History:

Received on: 25 Jul 2020
Revised on: 12 Aug 2020
Accepted on: 26 Aug 2020

Keywords:

Frontal sinus,
Morphometric
evaluation,
Symmetry,
Caldwell's View

ABSTRACT

The present study was aimed to evaluate the importance of combined use of frontal sinus dimensions and evaluating possible implications. The study was retrospective and intended to measure dimensions on 60 digital radiographs (PA Caldwell's View) of age group 20 to 50 years. The Institutional Ethical Committee approved the research protocol. Inclusion Criteria was taken as radiographs with good image quality and absence of any artefact. Radiographs of individuals with bilateral complete frontal sinus development were included while radiographs are exhibiting pathology like, e.g. mucous retention within the frontal sinus, aplasia (unilateral and bilateral) or rudimentary frontal sinus excluded from the study. Parameters measured were maximum height, width on both sides and symmetry of frontal sinus. Out of 60 radiographs five were excluded from the study (2 frontal sinus aplasia and 3 unilateral frontal sinuses). The final study involved 55 radiographs (N=55) which constituted 28 males and 27 females. The mean values of maximum height and width were obtained. Symmetry was calculated using width. There were significant differences in average width and height of frontal sinus of males and females. The results of the study favour the radiographic evaluation and frontal sinus dimensions for identification in forensics and also it is useful for the management of sinus-related ailments.



*Corresponding Author

Name: Pinki Rai
Phone: 9050675237
Email: pinkiraishkmgmc@gmail.com

ISSN: 0975-7538

DOI: <https://doi.org/10.26452/ijrps.v11i4.3267>

Production and Hosted by

IJRPS | www.ijrps.com

© 2020 | All rights reserved.

different sizes of cavities and show an asymmetrical pattern (Christensen, 2005; Rossouw *et al.*, 1991). In the initial years of life frontal sinus grows gradually, but at puberty, the cavities grow considerably both in males and females (Ruiz and Wafae, 2004). However, the growth and development of frontal sinus are complete by the second decade of life (Prossinger and Bookstein, 2003; Pandeshwar *et al.*, 2017). There may be an observed failure in the development of frontal sinus cavity in the bone, and the condition is called as aplasia. Aplasia may be unilateral or bilateral.

INTRODUCTION

Frontal sinuses are air-filled cavities inside the frontal bone with lobulations on the margins. Although the frontal sinus exists in pairs, the cavities develop independent of each other, leading to

Radiography is the conventional method of investigation. Plain radiographs are nowadays replaced by digital radiographs providing better image quality (Bansal, 2006). Frontal sinuses are best visible in Caldwell's view, and dimensions of sinus cavities can be measured easily. Detailed information on

anatomy and size of frontal sinus is crucial for the management of sinus (Cashman *et al.*, 2011) related ailments and dimension based personal identification in forensics (Krishan, 2013).

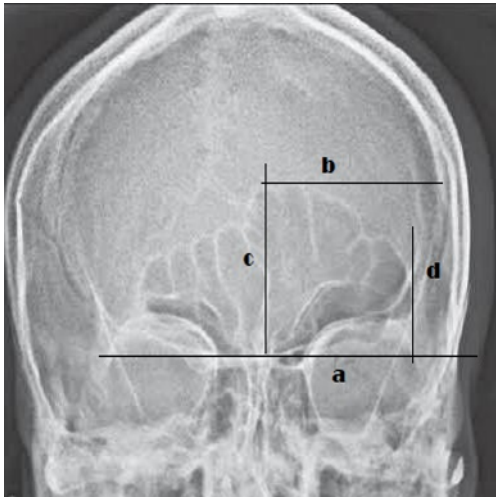


Figure 1: Measurement of width and height of frontal sinus cavity

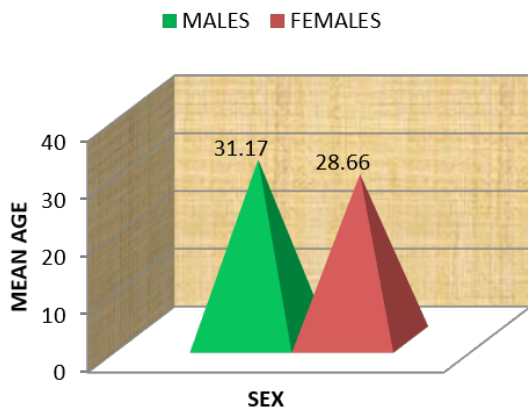


Figure 2: Comparison of mean Age

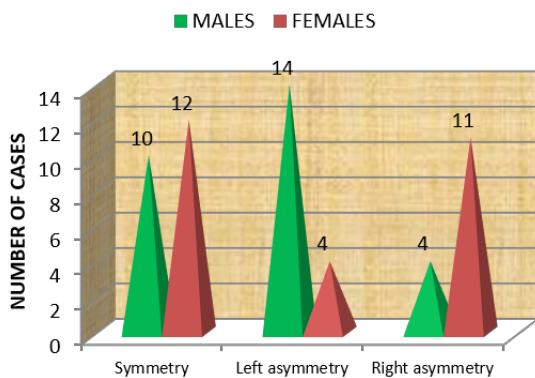


Figure 3: Comparison of patterns of frontal sinus

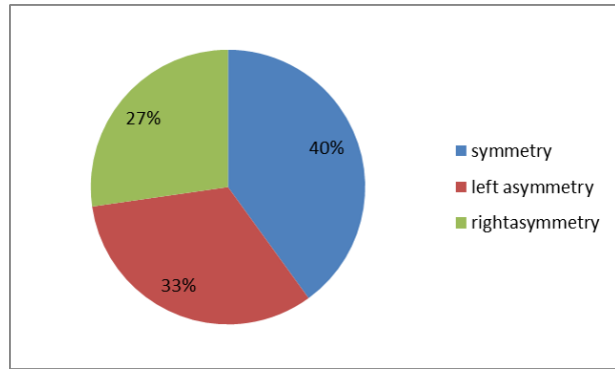


Figure 4: Distribution of symmetry/ asymmetry in total subjects (n=55)

MATERIALS AND METHODS

The present study was based on retrospective design and was proposed to measure dimensions on 60 digital radiographs (PA Caldwell's View) of age group 20 to 50 years, consisting of 30 males and 30 females. The research protocol was approved by the Institutional Ethical Committee of SGT Medical College, Gurugram. Only useful quality radiographs were included which were found free from any error. Also, the radiographs of individuals with bilateral complete frontal sinus development were included while radiographs are exhibiting pathology like, e.g. mucous retention within the frontal sinus, aplasia (unilateral and bilateral) or undeveloped frontal sinus excluded from the study. Parameters measured were maximum height, width on both sides and symmetry of frontal sinus. Out of total 60 (30 males, 30 females) participants, 55 were found to be suitable as per inclusion criteria, and thus 5 were excluded from the study and analysis.

Method of measurement of parameters: For the measurement of above said five parameters, a radiograph was placed on view box and following lines were drawn using fine marker and ruler as shown in the image given (Figure 1).

All the measurements were calculated as per previous studies (Taniguchi *et al.*, 2003; Gopal and Vijayan, 2016). The difference between the width of two cavities was divided by sum of width of two cavities and multiplied by hundred provided the data for symmetry. A value less than or equal to twenty was taken as symmetrical cavities while exceeding the twenty per cent was taken as asymmetry of larger size cavity.

RESULTS AND DISCUSSION

Among the included 55 participants, there were 28 males and 27 females. The mean age of both genders was comparable. The average age in the case

Table 1: Average height of right and left frontal sinus cavity

Gender	Rt. height (in cm) Mean \pm SD	Lt. height (in cm) Mean \pm SD
Males	3.19 \pm 1.04	3.17 \pm 1.01
Females	2.70 \pm 0.77	2.69 \pm 0.74
Statistical analysis	0.05	0.04
Significance	Significant (p < 0.05)	Significant (p < 0.05)

Table 2: Average widths of Right and Left frontal sinus cavity

Gender	Rt. width (in cm) Mean \pm SD	Lt. width (in cm) Mean \pm SD
Males	2.40 \pm 0.92	2.89 \pm 0.84
Females	2.98 \pm 1.14	2.36 \pm 1.08
Statistical analysis	0.04	0.04
Significance	Significant (p < 0.05)	Significant (p < 0.05)

of males and females are comparable, and data has been illustrated in Figure 2.

It was observed that the average height of the right frontal sinus cavity was higher in males than in females and found to be statically significant (p = 0.05). Similar results were seen in the left frontal sinus cavity. The average height of both sides frontal sinus cavities were more in males than in females (Table 1).

There were interesting observations in the width of frontal sinus cavities. The average width of the right frontal sinus cavity was higher in females, i.e. 2.98 \pm 1.14 than in males which were 2.40 \pm 0.92 (Table 2). On the contrary, the average left width was higher in males than females. The results were statically Significant (p < 0.05).

The pattern of frontal sinus cavity has shown significant results. Left asymmetry was highly significant (p=0.005 Significant) with a distribution of 14 cases among males and 4 among females. Right asymmetry was also statically significant (p=0.02 Significant) with more cases in females than males, i.e. 11 and 4, respectively. Figure 3 is showing the distribution of symmetry/ asymmetry of frontal sinus cavity in males and females.

The total number of cases having symmetry was 22; left asymmetry 18 and right asymmetry were 15. The distribution is shown in the graph below(Figure 4). The contribution of symmetry is 40%, left asymmetry 33% and right asymmetry 27%.

Researchers have extensively studied frontal sinus, clinicians and academicians, taking into consideration various aspects of frontal sinus like height,

width, symmetry, area, scallops, no of septa etc. The association of frontal sinus concerning age, gender, demography and weather has been established (Camargo *et al.*, 2007). There have been observed variation in different populations and locations.

The present study was conducted in the southwest region of New Delhi, India. The age of participants included in the study was above twenty years as the growth of the frontal sinus cavity is supposed to be completed at this age (Camargo *et al.*, 2007). The average age of the study participants was found as 31.17 \pm 10.52 years in males and 28.66 \pm 11.76 in females. The average height of the right frontal sinus cavity was found to be 3.19 \pm 1.04 cm in males and 2.70 \pm 0.77 cm in females. The results had shown significance statistically. These results were also supported by previous studies (Kotrashetti *et al.*, 2014). On the left side height of the frontal sinus cavity was found to be 3.17 \pm 1.01 cm in case of males and 2.69 \pm 0.74 in case of females. In the present study, height on both right and left side of the frontal sinus cavity was higher in males than in females. Height on both sides has been reported to be higher in males than in females by (Kotrashetti *et al.*, 2014; Kanjani *et al.*, 2018).

Researchers have adopted different methods for measurement of the width of the frontal sinus cavity. Some have approached by taking the width as a whole measuring the distance between the width farthest lateral limits of the frontal sinus cavity (Tehranchi *et al.*, 2015; Verma *et al.*, 2017). While others have measured the width separately for each side of sinus cavity taking reference of the inter-sinus septum to the farthest point on each

side (Kotrashetti *et al.*, 2014; Verma *et al.*, 2015; Soman *et al.*, 2016). The present study has followed the latter approach and width of the right and left sinus cavities were measured separately for both males and females. Right width was found to be 2.40 ± 0.92 cm in case of males while it was 2.98 ± 1.14 cm in case of females. The width of the right frontal sinus cavity was significantly higher in females. These results were contrasting to previous studies in which dimensions of right width were higher in males than that of females (Kotrashetti *et al.*, 2014; Soman *et al.*, 2016). The average width of the left frontal sinus cavity was found to be 2.89 ± 0.84 cm while in females it was observed as 2.36 ± 1.08 cm. The left frontal sinus cavity was significantly higher in males than that of females. These results were in congruence with the previous studies, which also favoured a higher value of left width in males (Kotrashetti *et al.*, 2014; Verma *et al.*, 2017).

In this study, the symmetry was observed in a total of 22 cases, left asymmetry in 18 cases and right asymmetry in 15 cases contributing to 40%, 33% and 27 % respectively. These results were in accordance with a study conducted by (Taniguchi *et al.*, 2003) and rest cases of as reported by (Verma *et al.*, 2015; Saxena and David, 2010) reported 58% of cases with symmetry and 32% of cases with asymmetry. Other studies also have reported more than 50 % of cases with overall symmetry.

The frontal sinus has shown versatile dimensions contingent on the circumstances and demography. The results also have been found in a wide range depending upon the sample sizes and methods of measurements. However, exploring the dimensions of a larger sample can produce a better picture of the pattern of that population.

CONCLUSIONS

The knowledge of frontal sinus anatomy and the sizes of various parameters of its cavity is helpful in clinical practice for the management of minor to major sinus ailments. The results of the present study have shown significant differences in dimensions of male and female frontal sinus cavities favouring its application in forensics for personal identification.

Funding Support

The authors declare that they have no funding support for this study.

Conflict of interest

The authors declare that they have no conflict of interest for this study.

REFERENCES

- Bansal, G. J. 2006. Digital radiography. A comparison with modern conventional imaging. *Postgraduate Medical Journal*, 82(969):425-428.
- Camargo, R. J., Dargue, E., Prado, F. B., Caria, P., Alves, M. C., Silva 2007. The frontal sinus morphology in radiographs of Brazilian subjects: its forensic importance. *Braz J Morphol Sci*, 24(4):239-243.
- Cashman, E. C., Macmahon, P. J., Smyth, D. 2011. Computed tomography scans of paranasal sinuses before functional endoscopic sinus surgery. *World Journal of Radiology*, 3(8):199.
- Christensen, A. M. 2005. Testing the Reliability of Frontal Sinuses in Positive Identification. *Journal of Forensic Sciences*, 50(1):1-5.
- Gopal, K. S., Vijayan, B. P. 2016. Significance of frontal sinus and nasal septum patterns in personal identification in forensics: A retrospective CBCT study. *Int J Oral Health Med Res*, 2(6):57-62.
- Kanjani, V., Annigeri, R. G., Revanappa, M. M., Tejaswini, N. G., Jain, N., Sharma, N. 2018. Morphometric Evaluation of the Frontal Sinus and Nasal Septum as an Aid in Personal and Gender Identification- A Retrospective Digital Radiographic Study. *JMSCR*, 6(3):1154-1161.
- Kotrashetti, V. S., Kale, A. D., Belaldavar, C., Halikerimath, S. R. 2014. Assessment of frontal sinus dimensions to determine sexual dimorphism among Indian adults. *Journal of Forensic Dental Sciences*, 6(1):25.
- Krishan, T. K. K. 2013. Personal Identification in Forensic Examinations. *Anthropology*, 02(01):2.
- Pandeshwar, P., Kumar, N. N., Shastry, S. P., Ananthaswamy, A., Markande, A. 2017. Sexual dimorphism of radiomorphological features of frontal sinus. *International Journal of Forensic Odontology*, 2(2):46.
- Prossinger, H., Bookstein, F. L. 2003. Statistical estimators of frontal sinus cross section ontogeny from very noisy data. *Journal of Morphology*, 257(1):1-8.
- Rossouw, P. E., Lombard, C. J., Harris, A. M. P. 1991. The frontal sinus and mandibular growth prediction. *American Journal of Orthodontics and Dentofacial Orthopedics*, 100(6):542-546.
- Ruiz, C. R., Wafae, N. N. 2004. Anatomoradiological and morphometrical study of the frontal sinus in humans. *Braz J Morphol Sci*, 21(1):53-59.
- Saxena, R., David, M. P. 2010. Use of frontal sinus and nasal septum patterns as an aid in personal identification: A digital radiographic pilot study. *Journal of Forensic Dental Sciences*, 2(2):77.

- Soman, B. A., Sujatha, G. P., Lingappa, A. 2016. Morphometric evaluation of the frontal sinus in relation to age and gender in subjects residing in Davangere, Karnataka. *Journal of Forensic Dental Sciences*, 8(1):57.
- Taniguchi, M., Sakoda, S., Kano, T., Zhu, B. L., Kamikodai, Y., Fujita, M. Q., Maeda, H. 2003. Possible use of nasal septum and frontal sinus patterns to radiographic identification of unknown human remains. *Osaka City Medical Journal*, 49(1):31-38.
- Tehranchi, A., Saedi, S., Motamedian, S., Rohani, K. 2015. Radiographic Evaluation of Frontal Sinus Dimensions and Anatomic Variations. *British Journal of Medicine and Medical Research*, 8(5):454-462.
- Verma, K., Nahar, P., Singh, M. P., Mathur, H., Bhuvaneshwari, S. 2017. Use of Frontal Sinus and Nasal Septum Pattern as an Aid in Personal Identification and Determination of Gender: A Radiographic Study. *Journal of clinical and diagnostic research: JCDR*, 11(1):71-74.
- Verma, P., Verma, K., Khosa, R., Kumar, S., Basavaraju, S., Patwardhan, N. 2015. The combined use of frontal sinus and nasal septum patterns as an aid in forensics: A digital radiographic study. *North American Journal of Medical Sciences*, 7(2):47.