



Radiographic imaging evaluation of mandibular third molars among patients presenting to private dental college in South India

Jones Jayabalan*, Jayakeerthana S, Muthusekhar MR

Department of Oral and Maxillofacial Surgery, Saveetha Dental College and Hospitals, Saveetha Institute of Medical and Technical Sciences, Chennai - 600077, Tamilnadu, India



Article History:

Received on: 30 May 2020

Revised on: 30 Jun 2020

Accepted on: 01 Jul 2020

Keywords:

Agenesis,
Impacted tooth,
Panoramic radiography,
Third molars

ABSTRACT

The most common reason for mandibular third molar impaction is due to reduced space between the distal part of the second mandibular molar and the anterior border of the ascending ramus of the lower jaw. The tooth that is impacted is commonly asymptomatic, or sometimes present with various pathological conditions causing pain and swelling as well as pus discharge. In our current study, we have assessed the patterns of Mandibular third molar impactions using the Orthopantomogram (OPG's). OPG's of 150 patients (91 female and 59 male) who were between 18-25 years of age and had impacted mandibular third molars was assessed for gender, the region having the highest frequency of impaction and the fashion of impaction of the mandibular third molars. The study shows Bilateral impaction was more commonly seen in 26.66% of the study population and case of unilateral impactions the most frequent site is particularly in left side 23.33% and in right 19.33% unilateral impactions. The mesioangular pattern of impaction was more common in both male and female and was followed by distoangular, vertical and horizontal patterns. The study showed that there was no gender bias in the presence of impacted mandibular third molars and that the mesioangular pattern of impaction was more common.

*Corresponding Author

Name: Jones Jayabalan

Phone: +91-7845619673

Email: jonescyril27@gmail.com

ISSN: 0975-7538

DOI: <https://doi.org/10.26452/ijrps.v11i3.2788>

Production and Hosted by

IJRPS | www.ijrps.com

© 2020 | All rights reserved.

INTRODUCTION

Surgical removal of an impacted tooth is the usual procedure performed by maxillofacial surgeons everywhere (Ferrús-Torres *et al.*, 2009). The commonly impacted tooth is the third molar tooth (Ryalat *et al.*, 2018). The most frequent cause

for impaction of a mandibular third molar is due to reduced space between the distal surface of the second mandibular molar and the anterior border of the ascending ramus of the mandible. These impacted teeth present commonly as asymptomatic few times it may be associated with few pathological conditions causing pain, swelling, infection, trismus (Güven *et al.*, 2000). It sometimes causes mobility of the adjacent tooth by resorption of the neighbouring tooth root (Bataineh *et al.*, 2002). Various researches have suggested that female populations have a greater incidence of impacted mandibular third molar than the male populations. Multiple reasons are established as reasons for impaction of the third molar (Almendros-Marqués *et al.*, 2008). The evolution with a gradual decrease in the size of the mandible and maxilla is said to be one common reason for impaction of the tooth because of the reduced space in the arch. The patients who underwent surgical extraction of an impacted third

molar are shown to suffer from pain, swelling, trismus and general oral discomfort during the first few postoperative days. Few other less commonly seen complications are dry socket, wound breakdown, bleeding and neurological injury (Singh, 2019; Babu et al., 2012). In our present study, we aim to retrospectively assess the patterns of Mandibular third molar impactions reporting to our institution using Orthopantomogram.

Few classification systems have been used to classify the type of the impacted teeth namely,

1. WINTER'S classification
2. PELL AND GREGORY classification
3. KELLEY AND KAY classification
4. ARCHER'S classification of impacted maxillary teeth.

In winter's we see the position/inclination of the impacted tooth to the long axis of the second molar, and the impacted third molar is classified as disoangular impaction, mesioangular impaction, horizontal impaction, vertical impaction and transverse impaction. The classification we have used in our study is simple and easy to explain to the patient to make them understand (Çolak, 2019).

The present aim of our research is to assess the various patterns of impaction of the mandibular third molars using Orthopantomogram to identify, the position of impacted mandibular third molars and also to evaluate the most common gender affected by mandibular third molar. Impacted third molars can also be classified according to their angular relationship to the adjacent second molar. Angulation of the impacted third molar can be assessed by looking at the angle formed between the intersected longitudinal axes of the impacted third molar and the adjacent second molar, as described by winter, either visually or by using an orthodontic protractor.

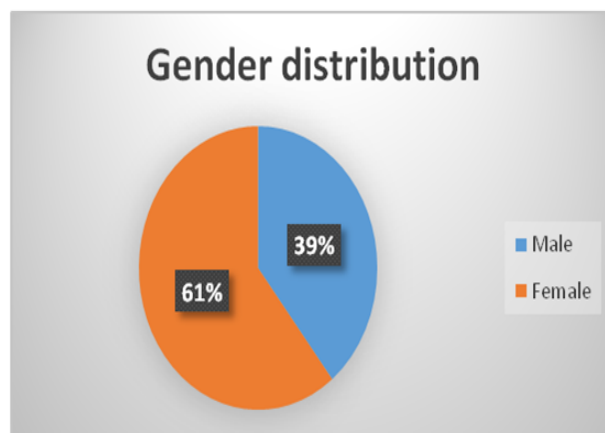
MATERIALS AND METHODS

The study is an observational study carried out retrospectively in Saveetha Dental College and Hospitals, Chennai, India. We included 150 high-quality Orthopantomograms of the patients who reported to our study.

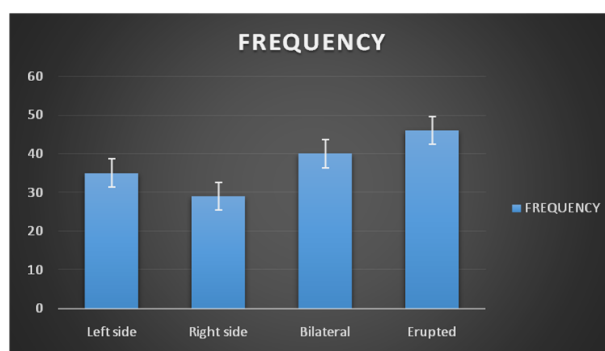
The pattern of impaction of the mandibular molar was studied using Orthopantomogram (OPG).

Inclusion criteria

1. Age of the study groups 18 – 25 years.



Graph 1: Gender distribution



Graph 2: Distribution of mandibular impaction in the sample

2. The patient reported for an impacted tooth removal.

Exclusion criteria

1. OPG of patients with congenital deformity due to any syndromes were excluded.
2. OPG of patients with any history of trauma, pathology in mandible and patient who has undergone surgery involving mandible were excluded.
3. Poor quality OPG images were excluded.

Ethical Consideration

Approval was obtained from the Institutional Review Board of Saveetha Institute of Medical and Technical Science, India.

Assessment of patterns

The pattern of impaction is derived by checking the angles recorded between the lines intersecting the long axis of the second and third molar.

Table 1: Gender distribution

Gender	N	Percentage
MALE	59	39
FEMALE	91	61
TOTAL	150	100

Table 2: Distribution of mandibular impaction in the sample

Side affected	Frequency	Percentage
LEFT SIDE ONLY	35	23.33
RIGHT SIDE ONLY	29	19.33
BOTH SIDES	40	26.66
ERUPTED	46	30.66
TOTAL	150	100

Table 3: Gender distribution Pattern of Impaction on right quadrant in female patients

Right Mandibular Third Molar	Number	Percentage
Absence	29	31.9
Mesioangular Impaction	29	31.9
Distoangular Impaction	19	20.9
Vertical Impaction	6	6.5
Horizontal Impaction	7	7.6
Total	91	100

Table 4: Gender distribution Pattern of Impaction on right quadrant in male patients

Right Mandibular third molar	Number	Percentage
Absence	17	28.81
Mesioangular Impaction	20	33.89
Distoangular Impaction	8	13.56
Vertical Impaction	5	8.47
Horizontal Impaction	9	15.25
TOTAL	59	100

Table 5: Gender distribution pattern of Impaction on left quadrant in female patients

Left Mandibular Third Molar	Number	Percentage
Absence	21	31.5
Mesioangular Impaction	35	23.3
Distoangular Impaction	12	18
Vertical impaction	10	15
Horizontal Impaction	12	18
Total	90	100

Table 6: Gender distribution pattern of Impaction on left quadrant male patients

Left Mandibular Third Molar	Number	Percentage
Absence	25	37.5
Mesioangular Impaction	22	33
Distoangular Impaction	7	10.5
Vertical Impaction	4	6
Horizontal Impaction	9	13.5
Total	67	100

The angle checked is used to determine the mesial, distal, horizontal and vertical inclination in relation to the second molar.

The radiographs were interpreted for the following:

1. Unilateral or bilateral impacted mandibular third molar.
2. The pattern of an impacted mandibular third molar.
3. Gender difference.

Statistics

The collected data were assessed with IBM SPSS statistics software Version 23.0. To explain the descriptive data statistics frequency analysis, percentage analysis was used for categorical variables, and the mean & S.D were used for continuous variables.

RESULTS AND DISCUSSION

Evaluating the 150 Orthopantomogram among the study population, 59 were of male patients (39%) and 91 were of female patients (61%), as shown in Graph 1 and Table 1. Majority of the study population reported were female patients similar to other studies showing females have a higher incidence of impactions when compared to male population (Almendros-Marqués *et al.*, 2008). A significant difference was seen in the unilateral and bilateral distribution of third molar impaction. Unilateral impaction was found in 64 radiographs which accounted for 43% of the total and bilateral impaction was seen in 40 people which accounted for 26.6% of the sample as shown graphically in Graph 2 and mentioned in Table 2.

The mesioangular pattern of impaction was more common and was followed by distoangular, vertical and horizontal patterns. Third molar impactions were more common in the right quadrant (34% per cent for the males and about 39% for the females) than in the left quadrant (23.3% in females and 33%

in males). There's no sexual predominance seen in impaction pattern or agenesis (Table 3, Table 4, Table 5 and Table 6). These findings are similar to studies done in various other populations (Harsha, 2014; Singh, 2019).

The main reason for a mandibular third molar to be impacted is due to devoid of space for the eruption. The early man ate coarse uncooked food that resulted in attrition of teeth on the occlusal and proximal surfaces of the teeth. This attrition and tendency of mesial drifting of the teeth provided the gap for an eruption of the impacted tooth. Whereas, in modern man, the attrition of teeth does not take place due to eating cooked and soft textured food. Hence, as a result, the space required for third molars eruption by attrition and mesial drifting of teeth is lost (Björk *et al.*, 1956; Akadiri *et al.*, 2010).

Other factors that bring about impactions include the growth of the face, size of the jaw, tooth size, food habits, overlying bone or soft tissue, with the host having systemic diseases etc. A properly positioned third molar erupts between the ages 18 and 24. The other complications associated with a delayed eruption of the mandibular third molar are poor tooth alignment particularly in the lower anterior, mobility of the adjacent tooth due to pathological root resorption, inflammatory conditions and even TMJ dysfunction. The dispensation of the depth of impaction and angulation in the lower third molars seen in our present study is similar to the study by Kramer and Williams. In their study, they have reported 75% of impacted lower third molars were in mesioangular and horizontal angulation. The position of an impacted tooth plays an important role in the clinical implication on the adjacent mandibular second molar, as outlined by various authors (Danda *et al.*, 2010; Stella, 2017).

CONCLUSION

Our study concludes that Orthopantomogram can be used as an excellent assessing tool to see the pattern of impaction, which helps the surgeon to carry out the surgical removal of the impacted tooth. Bilat-

eral and mesioangular impaction is commonly seen in our study population. Agenesis of the lower third molar was widely seen in the female population.

ACKNOWLEDGEMENT

The authors are grateful to the Department of Oral Medicine and Radiology, Saveetha Dental College and Hospitals for providing us with the Orthopantomogram for this research work.

Financial Support

Nil.

Conflict of Interest

There are no conflicts of interest.

REFERENCES

- Akadiri, O. A., Fasola, A. O., Arotiba, J. T. 2010. Incidence and risk factors for nerve injuries in mandibular third molar surgery. *Nigerian Journal of Medicine*, 18(4).
- Almendros-Marqués, N., Berini-Aytés, L., Gay-Escoda, C. 2008. Evaluation of Intraexaminer and Interexaminer Agreement on Classifying Lower Third Molars According to the Systems of Pell and Gregory and of Winter. *Journal of Oral and Maxillofacial Surgery*, 66(5):893–899.
- Babu, H. S. C., Reddy, P. B., Pattathan, R. K. B., Desai, R., Shubha, A. B. 2012. Factors Influencing Lingual Nerve Paraesthesia Following Third Molar Surgery: A Prospective Clinical Study. *Journal of Maxillofacial and Oral Surgery*.
- Bataineh, A. B., Al-Khateeb, T., Rawashdeh, M. A. 2002. The surgical treatment of central giant cell granuloma of the mandible. *Journal of Oral and Maxillofacial Surgery*, 60(7):756–761.
- Björk, A., Jensen, E., Palling, M. 1956. Mandibular growth and third molar impaction. *Acta Odontologica Scandinavica*, 14(3):231–272.
- Çolak, M. 2019. A radiographic evaluation of impacted third molar teeth of patients in the South-east of Turkey: a retrospective study. *International Dental Research*, 9(3):127–132.
- Danda, A. K., Tatiparthi, M. K., Narayanan, V., Siddareddi, A. 2010. Influence of Primary and Secondary Closure of Surgical Wound After Impacted Mandibular Third Molar Removal on Postoperative Pain and Swelling—A Comparative and Split Mouth Study. *Journal of Oral and Maxillofacial Surgery*, 68(2):309–312.
- Ferrús-Torres, E., Gargallo-Albiol, J., Berini-Aytés, L., Gay-Escoda, C. 2009. Diagnostic predictability of digital versus conventional panoramic radiographs in the presurgical evaluation of impacted mandibular third molars. *International Journal of Oral and Maxillofacial Surgery*, 38(11):1184–1187.
- Güven, O., Keskin, A., Akal, Ü. K. 2000. The incidence of cysts and tumors around impacted third molars. *International Journal of Oral and Maxillofacial Surgery*, 29(2):80011–80020.
- Harsha, S. S. 2014. Incidence of Mandibular Third Molar Impaction in Patients Visiting a Private Dental College. *IOSR Journal of Dental and Medical Sciences*, 13(1):1–02.
- Ryalat, S., AlRyalat, S. A., Kassob, Z., Hassona, Y., Al-Shayyab, M. H., Sawair, F. 2018. Impaction of lower third molars and their association with age: radiological perspectives. *BMC Oral Health*, 18(1).
- Singh, D. R. 2019. Correlation of Impacted Mandibular Third Molar and Inferior Alveolar Nerve Canal—A Clinico Radiographic Study. *Saudi Journal of Oral and Dental Research*, pages 819–823.
- Stella, P. E. M. 2017. Impact of mandibular third molar extraction in the second molar periodontal status: A prospective study. *Journal of Indian Society of Periodontology*, 21(4):285–290.